

Sharmeen Sorathia, MDDepartment of Internal Medicine,
Cleveland Clinic Fairview Hospital,
Cleveland, OH**Anibelky Almanzar, MD**Department of Internal Medicine, Case
Western Reserve University/MetroHealth
Hospital, Cleveland, OH**Abhishek Bhandiwad, MD**Department of Internal Medicine,
Case Western Reserve University/MetroHealth
Hospital, Cleveland, OH**Phoo Pwint Nandar, MD**Department of Internal Medicine,
Heart and Vascular Division, Case Western
Reserve University/MetroHealth Hospital,
Cleveland, OH

Managing right ventricular failure in the setting of pulmonary embolism

ABSTRACT

Pulmonary embolism (PE) has a significant impact on right-sided heart function. Clinical presentation can range from no involvement of the right ventricle to right ventricular dysfunction, cardiogenic shock, and even cardiac arrest. The authors explore the pathophysiology of PE-induced right ventricular failure, emphasizing the mechanisms by which PE contributes to dysfunction, current diagnostic tools for risk stratification, and the importance of timely diagnosis. The primary focus is on strategies for managing right ventricular failure secondary to PE, including medical, percutaneous interventional, and surgical options. Recent advances in the field are also noted, including emerging therapies and evolving treatment algorithms.

KEY POINTS

Inpatient mortality for patients with high-risk PE is as high as 42.1% and is primarily due to right ventricular dysfunction from a sudden rise in right ventricular afterload.

Risk of mortality is classified as low, intermediate (intermediate low-risk and intermediate high-risk), and high.

Management of PE with right ventricular involvement of varying severity requires prompt and concomitant integration of several approaches: management of hemodynamics (preload and afterload), reperfusion, pharmacologic support, supportive care, and, in refractory cases, use of mechanical circulatory support and advanced therapy.

PULMONARY EMBOLISM (PE) significantly impacts right-sided heart function. Clinical presentation can range from no involvement of the right ventricle to right ventricular dysfunction, cardiogenic shock, and even cardiac arrest. In a retrospective subset from the Pulmonary Embolism Response Team Consortium Registry,¹ inpatient mortality was as high as 42.1% in patients with high-risk PE with hemodynamic collapse (termed *catastrophic* PE). Management requires critical evaluation, risk stratification, and multidisciplinary care that can include medical, percutaneous interventional, and surgical options. This article predominantly discusses patients classified as having intermediate- and high-risk PE, given the associated hemodynamics and involvement of the right ventricle.

■ RIGHT VENTRICULAR FAILURE IN ACUTE PE

Acute PE is associated with an elevated risk of death, primarily due to acute right ventricular dysfunction resulting from a sudden rise in right ventricular afterload.² Vascular obstruction caused by thrombus in the pulmonary arterial circulation can lead to significant increases in pulmonary pressures and pulmonary vascular resistance, raising right ventricular afterload. In PE, hypoxemia and pulmonary vasoconstrictors also contribute to pulmonary vascular resistance. The crescent-shaped right ventricle, characterized by fine layers of myofibrils arranged in series for volume expansion and enhanced compliance compared with the left ventricle, is designed to tolerate preload

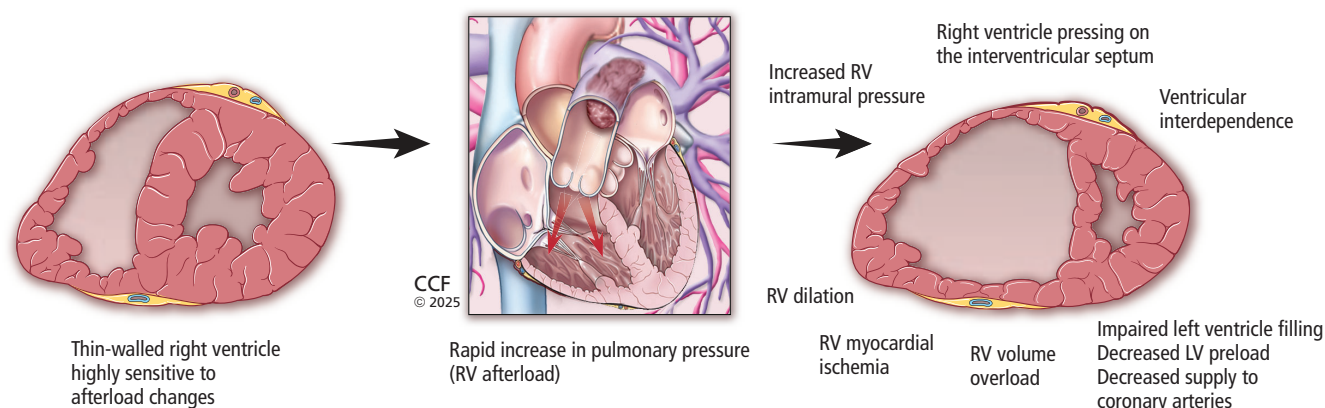


Figure 1. Illustration of the pathophysiology and development of right ventricular (RV) failure in the setting of acute increase in afterload caused by pulmonary embolism.

LV = left ventricular

Based on information from references 2 and 4.

changes and is compliant in low-pressure systems. It struggles to adapt rapidly to acute elevations in circulatory pressures and has limited capacity to adapt to sudden increases in afterload.

During an acute PE, the right ventricle attempts to preserve right ventricle–pulmonary artery coupling and maintain stroke volume and cardiac output by dilating and altering its geometry.³ However, the right ventricle cannot endure consistently elevated pressures, which leads to further right ventricular dilation and acute septal deviation toward the left ventricle, giving rise to altered ventricular interdependence—a phenomenon where the performance of one ventricle is influenced by the other due to the shared interventricular septum. Consequently, the right ventricle exerts pressure on the interventricular septum, impairing filling of the left ventricle, decreasing left ventricular preload, and reducing blood supply to the coronary arteries.

The increase in right ventricular intramural pressure and wall tension also causes straightening of the wall of the right ventricle, leading to decreased right coronary artery perfusion and right ventricular ischemia, even in individuals without preexisting coronary disease.² Furthermore, with persistent right ventricular dilation and enlargement, the tricuspid valve annulus may expand, resulting in inadequate closure of the valve leaflets and subsequent secondary tricuspid regurgitation. These effects create a cycle of ischemia, compounded by decreased oxygenation from obstructive thrombotic material, resulting in a drop in blood pressure and hemodynamic changes, all of which may manifest as syncope, hypotension, cardiogenic shock, and cardiac arrest (**Figure 1**).^{2,4} Moreover, this

dysfunction permits retrograde blood flow into the right atrium, compromising right ventricular filling, elevating right atrial pressure, and contributing to progressive venous congestion.

■ DIAGNOSTIC AND PROGNOSTIC TOOLS IN ACUTE PE

Signs of right ventricular involvement can be observed through laboratory and imaging studies. Computed tomography pulmonary angiography has been a cornerstone in the diagnosis of acute PE due to its detailed contrast enhancement of pulmonary vasculature. It is also a valuable tool in assessment of the right ventricle. Per the 2019 European Respiratory Society (ERS) guidelines, an increase in the right ventricle-to-left ventricle diameter ratio greater than 1 found with computed tomography pulmonary angiography (**Figure 2**) is indicative of acute right ventricular dysfunction, and is associated with increased risk of adverse outcomes and all-cause and PE-related mortality.^{5–7} Additional findings that may be supportive of acute right ventricular failure in certain clinical settings include septal straightening or bowing, reflux of contrast in the inferior caval vein, and hepatojugular reflux of contrast into the inferior caval vein. Thrombus load and central location have not shown a consistent association with all-cause mortality.⁶

Echocardiography is invaluable in the assessment of right ventricular dysfunction in acute PE as it can identify numerous findings suggestive of right ventricular dysfunction^{5,7}:

- Enlarged right ventricle
- Dilated right ventricle with right ventricle-to-left ventricle ratio (> 1.0)

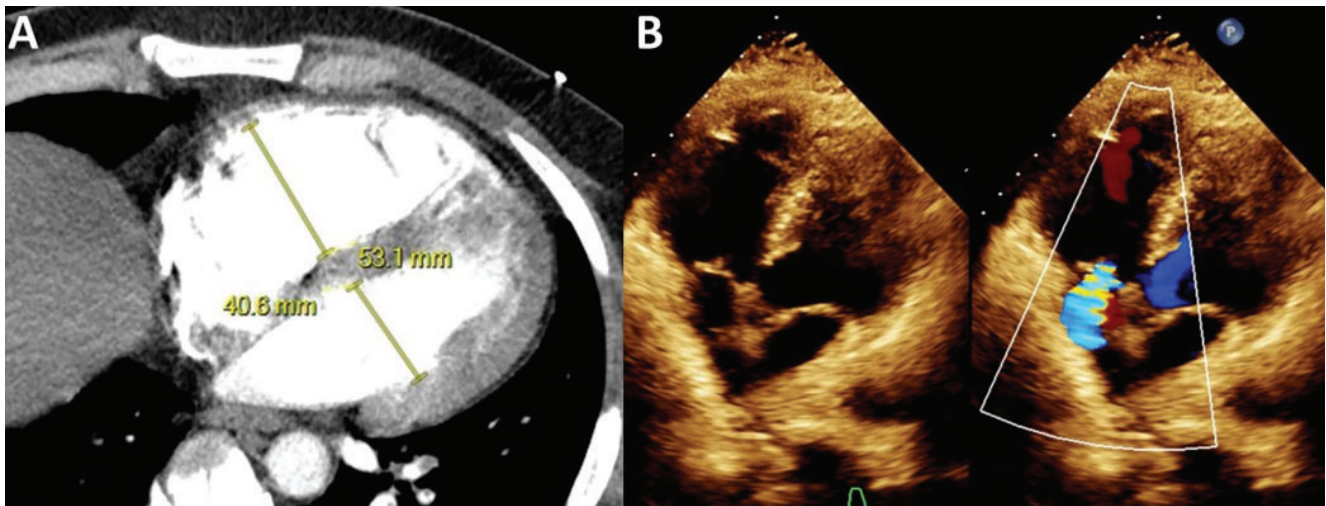


Figure 2. (A) Computed tomography and (B) echocardiogram showing an increased right ventricle-to-left ventricle ratio, which is used to assess right ventricular strain and dysfunction for risk stratification of pulmonary embolism.

- McConnell sign (right ventricular free wall akinesis with the apex spared)
- Flattened intraventricular septum
- Distended inferior caval vein with decreased inspiratory collapsibility
- Decreased tricuspid annular plane systolic excursion (< 16 mm)
- Decreased peak systolic velocity of tricuspid annulus
- Right heart mobile thrombus or clot in transit
- 60/60 sign (coexistence of acceleration time of pulmonary ejection less than 60 ms and midsystolic notch with mildly elevated [< 60 mm Hg] peak systolic gradient at the tricuspid valve).

Low left ventricular outflow tract velocity time integral of 15 cm or less and right ventricular outflow tract velocity time integral less than 9.5 cm have also been associated with adverse outcomes.^{8,9}

Biomarkers that have been proposed as tools for diagnosis and prognosis of patients with acute PE include troponins (marker of myocardial injury) and natriuretic peptides (marker of right ventricular dysfunction).⁷

■ TRIAGING AND RISK STRATIFICATION

Initial management of patients with PE begins with triaging and risk stratification using clinical assessment tools including the Pulmonary Embolism Severity Index (PESI) score or its simplified version (sPESI), cardiac biomarkers, and imaging (Figure 3).^{1,7}

Severity of PE and risk of early death are stratified as high, intermediate (intermediate low-risk and intermediate high-risk), and low. Patients classified

with high-risk PE are hemodynamically unstable, as defined by cardiac arrest, shock, or hypotension. Patients classified with intermediate-risk PE have signs of right ventricular involvement, while patients classified as low risk do not. Patients with intermediate high-risk PE are hemodynamically stable but have abnormalities in all 3 indicators of risk—clinical (PESI III–V or sPESI \geq I), laboratory (elevated troponin), and imaging parameters indicative of right ventricular dysfunction (shown on computed tomography pulmonary angiography or echocardiography). Patients classified with intermediate low-risk PE have at least clinically severe presentation and 1 or none of the other parameters.⁷ In the registry study noted earlier, the term *catastrophic* PE was introduced as a further classification of patients with high-risk PE and hemodynamic collapse, particularly those requiring vasopressors or experiencing cardiac arrest.¹

■ ESSENTIALS OF MANAGEMENT

Management of PE with right ventricular involvement of varying severity requires prompt, concomitant integration of clinical care focused on hemodynamics (preload and afterload), reperfusion, pharmacologic support, supportive care, and, in refractory cases, use of mechanical circulatory support and advanced therapy (Table 1).^{7,10}

Preload

Management of preload, particularly fluids and diuresis, has been studied sparsely. In a study of hemodynamically

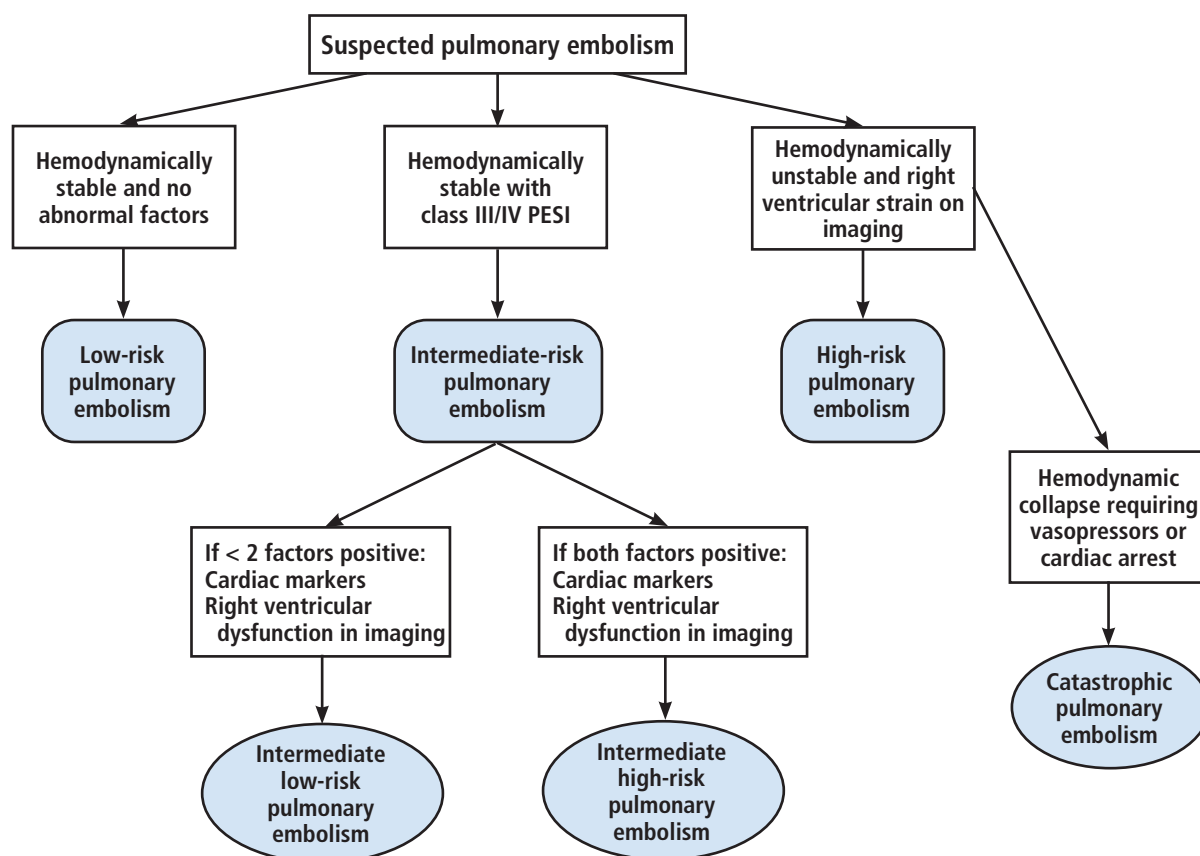


Figure 3. Algorithm of our initial assessment and risk stratification of pulmonary embolism based on Pulmonary Embolism Severity Index (PESI) score, cardiac markers (troponin or brain natriuretic peptide), right ventricular strain on imaging (transthoracic echocardiography or computed tomography pulmonary angiography), and hemodynamic instability (cardiac arrest, obstructive shock, or persistent hypotension). Note the addition of a subcategory of high-risk pulmonary embolism, termed *catastrophic* pulmonary embolism (those with hemodynamic collapse).

Based on information from references 1 and 7.

stable patients with submassive PE (defined as a normotensive patient with PE and evidence of right ventricular dysfunction), the cohort receiving intravenous furosemide bolus experienced earlier improvements in parameters of right ventricular function compared with the cohort receiving volume expansion.¹¹ More recently, in a randomized controlled trial targeting normotensive patients with intermediate-risk PE, a single high-dose bolus of furosemide improved the primary outcomes of normalization of sPESI items and reduced oligoanuria in the first 24 hours (a critical symptom of low cardiac output), and maintained stable renal function compared with placebo.¹² In another trial, right ventricular dysfunction parameters did not differ between patients with intermediate high-risk PE treated with diuresis compared with volume loading;

however, diuretics were tolerated safely, and brain-type natriuretic peptide was normalized earlier in the diuretic group.¹³

Although supporting evidence is limited, reducing the preload of an overloaded right ventricle during acute PE with diuresis would be expected to decrease right ventricular load and stress, and fluids could be detrimental. However, if a patient with acute PE has low central venous pressure (by ultrasonography of the inferior caval vein), a modest fluid challenge (≤ 500 mL) may improve the cardiac index.⁷ When volume overload is evident, diuresis with concomitant support from vasopressors can be pursued despite hypotension, to target improvement in cardiac output while reducing right ventricular dilation.

TABLE 1

Principles of management options of right ventricular failure in pulmonary embolism

Management of the thrombus	Management of the preload	Pharmacologic support	Mechanical support
High-risk pulmonary embolism: intravenous thrombolytics vs surgical embolectomy	Volume assessment	First line: norepinephrine	Venoarterial extracorporeal membrane oxygenation
Intermediate-risk pulmonary embolism: catheter-guided therapies (thrombolysis or thrombectomy) vs anticoagulation alone	Fluid challenge vs intravenous furosemide	Second line: dobutamine	Right ventricular assist device
Inferior caval vein filter placement as an adjunct to above, especially if contraindications to anticoagulation			

Based on information from references 7 and 10.

Afterload and reperfusion therapy

Because the thrombus drives the acute increase in right ventricular afterload that is the primary cause of right ventricular dysfunction, it is essential to plan reperfusion early in the course of care.

High-risk PE. Primary reperfusion with systemic thrombolysis remains the treatment of choice for patients with high-risk (or massive) PE (defined as syncope, systemic arterial hypotension, cardiogenic shock, or resuscitated cardiac arrest), and, together with anticoagulation initially with unfractionated heparin, readily improves pulmonary vascular resistance, pulmonary artery pressure, and obstruction.^{7,14} Absolute contraindications to intravenous thrombolysis include the following⁷:

- A history of hemorrhagic stroke or stroke of unknown origin
- Ischemic stroke in the previous 6 months
- Central nervous system neoplasm
- Major trauma, surgery, or head injury in previous 3 weeks
- Bleeding diathesis
- Active bleeding.

For systemic thrombolysis, lower doses of recombinant tissue-type plasminogen activator (50 mg over 2 hours compared with 100 mg over 2 hours) showed similar efficacy and possibly better safety in patients with acute PE.¹⁵

The ERS guidelines define the classes of PE treatment recommendations, with surgical embolectomy being recommended (class I indication: evidence or agreement of the benefit of treatment) for patients with

high-risk PE who have contraindications to systemic thrombolysis or in whom thrombolysis has failed.⁷ Bayiz et al¹⁶ demonstrated the safety and efficacy of percutaneous mechanical aspiration thrombectomy in patients with massive or high-risk PE, who, at follow-up, had decreased pulmonary clot burden and improved hemodynamic parameters, pulmonary artery pressure, right ventricular end-diastolic pressure, and right ventricle-to-left ventricle ratio. Currently, percutaneous catheter-directed treatment is a class IIa indication (weight of evidence favors usefulness of treatment) and should be considered for patients with massive or high-risk PE when thrombolysis is contraindicated or has failed.⁷

Low- and intermediate-risk PE. Anticoagulation is recommended (class I indication) for patients with low- to intermediate-risk PE. When oral anticoagulation is initiated, direct oral anticoagulants are preferred over vitamin K antagonists,⁷ as these agents have a lower risk of bleeding complications and similar efficacy.¹⁷

Intermediate-risk (or submassive) PE has been a focus of research in recent years, given the risk for decompensation and subsequent right ventricular strain and dysfunction. Patients with intermediate-risk PE vary in clinical presentation,¹ making management of the clot a crucial part of clinical decision-making. Thrombolysis can prevent hemodynamic decompensation and death in patients with intermediate-risk PE, but it also carries an increased risk of major hemorrhage and stroke.¹⁸ In the PEITHO (Pulmonary Embolism Thrombolysis) trial,¹⁹ thrombolysis in patients with intermediate-risk PE did not affect long-term mortality

and did not reduce right ventricular dysfunction or clinical symptoms, compared with anticoagulation alone. In patients with contraindications or in whom thrombolysis has failed, surgical embolectomy was reported to have a high survival rate.²⁰

Another modality for thrombus management is placement of an inferior caval vein filter to prevent a clot from reaching the right side of the heart and pulmonary circulation. Routine use of inferior caval vein filters is not recommended, but they should be considered in patients with absolute contraindications to anticoagulation or recurrent PE despite therapeutic anticoagulation.⁷

In conclusion, strategies for reperfusion treatment of intermediate-risk PE remain a gray area. The ERS guidelines⁷ determined that anticoagulation is the only class I recommendation for initial treatment of patients with intermediate or high clinical probability of PE. However, promising studies with a focus on emerging techniques are currently taking place.

Percutaneous interventions for clot management

Catheter-directed therapies have emerged over recent years as safe and effective options.

Catheter-directed thrombolysis. In the ULTIMA (Ultrasound Accelerated Thrombolysis of Pulmonary Embolism) trial,²¹ ultrasonography-assisted catheter-directed thrombolysis in patients with intermediate-risk PE, in addition to anticoagulation, resulted in reversal of right ventricular dilation and decreased mean right ventricle-to-left ventricle ratio at 24 hours compared with anticoagulation alone, without an increase in bleeding complications.

SEATTLE-II (A Prospective, Single-Arm, Multicenter Trial of EkoSonic Endovascular System and Activase for Treatment of Acute Pulmonary Embolism)²² studied 150 patients with right ventricular dysfunction (79% had submassive PE and 21% had massive PE) who underwent catheter-directed low-dose fibrinolysis. This therapy resulted in a significant decrease in mean right ventricle-to-left ventricle ratio 48 hours after the procedure ($P < .0001$) and reduced mean pulmonary artery systolic pressure, with a safe bleeding profile and no intracranial hemorrhage at 72 hours.²² In the OPTALYSE-PE (Optimum Duration of Acoustic Pulse Thrombolysis Procedure in Acute Pulmonary Embolism) trial,²³ catheter-directed therapy with low-dose tissue plasminogen activator administered using a shorter duration of delivery improved clot burden and right ventricular function.

More recent studies have explored outcomes of catheter-directed therapies in patients with interme-

diate high-risk PE. The CANARY (Catheter-Directed Thrombolysis vs Anticoagulation in Patients With Acute Intermediate-High-Risk Pulmonary Embolism) randomized clinical trial²⁴ showed significantly lower right ventricle-to-left ventricle ratio at the 3-month echocardiography follow-up after catheter-directed thrombolysis ($P = .01$) compared with anticoagulation monotherapy, although the study was prematurely terminated due to the COVID-19 pandemic. There is an ongoing study comparing catheter-directed thrombolysis vs anticoagulation alone in patients with intermediate high-risk PE.²⁵

Catheter-directed percutaneous mechanical thrombectomy is an emerging effective treatment option in patients with high- and intermediate-risk PE, without thrombolytic complications and their associated bleeding adverse events. FLARE (FlowTrier Pulmonary Embolectomy Clinical Study)²⁶ showed significant improvement in the right ventricle-to-left ventricle ratio 48 hours after the procedure, with minimal major bleeding, in patients with intermediate-risk PE. The recent FLAME (FlowTrier for Acute Massive PE) study²⁷ compared peripheral mechanical thrombectomy with other contemporary therapies (systemic thrombolysis or anticoagulation alone) in patients with high-risk PE and found a lower rate of in-hospital adverse outcomes and 1.9% all-cause mortality in the thrombectomy group. These studies are an important step forward in management options other than systemic thrombolysis for hemodynamically unstable patients with high-risk PE.

Furthermore, a study using data from the largest US National Inpatient Sample database noted that catheter-based therapy (thrombolysis or mechanical thrombectomy) for patients with cancer and intermediate- or high-risk PE was associated with a lower risk of in-hospital mortality or cardiac arrest but had a high risk of bleeding.²⁸

In the PERFECT (Pulmonary Embolism Response to Fragmentation, Embolectomy, and Catheter Thrombolysis) multicenter registry,²⁹ 101 patients with massive (high-risk) and submassive (intermediate high-risk) PE were treated with catheter-directed therapy, including mechanical or pharmacomechanical thrombectomy or thrombolysis. Clinical success—defined as hemodynamic stability, improvement in pulmonary artery pressure and right heart strain, and survival to hospital discharge—was achieved in 85.7% of patients with massive PE and 97.3% of patients with submassive PE. These therapies were found to be safe, with improved right-sided heart function.

■ PHARMACOLOGIC SUPPORT

Inotropes and vasopressors

In patients with high-risk PE and shock, vasopressors are often needed to maintain systemic blood pressure and improve end-organ and coronary perfusion.⁷ In cases of persistently low cardiac output despite vasopressor therapy, it is advisable to consider contractility support with inotropes. Norepinephrine and dobutamine are currently recommended as class IIa options for patients with high-risk PE. However, dobutamine should be used cautiously to enhance right ventricular and cardiac output, as it may worsen ventilation-perfusion mismatch and increase the risk of arrhythmias. Additionally, using dobutamine without a vasopressor can exacerbate hypotension.

Pulmonary vasodilators

The role of pulmonary vasodilation has also been explored in right ventricular dysfunction in patients with PE. In a randomized clinical trial with 20 patients who had acute intermediate high-risk PE, a single-dose of sildenafil (in 10 patients) did not significantly improve the cardiac index and instead lowered blood pressure compared with placebo.³⁰ In another randomized clinical trial, patients with severe acute submassive (intermediate high-risk) PE who received treatment with nitric oxide did not achieve the primary composite end point of normal right ventricle on echocardiogram and normal plasma troponin T.³¹ However, a preplanned post hoc analysis showed that 29% more patients treated with nitric oxide had resolution of right ventricular dilation or hypokinesis at 24 hours.³¹ In a randomized clinical trial of 14 patients with acute PE (hemodynamically stable with high clinical probability of right ventricular dysfunction), epoprostenol compared with placebo did not result in improvement of right ventricular dilation or other parameters.³²

While pulmonary vasodilators can be beneficial in specific types of pulmonary hypertension, their effectiveness in right ventricular failure associated with pulmonary vascular issues may be limited. This is likely due to the unique pathophysiology of PE, particularly the acute increase in afterload resulting from a substantial clot burden. Overall, pulmonary vasodilators are not encouraged, as they can aggravate hypoperfusion of organs and systemic hypotension, despite efforts to decrease blood pressure and pulmonary vascular resistance.⁷

■ SUPPORTIVE CARE

For hypoxemic patients, prompt administration of supplemental oxygen therapy is essential. Intubation and

mechanical ventilation are reserved for select patients with refractory hypoxemia and unstable hemodynamics, with careful use of anesthetic agents to avoid hypotension and cautious monitoring given the detrimental effects of positive end-expiratory pressure.⁷

In recent years, an integrated approach involving multidisciplinary teams, early risk stratification, and prompt decision-making in patients with intermediate-risk PE has led to lower rates of all-cause mortality,³³ reduced intensive care unit and overall hospital length of stay,³⁴ and high survival-to-discharge rates.³⁵ A multidisciplinary team approach in patients with high-risk PE and certain patients with intermediate-risk PE is a class IIa recommendation.⁷ In the long term, if patients develop pulmonary hypertension as a complication, referral to a pulmonary hypertension center is highly recommended.

■ MECHANICAL CIRCULATORY SUPPORT AND ADVANCED THERAPY

Extracorporeal membrane oxygenation

Some patients may experience clinical deterioration that is resistant to treatment, including cardiac arrest or worsening hemodynamic shock requiring increased vasopressor support. In these cases, extracorporeal membrane oxygenation (ECMO) can be used as a bridging or rescue therapy; the ERS classified this as a class IIb recommendation (efficacy of treatment is less well established).⁷ Venoarterial ECMO can bypass blocked pulmonary circulation by providing sufficient cardiac output to sustain systemic and coronary blood flow until the thrombus is effectively managed. However, using ECMO for an extended period, typically more than 5 to 10 days, can result in complications.⁷

Another detailed analysis from the National Inpatient Sample database of patients with high-risk PE revealed that use of ECMO in patients with massive PE increased from 0.07% to 1.1% from 2005 to 2013 and its use was not associated with a change in in-hospital mortality (61.6%).³⁶ ECMO was performed in 0.3% of hospitalized patients with high-risk PE for a duration of 1.9 ± 4.1 days from the index admission date, and the median hospital length of stay was 10 days. In patients with high-risk PE using ECMO for hemodynamic support, independent predictors of mortality included age, female sex, obesity, congestive heart failure, and chronic pulmonary disease.³⁶

A handful of studies have looked at using ECMO as a bridge to ultimate clot management in patients with high-risk PE. In a cohort of 20 patients with high-risk PE who were managed with venoarterial

ECMO for a median 5.1 days, 94.7% had normal right ventricular function at discharge.³⁷ Another group of 16 patients with acute high-risk PE, 12 of whom were in cardiac arrest, underwent venoarterial ECMO for a mean duration of 1.5 days and had an overall 30-day mortality rate of 43.8%; treatment was mainly with ECMO alone, ECMO with thrombolysis, and ECMO with embolectomy.³⁸ While a meta-analysis on venoarterial ECMO and acute massive PE did not show significantly different in-hospital mortality between patients treated with or without ECMO,³⁹ another meta-analysis of venoarterial ECMO showed low-quality evidence of higher survival rates in patients 60 years or younger and in those who underwent surgical embolectomy.⁴⁰ There was evidence that venoarterial ECMO improves short-term survival of patients with acute PE.⁴⁰

The 2022 American Heart Association guidelines maintain their earlier statement on cardiopulmonary resuscitation, which suggests that extracorporeal cardiopulmonary resuscitation for cardiac arrest from PE can be considered as a bridge to reperfusion therapy in select patients when it can be implemented and conventional cardiopulmonary resuscitation is failing.⁴¹

Right ventricular assist devices

Right ventricular assist devices have been explored for refractory shock related to PE. The devices can be placed surgically, with cannulation performed in the right atrium or right ventricle and pulmonary artery while connected with an extracorporeal flow pump.⁴ They also can be placed percutaneously with lower flow than surgical right ventricular assist devices. Right ventricular assist devices, while offloading the right atrium

and right ventricle from excessive preload, ultimately increase right ventricular afterload by generating constant flow and pressure in the pulmonary artery.⁴ The percutaneous right ventricular assist device Impella RP, when used in hemodynamically unstable patients with PE, can lead to shock reversal with improvement in cardiac index and hemodynamic stability.¹⁰

Overall, there is a lack of sufficient evidence on outcomes of patients with acute high-risk PE undergoing treatment with ECMO, Impella RP, or other right ventricular assist devices. The decision to bridge with mechanical circulatory support should be made on a case-by-case basis, using a multidisciplinary team approach that involves intensivists, cardiologists with expertise in heart failure, pulmonologists, and cardiothoracic surgeons.

CONCLUSION

The incidence and burden of PE have risen in recent decades. Mortality, particularly in patients at high-risk with significant right ventricular involvement, is alarmingly high. An integrated approach to risk stratification and prompt implementation of therapies are critical to manage acute, life-threatening and long-term sequelae of PE, given PE's relationship with right-sided heart dysfunction. There are evidence gaps in the management of right ventricular failure due to PE, and further studies are warranted to aid in decision-making.

DISCLOSURES

The authors report no relevant financial relationships which, in the context of their contributions, could be perceived as a potential conflict of interest.

REFERENCES

1. Kobayashi T, Pugliese S, Sethi SS, et al. Contemporary management and outcomes of patients with high-risk pulmonary embolism. *J Am Coll Cardiol* 2024; 83(1):35–43. doi:10.1016/j.jacc.2023.10.026
2. Matthews JC, McLaughlin V. Acute right ventricular failure in the setting of acute pulmonary embolism or chronic pulmonary hypertension: a detailed review of the pathophysiology, diagnosis, and management. *Curr Cardiol Rev* 2008; 4(1):49–59. doi:10.2174/157340308783565384
3. He Q, Lin Y, Zhu Y, et al. Clinical usefulness of right ventricle-pulmonary artery coupling in cardiovascular disease. *J Clin Med* 2023; 12(7):2526. doi:10.3390/jcm12072526
4. Bali AD, Sharma T, Villela MA, Naidu SS, Goldberg J. Interventional therapies and mechanical circulatory support for acute pulmonary embolism. *J Card Fail* 2024; 30(10):1319–1329. doi:10.1016/j.cardfail.2024.07.012
5. Pruszczyk P, Goliszek S, Lichodziejewska B, et al. Prognostic value of echocardiography in normotensive patients with acute pulmonary embolism. *JACC Cardiovasc Imaging* 2014; 7(6):553–560. doi:10.1016/j.jcmg.2013.11.004
6. Meinel FG, Nance JW Jr, Schoepf UJ, et al. Predictive value of computed tomography in acute pulmonary embolism: systematic review and meta-analysis. *Am J Med* 2015; 128(7):747–759.e2. doi:10.1016/j.amjmed.2015.01.023
7. Konstantinides SV, Meyer G, Becattini C, et al. 2019 ESC guidelines for the diagnosis and management of acute pulmonary embolism developed in collaboration with the European Respiratory Society (ERS). *Eur Heart J* 2020; 41(4):543–603. doi:10.1093/eurheartj/ehz405
8. Yuriditsky E, Mitchell OJ, Sibley RA, et al. Low left ventricular outflow tract velocity time integral is associated with poor outcomes in acute pulmonary embolism. *Vasc Med* 2020; 25(2):133–140. doi:10.1177/1358863X19880268
9. Brailovsky Y, Lakhter V, Weinberg I, et al. Right ventricular outflow doppler predicts low cardiac index in intermediate risk pulmonary embolism. *Clin Appl Thromb Hemost* 2019; 25:1076029619886062. doi:10.1177/1076029619886062
10. Elder M, Blank N, Kaki A, et al. Mechanical circulatory support for acute right ventricular failure in the setting of pulmonary embolism. *J Interv Cardiol* 2018; 31(4):518–524. doi:10.1111/joic.12503
11. Schouwer ED, Chiche O, Bouvier P, et al. Diuretics versus volume expansion in acute submassive pulmonary embolism. *Arch Cardiovasc Dis* 2017; 110(11):616–625. doi:10.1016/j.acvd.2017.01.016

12. Lim P, Delmas C, Sanchez O, et al. Diuretic vs. placebo in intermediate-risk acute pulmonary embolism: a randomized clinical trial. *Eur Heart J Acute Cardiovasc Care* 2022; 11(1):2–9. doi:10.1093/ehjacc/zuab082
13. Ferrari E, Sartre B, Labbaoui M, et al. Diuretics versus volume expansion in the initial management of acute intermediate high-risk pulmonary embolism. *Lung* 2022; 200(2):179–185. doi:10.1007/s00408-022-00530-5
14. Marti C, John G, Konstantinides S, et al. Systemic thrombolytic therapy for acute pulmonary embolism: a systematic review and meta-analysis. *Eur Heart J* 2015; 36(10):605–614. doi:10.1093/eurheartj/ehu218
15. Wang C, Zhai Z, Yang Y, et al. Efficacy and safety of low dose recombinant tissue-type plasminogen activator for the treatment of acute pulmonary thromboembolism: a randomized, multicenter, controlled trial. *Chest* 2010; 137(2):254–262. doi:10.1378/chest.09-0765
16. Bayiz H, Dumantepe M, Teymen B, Uyar I. Percutaneous aspiration thrombectomy in treatment of massive pulmonary embolism. *Heart Lung Circ* 2015; 24(1):46–54. doi:10.1016/j.hlc.2014.06.014
17. van der Hulle T, Kooiman J, den Exter PL, Dekkers OM, Klok FA, Huisman MV. Effectiveness and safety of novel oral anticoagulants as compared with vitamin K antagonists in the treatment of acute symptomatic venous thromboembolism: a systematic review and meta-analysis. *J Thromb Haemost* 2014; 12(3):320–328. doi:10.1111/jth.12485
18. Meyer G, Vicaut E, Danays T, et al. Fibrinolysis for patients with intermediate-risk pulmonary embolism. *N Engl J Med* 2014; 370(15):1402–1411. doi:10.1056/NEJMoa1302097
19. Konstantinides SV, Vicaut E, Danays T, et al. Impact of thrombolytic therapy on the long-term outcome of intermediate-risk pulmonary embolism. *J Am Coll Cardiol* 2017; 69(12):1536–1544. doi:10.1016/j.jacc.2016.12.039
20. Kolkailah AA, Hirji S, Piazza G, et al. Surgical pulmonary embolectomy and catheter-directed thrombolysis for treatment of submassive pulmonary embolism. *J Card Surg* 2018; 33(5):252–259. doi:10.1111/jocs.13576
21. Kucher N, Boekstegers P, Müller OJ, et al. Randomized, controlled trial of ultrasound-assisted catheter-directed thrombolysis for acute intermediate-risk pulmonary embolism. *Circulation* 2014; 129(4):479–486. doi:10.1161/CIRCULATIONAHA.113.005544
22. Piazza G, Hohlfelder B, Jaff MR, et al. A prospective, single-arm, multicenter trial of ultrasound-facilitated, catheter-directed, low-dose fibrinolysis for acute massive and submassive pulmonary embolism: the SEATTLE II study. *JACC Cardiovasc Interv* 2015; 8(10):1382–1392. doi:10.1016/j.jcin.2015.04.020
23. Tapson VF, Sterling K, Jones N, et al. A randomized trial of the Optimum Duration of Acoustic Pulse Thrombolysis Procedure in Acute Intermediate-Risk Pulmonary Embolism: the OPTALYSE PE trial. *JACC Cardiovasc Interv* 2018; 11(14):1401–1410. doi:10.1016/j.jcin.2018.04.008
24. Sadeghipour P, Jenab Y, Moosavi J, et al. Catheter-directed thrombolysis vs anticoagulation in patients with acute intermediate-high-risk pulmonary embolism: the CANARY randomized clinical trial. *JAMA Cardiol* 2022; 7(12):1189–1197. doi:10.1001/jamacardio.2022.3591
25. Klok FA, Piazza G, Sharp ASP, et al. Ultrasound-facilitated, catheter-directed thrombolysis vs anticoagulation alone for acute intermediate-high-risk pulmonary embolism: rationale and design of the HI-PEITHO study. *Am Heart J* 2022; 251:43–53. doi:10.1016/j.ahj.2022.05.011
26. Tu T, Toma C, Tapson VF, et al. A prospective, single-arm, multicenter trial of catheter-directed mechanical thrombectomy for intermediate-risk acute pulmonary embolism: the FLARE study. *JACC Cardiovasc Interv* 2019; 12(9):859–869. doi:10.1016/j.jcin.2018.12.022
27. Silver MJ, Gibson CM, Giri J, et al. Outcomes in high-risk pulmonary embolism patients undergoing FlowTrier mechanical thrombectomy or other contemporary therapies: results from the FLAME study. *Circ Cardiovasc Interv* 2023; 16(10):e013406. doi:10.1161/CIRCINTERVENTIONS.123.013406
28. Leiva O, Yuriditsky E, Postelnicu R, et al. Catheter-based therapy for intermediate or high-risk pulmonary embolism is associated with lower in-hospital mortality in patients with cancer: insights from the national inpatient sample. *Catheter Cardiovasc Interv* 2024; 103(2):348–358. doi:10.1002/ccd.30917
29. Kuo WT, Banerjee A, Kim PS, et al. Pulmonary Embolism Response to Fragmentation, Embolectomy, and Catheter Thrombolysis (PERFECT): initial results from a prospective multicenter registry. *Chest* 2015; 148(3):667–673. doi:10.1378/chest.15-0119
30. Andersen A, Waziri F, Schultz JG, et al. Pulmonary vasodilation by sildenafil in acute intermediate-high risk pulmonary embolism: a randomized explorative trial. *BMC Pulm Med* 2021; 21(1):72. doi:10.1186/s12890-021-01440-7
31. Kline JA, Puskarich MA, Jones AE, et al. Inhaled nitric oxide to treat intermediate risk pulmonary embolism: a multicenter randomized controlled trial. *Nitric Oxide* 2019; 84:60–68. doi:10.1016/j.niox.2019.01.006
32. Kooter AJ, Ijzerman RG, Kamp O, Boonstra AB, Smulders YM. No effect of epoprostenol on right ventricular diameter in patients with acute pulmonary embolism: a randomized controlled trial. *BMC Pulm Med* 2010; 10:18. doi:10.1186/1471-2466-10-18
33. Sagoschen I, Scibior B, Farmakis IT, et al. A multidisciplinary pulmonary embolism response team (PERT): first experience from a single center in Germany. *Clin Res Cardiol* 2024; 113(4):581–590. doi:10.1007/s00392-023-02364-4
34. Xenos ES, Davis GA, He Q, Green A, Smyth SS. The implementation of a pulmonary embolism response team in the management of intermediate- or high-risk pulmonary embolism. *J Vasc Surg Venous Lymphat Disord* 2019; 7(4):493–500. doi:10.1016/j.jvsv.2018.11.014
35. Carroll BJ, Pemberton H, Bauer KA, et al. Initiation of a multidisciplinary, rapid response team to massive and submassive pulmonary embolism. *Am J Cardiol* 2017; 120(8):1393–1398. doi:10.1016/j.amjcard.2017.07.033
36. Elbadawi A, Mentias A, Elgendy IY, et al. National trends and outcomes for extra-corporeal membrane oxygenation use in high-risk pulmonary embolism. *Vasc Med* 2019; 24(3):230–233. doi:10.1177/1358863X18824650
37. Pasrija C, Kronfli A, George P, et al. Utilization of veno-arterial extracorporeal membrane oxygenation for massive pulmonary embolism. *Ann Thorac Surg* 2018; 105(2):498–504. doi:10.1016/j.athoracsur.2017.08.033
38. Oh YN, Oh DK, Koh Y, et al. Use of extracorporeal membrane oxygenation in patients with acute high-risk pulmonary embolism: a case series with literature review. *Acute Crit Care* 2019; 34(2):148–154. doi:10.4266/acc.2019.00500
39. Kaso ER, Pan JA, Salerno M, et al. Venoarterial extracorporeal membrane oxygenation for acute massive pulmonary embolism: a meta-analysis and call to action. *J Cardiovasc Transl Res* 2022; 15(2):258–267. doi:10.1007/s12265-021-10158-0
40. Karami M, Mandigers L, Miranda DDR, et al. Survival of patients with acute pulmonary embolism treated with venoarterial extracorporeal membrane oxygenation: a systematic review and meta-analysis. *J Crit Care* 2021; 64:245–254. doi:10.1016/j.jcrc.2021.03.006
41. Wyckoff MH, Greif R, Morley PT, et al. 2022 international consensus on cardiopulmonary resuscitation and emergency cardiovascular care science with treatment recommendations: summary from the Basic Life Support; Advanced Life Support; Pediatric Life Support; Neonatal Life Support; Education, Implementation, and Teams; and First Aid Task Forces [published correction appears in *Circulation* 2024; 149(21):e1218]. *Circulation* 2022; 146(25):e483–e557. doi:10.1161/CIR.0000000000001095

Address: Phoo Pwint Nandar, MD, Department of Internal Medicine, Heart and Vascular Division, Case Western Reserve University/MetroHealth Hospital, 2500 MetroHealth Drive, Cleveland, OH 44109; pnandar@metrohealth.org