

Akihiro Orita, MD

Department of Dermatology, Chitose City
Hospital, Chitose, Japan

Mitsuhito Ota, MD, PhD

Department of Dermatology, Chitose City
Hospital, Chitose, Japan

Sarcoidosis with diffuse purplish erythematous plaques on the hands

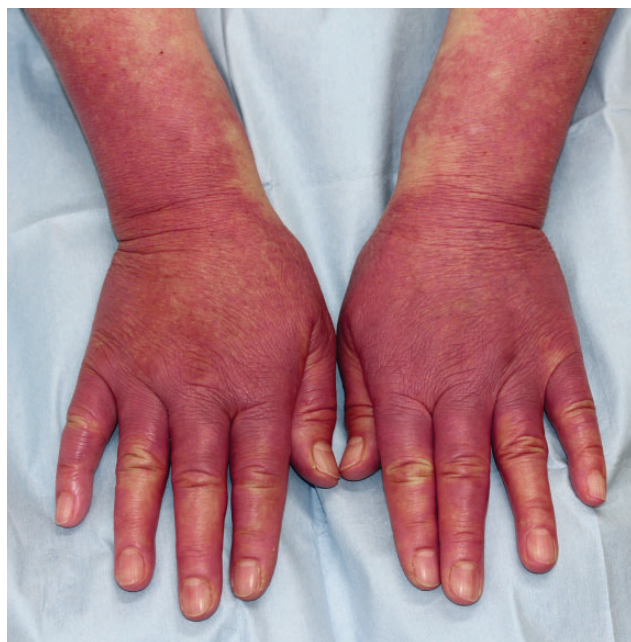

Figure 1. Diffuse purplish erythema on the dorsal surface of the distal forearms, hands, and fingers, with telangiectasia and swollen fingers.

A PREVIOUSLY HEALTHY 70-YEAR-OLD WOMAN presented in winter with a 1-month history of asymptomatic redness of the hands. She denied that the rash had been exacerbated by exposure to the cold temperatures. Physical examination revealed diffuse purplish erythematous plaques symmetrically distributed on the distal forearms and on the dorsal surface of the hands and fingers, with telangiectasia and swollen fingers (**Figure 1**). She had no other skin lesions.

Histopathologic examination of a skin biopsy specimen showed noncaseating granulomatous infil-

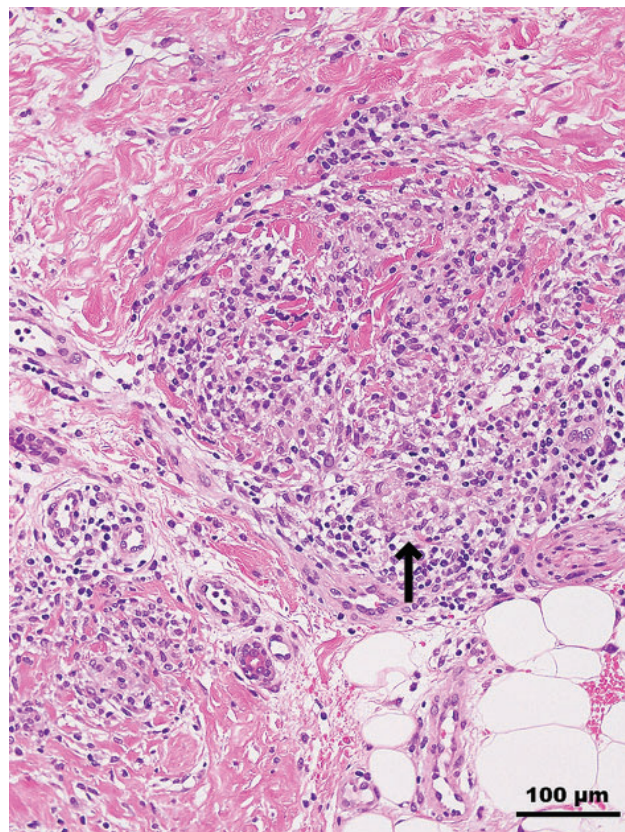


Figure 2. Histopathologic examination of a skin biopsy specimen revealed nodular histiocytic infiltration in the dermis, forming epithelioid granulomas (arrow) without evidence of necrosis (hematoxylin and eosin, original $\times 200$).

trates of epithelioid histiocytes with mild lymphocytic infiltrates in the dermis (**Figure 2**). Radiography of the hands found no bone lesions. Laboratory testing showed a serum angiotensin-converting enzyme level of 30.4 U/L (reference range 7.0–25.0 U/L). Systemic

doi:10.3949/ccjm.92a.24022

investigations identified supraclavicular and mediastinal lymphadenopathies and uveitis.

A diagnosis of sarcoidosis was made, and treatment with oral prednisolone (0.5 mg/kg daily) was started. The skin lesions abated in 2 months, and the prednisolone was tapered off. The nodal lesions also have disappeared or regressed, and the uveitis has improved.

CUTANEOUS MANIFESTATIONS OF SARCOIDOSIS

Sarcoidosis is a systemic disorder of unknown etiology characterized by noncaseating epithelioid cell granulomas that mainly involve the lungs (about 90% of cases), mediastinal and peripheral lymph nodes, eyes, and skin.¹ Involvement of the liver, spleen, central nervous system, heart, and bones occurs less often but is usually severe.

Cutaneous lesions specific for sarcoidosis, ie, those that display the histopathologic features of sarcoid granulomas, develop in up to 35% of patients with systemic sarcoidosis.² Less than one-third of patients with cutaneous manifestations have isolated cutaneous sarcoidosis without any systemic features.¹ The most common specific skin lesions include maculopapular sarcoidosis, nodular and plaque sarcoidosis, lupus pernio, scar or tattoo sarcoidosis, and subcutaneous sarcoidosis.²

Nonspecific skin lesions—those not caused by granulomas—also can occur in sarcoidosis and include erythema nodosum, prurigo, digital clubbing, erythema multiforme, pyoderma gangrenosum, and Sweet syndrome. Of these, erythema nodosum is the most common. However, there are many less common cutaneous manifestations of sarcoidosis, and, because

of this varied morphology, sarcoidosis is considered one of the great imitators in dermatology.²

In this patient, the cutaneous lesion may have been lupus pernio, which causes indurated violaceous papulonodules and plaques on the nose, cheeks, and ears.³ The fingers and toes can be affected as well. To the best of our knowledge, lupus pernio occurring only on the hands has not been reported. Differential diagnoses in this patient included vascular disorders, such as chilblains, Raynaud phenomenon, and acrocyanosis.

Delays in the diagnosis of sarcoidosis are common given its varying presentations. Sarcoidosis is diagnosed more easily and earlier when skin lesions are present because the skin is easily accessible for histopathologic confirmation.⁴ However, this does not necessarily mean that it is easy to recognize a skin lesion as a manifestation of sarcoidosis. Because cutaneous sarcoidosis presents with varied morphology, it may present a diagnostic challenge.

A thorough skin examination and skin biopsy are necessary for diagnosing sarcoidosis. Laboratory tests can also be useful because at least 60% of patients diagnosed with sarcoidosis have an increased serum angiotensin-converting enzyme level.² A systemic workup to evaluate the extent of involvement should be undertaken in all patients with cutaneous sarcoid lesions, even in those with minimal skin involvement.

DISCLOSURES

The authors report no relevant financial relationships which, in the context of their contributions, could be perceived as a potential conflict of interest.

REFERENCES

1. Islam S, Hossain MS, Murshed KM, Rahaman MFU, Azad MAK. Cutaneous sarcoidosis: a differential diagnosis to consider in undiagnosed skin lesions. *Cureus* 2023; 15(6):e39852. doi:10.7759/cureus.39852
2. Marcoval J, Mana J. Sarcoidosis. In: Griffiths C, Barker J, Bleiker T, Chalmers R, Creamer D, eds. *Rook's Textbook of Dermatology*. 9th ed. United Kingdom: Wiley-Blackwell; 2016.
3. Popatia S, Wanat KA. Lupus pernio. *JAMA Dermatol* 2022; 158(4):446. doi:10.1001/jamadermatol.2021.6007
4. Judson MA, Thompson BW, Rabin DL, et al. The diagnostic pathway to sarcoidosis. *Chest* 2003; 123(2):406–412. doi:10.1378/chest.123.2.406

Address: Mitsuhiro Ota, MD, PhD, Department of Dermatology, Chitose City Hospital, Hokkaido 2, Chitose 066-8550 Japan; ota@med.hokudai.ac.jp