

**David D. Chong, BA**

Case Western Reserve University School of Medicine, Cleveland, OH

**Nikhil Das, MD**

Center for Ophthalmic Bioinformatics, Cole Eye Institute, Cleveland Clinic, Cleveland, OH

**Rishi P. Singh, MD**

Vice President, Chief Medical Officer, Cleveland Clinic Martin Hospitals, Cleveland Clinic Florida, Stuart, FL; Professor, Cleveland Clinic Lerner College of Medicine of Case Western Reserve University, Cleveland, OH

# Diabetic retinopathy: Screening, prevention, and treatment

## ABSTRACT

Internists are integral in the multidisciplinary approach to diabetic retinopathy, contributing significantly to the management of diabetes and diabetes-related complications. Effective screening processes, timely referrals, and strategic diabetes management are imperative to prevent and mitigate the consequences of diabetic retinopathy. The evolution of treatments for diabetic retinopathy has markedly improved vision outcomes and reduced the burden on patients. Despite these advances, a collaborative approach to care is essential to prevent the progression of vision impairment and manage associated complications.

## KEY POINTS

Primary care physicians should implement the American Diabetes Association screening guidelines and consider leveraging new technologies to ensure patients who require ophthalmologic care are effectively referred to an ophthalmologist.

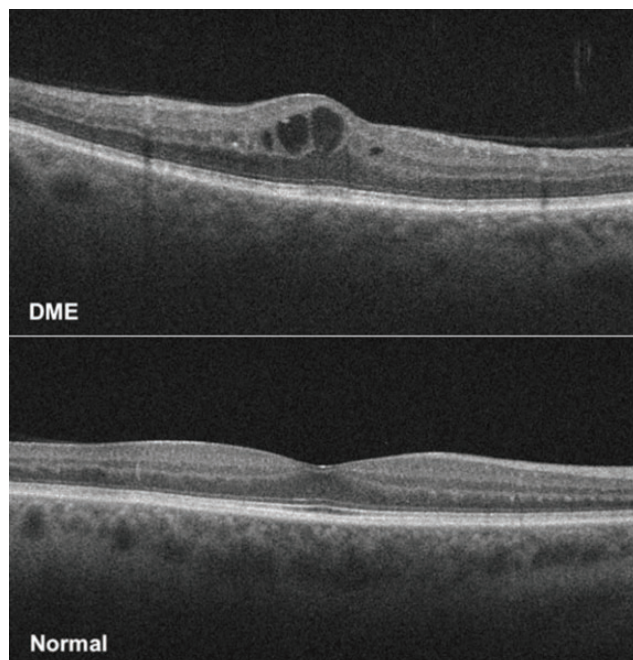
Glycemic control is crucial for preventing progression of diabetic retinopathy and can be more easily achieved using new diabetes therapies.

Diabetic retinopathy and diabetic macular edema are primarily treated with anti-vascular endothelial growth factors that are administered based on diabetic retinopathy staging and the presence of center-involved diabetic macular edema, as determined by optical coherence tomography.

**D**IABETIC RETINOPATHY is the leading cause of new cases of blindness in patients with diabetes mellitus.<sup>1-4</sup> In 2020, more than 103 million individuals with diabetes mellitus worldwide were affected by diabetic retinopathy, and estimates suggest this number will increase to 160 million by 2045.<sup>5</sup> Compared with all other leading causes of blindness, diabetic retinopathy is the only condition that has not experienced a decrease in age-standardized prevalence between 1990 and 2020.<sup>6</sup> Without proper prevention and management, the burden of diabetic retinopathy will continue to grow, placing more patients at risk for complications that can cause severe vision loss, such as diabetic macular edema (DME) and proliferative diabetic retinopathy. This article reviews the principles of screening for diabetic retinopathy, measures for preventing its development and progression, and current treatment options.

## ■ DIABETIC RETINOPATHY CLASSIFICATIONS

Diabetic retinopathy is classified as nonproliferative diabetic retinopathy (NPDR) and proliferative diabetic retinopathy based on the absence or presence of abnormal new blood vessels growing in the retina. The nonproliferative and proliferative stages are sequential. NPDR is further classified by severity as mild, moderate, or severe, and proliferative diabetic retinopathy as early or high-risk.<sup>7</sup> DME, defined as thickening of the retina, can occur in any stage of diabetic retinopathy and is the most common complication of diabetic retinopathy that causes vision loss (**Figure 1**).<sup>7,8</sup> DME can be divided into center-involved DME, which is



**Figure 1.** Optical coherence tomography images demonstrating center-involved diabetic macular edema (DME) and a normal retina with no edema.

thickening in the center of the macula and has greater risk for vision loss, or noncenter-involved DME.<sup>8</sup>

## SCREENING

Patients with type 1 and type 2 diabetes, including children, are at increased risk for diabetic retinopathy. These patients should be screened regularly with a comprehensive eye examination because symptoms may not occur until the disease has advanced and sight is threatened.<sup>2,9,10</sup> Although there are effective treatments to prevent progression to sight-threatening diabetic retinopathy, management is not possible until diabetic retinopathy has been detected. Unfortunately, screening rates remain low, with less than 50% of patients with diabetes mellitus receiving appropriate ophthalmic care through referrals from primary care physicians.<sup>3,11</sup>

### Who to screen, and how often

The American Diabetes Association recommends referring patients with type 1 diabetes to an ophthalmologist or optometrist for an initial dilated and comprehensive eye examination within 5 years of onset; patients with type 2 diabetes should be referred at the time of diagnosis.<sup>2,8</sup> If any level of diabetic retinopathy is present

on eye examination, the patient should receive dilated retinal examinations by an ophthalmologist or optometrist at least annually.<sup>2,8</sup> If symptoms progress or sight is threatened, more frequent examinations are required. Conversely, if 1 or more annual eye examinations show no evidence of diabetic retinopathy and glycemic indicators are within goal range, eye examinations can take place every 1 to 2 years.<sup>2</sup>

Patients who have lowered their hemoglobin A1c (HbA1c) to less than 6.5% for at least 3 months while off glucose-lowering medications would be considered in remission for diabetes mellitus.<sup>12</sup> With these patients, extending the screening intervals is acceptable, but it is important to adjust intervals based on the presence of other risk factors such as progression of diabetic retinopathy, advanced baseline retinopathy, uncontrolled hyperglycemia, or diabetic macular edema.<sup>2</sup>

Pregnancy increases the risk for the development and progression of diabetic retinopathy. Patients with preexisting type 1 diabetes or type 2 diabetes who are planning pregnancy should undergo an eye examination before pregnancy, early in the first trimester and in the following trimesters, and up to 1 year post partum, depending on the degree of diabetic retinopathy (Table 1).<sup>2,11–13</sup> According to the American Academy of Ophthalmology and the American Diabetes Association, patients who develop gestational diabetes mellitus do not require eye examinations.<sup>2,8</sup>

### Retinal photography with remote interpretation

Retinal photography in the primary care setting with remote reading by an ophthalmologist, optometrist, or artificial intelligence algorithms approved by the US Food and Drug Administration can be used in patients without a history of diabetic retinopathy.<sup>2,14–16</sup> This approach can increase access to diabetic retinopathy screening. However, retinal images must be of sufficient quality, and retinal photographs cannot substitute for follow-up eye examinations once abnormalities are detected.<sup>2</sup>

Artificial intelligence algorithms have specific exclusion criteria and provide limited results. The algorithms have not been used to screen patients with diabetes mellitus who are pregnant or who have blurred vision or floaters. Also, artificial intelligence algorithms are limited to detecting whether the eye is negative or positive for “more than mild” diabetic retinopathy.<sup>17,18</sup> Consequently, if the screening is positive, an in-person eye examination by an ophthalmologist is required.

Sensitivity of artificial intelligence platforms for detecting diabetic retinopathy is greater than 87%, and specificity is greater than 88%.<sup>15,17,19</sup> With high sensitivity and greater convenience, artificial intelligence

TABLE 1

**American Diabetes Association screening recommendations for diabetic retinopathy in different patient populations**

Patient population	Initial eye examination	Follow-up eye examination interval
Type 1 diabetes	Within 5 years after onset of type 1 diabetes	At least annually <sup>a</sup>
Type 2 diabetes	At time of diagnosis of type 2 diabetes	At least annually <sup>a</sup>
Preexisting diabetes and planning on pregnancy	Before pregnancy	Every trimester and up to 1 year post partum
Gestational diabetes	Not required <sup>b</sup>	Not required <sup>b</sup>

<sup>a</sup>If diabetic retinopathy is symptomatic or sight-threatening, examinations should be more frequent. If  $\geq 1$  annual eye examination shows no evidence of diabetic retinopathy, examinations can occur every 1 to 2 years.

<sup>b</sup>Individuals who develop gestational diabetes do not appear to be at increased risk of developing diabetic retinopathy during pregnancy.

Based on information from references 2,11–13.

platforms can increase the likelihood that patients with signs of diabetic retinopathy will receive a referral to ophthalmology, reducing the screening burden. The cost of hardware and services that come with these platforms is a consideration for primary care practices, and may be a barrier to implementing these systems.<sup>18</sup> However, remote interpretation by ophthalmologists, optometrists, or an artificial intelligence algorithm increases screening rates and provides higher sensitivity and accuracy in detecting diabetic retinopathy than fundoscopic examination done in the primary care setting.<sup>11,20,21</sup>

### Retinopathy predicts diabetes outcomes

Diabetic retinopathy is associated with major systemic complications of diabetes. Its presence and severity have been shown to predict stroke, myocardial infarction, and death.<sup>22–25</sup> Diabetic retinopathy is associated with the risk of diabetic nephropathy and diabetic neuropathy as well, and hence can be used to predict the development and progression of these conditions.<sup>26,27</sup> Primary care physicians can help decrease the risk of diabetes complications by referring patients for comprehensive eye examinations and managing associated comorbidities.

## PREVENTION

Risk factors associated with diabetic retinopathy development and progression include hyperglycemia, dyslipidemia, and high blood pressure. Strict glyce-mic control has been established as absolutely key in preventing diabetic retinopathy progression, but evidence is mixed for targeting dyslipidemia and high blood pressure as measures specifically to prevent or slow the progression of diabetic retinopathy.

### Hyperglycemia

Strict control of hyperglycemia is essential in minimizing the risk of diabetic retinopathy development or progression.<sup>1,28</sup> The Diabetes Control and Complications Trial reported a strong relationship between risk of diabetic retinopathy and mean HbA1c: a decrease of about 10% in HbA1c resulted in a 39% decrease in risk of diabetic retinopathy progression.<sup>8</sup> Long-term follow-up also showed that strict blood glucose control decreased the incidence of progression in severe NPDR, proliferative diabetic retinopathy, and clinically significant macular edema.<sup>29</sup>

### Dyslipidemia

Elevated serum cholesterol and triglyceride levels have been implicated as risk factors for diabetic retinopathy. However, studies of the effect of statin and fibrate treatment specifically on diabetic retinopathy development and progression have produced mixed results.

The Action to Control Cardiovascular Risk in Diabetes (ACCORD) trial<sup>30</sup> investigated intensive glyce-mic control and treatment of dyslipidemia in patients with type 2 diabetes (median baseline values for the dyslipidemia group were high-density lipoprotein cholesterol of 38 mg/dL, low-density lipoprotein cholesterol 93 mg/dL, and triglycerides 162 mg/dL). After 4 years of follow-up, the study reported reduced rates of diabetic retinopathy progression with intensive glyce-mic control combined with fenofibrate and simvastatin treatment vs simvastatin plus placebo. The Fenofibrate Intervention and Event Lowering in Diabetes (FIELD) study<sup>31</sup> reported a decreased need for laser treatment in patients with diabetic retinopathy treated with fenofibrate. Other studies reported that statin therapy decreased the risk and incidence of diabetic



retinopathy,<sup>4,32</sup> while others found that statins do not protect against diabetic retinopathy progression.<sup>33–35</sup>

Despite the uncertainty about the effect of statin and fibrate therapy on diabetic retinopathy outcomes, multiple trials have shown the benefits of statin therapy and lipid control for overall management of diabetes mellitus, including a decreased risk for atherosclerotic cardiovascular disease events, coronary heart disease deaths, and all-cause mortality.<sup>36</sup>

## Blood pressure

The role of blood pressure management in the prevention of diabetic retinopathy has been explored. A Cochrane review showed that although intensive blood pressure control was associated with a reduced risk of diabetic retinopathy development, it did not significantly impact progression of existing diabetic retinopathy compared with less stringent measures of blood pressure control.<sup>37</sup>

## Glucagon-like peptide-1 receptor agonists, rapid HbA1c reduction, and retinopathy

Although glycemic control with insulin or pharmacologic therapies is critical, the evidence is mixed on the effect of glucagon-like peptide-1 (GLP-1) receptor agonists on risk for diabetic retinopathy. Some meta-analyses and trials reported an increased risk of diabetic retinopathy with certain GLP-1 receptor agonists,<sup>38–44</sup> while others reported no significant difference.<sup>45–49</sup> Interestingly, many trials that reported an increased risk included or exclusively studied semaglutide, and many of the studies that found no significant difference reported on other GLP-1 receptor agonists. Furthermore, the increased risk for diabetic retinopathy seems to occur early in treatment and be transient, ranging from 3 months to 3 years after starting a GLP-1 receptor agonist, while the duration of improvement in retinopathy attributable to glycemic control ranges from about 3 years to more than 5 years.<sup>42,50</sup>

A plausible explanation for the potential early increased risk of diabetic retinopathy with GLP-1 receptor agonists is the drastic decrease in HbA1c that occurs when intensively managing diabetes mellitus, a phenomenon that may not necessarily be intrinsic to GLP-1 receptor agonists.<sup>50–52</sup> In a multicenter, randomized clinical trial (Diabetes Control and Complications Trial), the risk of early worsening of diabetic retinopathy was greater in the intensive insulin treatment group compared with the conventional insulin treatment group among patients with type 1 diabetes.<sup>50</sup> Interestingly, statistical analysis showed that the magnitude—but not the rapidity—of reduction in HbA1c was a significant

risk factor for early worsening of diabetic retinopathy in the first 6 months of intensive treatment.<sup>50</sup> A retrospective case-control study reported similar results, with a significant association between large reductions in HbA1c and worsening diabetic retinopathy in patients with uncontrolled type 2 diabetes.<sup>53</sup> Further investigations of drastic reductions in HbA1c, specific pharmacotherapies, and other glucose-lowering treatments such as bariatric surgery are needed to characterize early worsening of diabetic retinopathy and guide the safe management of diabetic retinopathy.

Nevertheless, GLP-1 receptor agonists have clear benefits in weight loss and cardiovascular risk, hypoglycemic risk, and kidney risk management for patients with diabetes mellitus.<sup>38</sup> When weighing the risks and benefits of a GLP-1 receptor agonist, the possible increased risk of development or progression of diabetic retinopathy should be carefully considered, especially if patients have a history of diabetic retinopathy or are already taking other diabetes medications that lower blood glucose. Primary care physicians should prioritize management of diabetes mellitus with a target HbA1c of 7% or lower while being mindful of large reductions of HbA1c when starting diabetes medications such as GLP-1 receptor agonists.<sup>8</sup> Additional studies of GLP-1 receptor agonists with longer follow-up and primary end points for diabetic retinopathy risk assessment are needed. When considering GLP-1 receptor agonists, retinopathy status should be assessed by an ophthalmologist because of the potential initial worsening of retinopathy.

As with any progression of diabetic retinopathy, patients who experience worsening symptoms or signs of diabetic retinopathy in the context of rapid HbA1c reduction from diabetes medications such as GLP-1 receptor agonists should be seen by an ophthalmologist as soon as possible to assess the severity of progression and presence of any complications.<sup>2,8</sup> These complications should be evaluated to determine their impact on next possible steps in management, such as observation, discontinuation of medications, anti-vascular endothelial growth factor (VEGF) injections, intravitreal corticosteroid injections, or surgery.

## MANAGEMENT

Management of patients with diabetic retinopathy depends on the severity of the retinopathy and whether DME is present.<sup>8</sup> Patients with mild, moderate, or severe NPDR have a 15.6%, 44.6%, and 62.6% chance of developing DME, respectively.<sup>54</sup> Owing to the risk of developing complications, follow-up examinations are recommended every 6 to 12 months for those with mild to moderate NPDR and every 2 to 4 months for

patients with severe NPDR and non-high-risk proliferative diabetic retinopathy.<sup>8</sup>

### VEGF injections

Standard treatment of diabetic retinopathy is anti-VEGF injections, which are used as off-label or US Food and Drug Administration–approved treatment for all stages of diabetic retinopathy.<sup>8,55</sup>

**NPDR.** The American Academy of Ophthalmology Preferred Practice Pattern regarding patients with diabetic retinopathy and no DME recommends considering anti-VEGF only in patients with severe NPDR.<sup>8</sup> However, recent studies have shown benefit in patients with milder disease. PANORAMA (Study of the Efficacy and Safety of Intravitreal Aflibercept for the Improvement of Moderately Severe to Severe Non-proliferative Diabetic Retinopathy)<sup>56</sup> and the Diabetic Retinopathy Clinical Research Retina Network Protocol W<sup>57</sup> looked at patients with moderate to severe NPDR and moderately severe to severe NPDR, respectively, both without DME. In these studies, patients treated with anti-VEGF injections had similar vision acuity outcomes compared with sham but a reduced risk of progression to proliferative diabetic retinopathy and development of center-involved DME.

Of US retina specialists treating very severe NPDR without DME, 60% closely monitor the condition and encourage systemic glycemic control, 25% consider anti-VEGF therapy in some patients with poor glycemic control, around 8% consider it in all or most patients, and 3% consider it in some patients with good glucose control and compliance.<sup>58,59</sup> Additionally, among those treating patients with severe NPDR without clinically significant DME, 52% do not recommend anti-VEGF therapy; 39.1% said they would recommend it if extensive peripheral nonperfusion was present on fluorescein angiography, and 27.5% would recommend it if fellow eye pathology were present.<sup>60</sup>

**Proliferative diabetic retinopathy.** Clinical trials have evaluated visual acuity outcomes in patients with proliferative diabetic retinopathy treated with ranibizumab vs panretinal photocoagulation. Gross et al<sup>61</sup> showed that anti-VEGF treatment is noninferior to photocoagulation in patients with and without DME, and Sivaprasad et al<sup>62</sup> showed that anti-VEGF treatment is superior in patients without DME. However, physicians should assess patient adherence, as patients with proliferative diabetic retinopathy treated with panretinal photocoagulation who were lost to follow-up longer than 6 months had better anatomic and functional outcomes compared with those treated with anti-VEGF therapy.<sup>63</sup>

Most ophthalmologists treat patients with high-risk proliferative diabetic retinopathy and center-involved DME with both anti-VEGF therapy and laser. In a survey of US retina specialists, 69.9% of respondents said that they would start anti-VEGF therapy and plan for concurrent or future panretinal photocoagulation; 26% said they would treat with anti-VEGF injections and later assess the need for panretinal photocoagulation.<sup>59</sup>

**DME.** First-line therapy for patients with DME is intravitreal anti-VEGF injections.<sup>8</sup> The RISE and RIDE (Ranibizumab Injection in Subjects With Clinically Significant Macular Edema With Center Involvement Secondary to Diabetes Mellitus) trials showed that ranibizumab significantly improved vision in patients with DME and reduced diabetic retinopathy severity across all stages.<sup>64</sup> Anti-VEGF treatment is initiated with monthly injections for 3 to 6 months.<sup>65</sup> The Diabetic Retinopathy Clinical Research Retina Network Protocol V evaluated patients with center-involved DME and visual acuity of 20/25 or better. It found that these patients should be observed with follow-up every 2 to 4 months, as initial treatment with either aflibercept or laser did not result in significant vision improvements compared with observation.<sup>66</sup>

Owing to insurance and costs, most patients are first treated with bevacizumab and, after treatment failure is demonstrated, are switched to another anti-VEGF therapy.<sup>67</sup> However, in the Diabetic Retinopathy Clinical Research Retina Network Protocol T trial comparing the efficacy of intravitreal aflibercept, bevacizumab, and ranibizumab in center-involved DME, patients with a visual acuity of 20/50 or worse receiving bevacizumab had worse 2-year visual acuity outcomes compared with those taking aflibercept.<sup>8</sup> Protocol AC, a multicenter, randomized clinical trial at 54 US clinical sites, showed that patients who first received bevacizumab and then switched to aflibercept due to nonresponse had noninferior 2-year vision outcomes compared with those taking aflibercept only.<sup>67,68</sup>

The efficacy of fixed-dose anti-VEGF regimens has been shown in clinical trials, but most clinicians use an as-needed or treat-and-extend approach to reduce treatment burden.<sup>69</sup> Patients on the treat-and-extend treatment regimen are administered anti-VEGF at each visit, and the intervals between appointments are extended, maintained, or decreased based on the presence of macular edema, as determined by optical coherence tomography imaging.<sup>70</sup> Treat-and-extend has been shown to have similar vision and anatomic outcomes compared with as-needed or fixed-dose regimens in patients with center-involved DME, with treat-and-extend requiring significantly fewer injections compared with fixed dosing.<sup>70,71</sup>

Extended treatment intervals can be used with other anti-VEGF agents that have received US Food and Drug Administration approval for treatment of center-involved DME.<sup>72,73</sup> In the double-masked 96-week PHOTON (Study of a High-Dose Aflibercept in Participants With Diabetic Eye Disease) trial,<sup>74</sup> patients with center-involved DME were randomized to receive aflibercept 8 mg every 12 or 16 weeks after 3 monthly doses or aflibercept 2 mg every 8 weeks after 5 monthly doses. Aflibercept 8 mg provided noninferior outcomes with fewer injections. In the YOSEMITE and RHINE (Efficacy and Safety of Faricimab in Participants With Diabetic Macular Edema) trials, faricimab also had extended durability in treating patients with center-involved DME.<sup>75</sup>

## Laser surgery

Laser is used as both primary and adjunctive treatment of diabetic retinopathy and DME. Multiple studies have demonstrated anti-VEGFs to be more effective than focal laser photocoagulation in improving visual acuity in patients with center-involved DME.<sup>8,76–79</sup> In a survey of US retina specialists treating patients with clinically significant DME on anti-VEGF therapy, 59.2% treated less than 5% of patients with focal or grid laser, and 21.7% treated 5% to 10% of patients with focal or grid laser.<sup>76</sup> The American Academy of Ophthalmology Preferred Practice Pattern clinical guidelines advocate for focal or grid laser as the preferred treatment modality for noncenter-involved DME, citing lack of research on this specific pathology.<sup>8</sup> Despite these guidelines, ongoing debate continues regarding the role of laser therapy in preventing vision loss.<sup>77,78</sup>

## Intravitreal steroids

Intravitreally injected steroids are effective in treating DME, with visual acuity gains similar to anti-VEGF treatment.<sup>79</sup> However, because of the risk of elevated intraocular pressure and cataract progression, intravitreal steroids are second-line therapies.<sup>8,79</sup>

## CONCLUSION

Clinicians managing patients with diabetes mellitus must recognize the risks and complications associated with diabetic retinopathy and ensure that proper screening and referral processes are in place. Technological advancements like retinal photography with remote interpretation can reduce the burden of screening for diabetic retinopathy, but there are device and service costs. Furthermore, awareness of advances in diabetes medications, which effectively control blood glucose levels and subsequently prevent diabetic retinopathy and its direct and related complications, is essential. The treatment of diabetic retinopathy and DME primarily involves anti-VEGF therapy. This therapy, while being the standard of care, may impose a significant treatment burden on patients. Therefore, it is imperative for clinicians to leverage new tools for early detection and new medications for effective management of diabetes and diabetic retinopathy. ■

## DISCLOSURES

Dr Singh has disclosed consulting for Alcon Lab, Apellis Pharmaceuticals, EyePoint Pharmaceuticals, Genentech/Roche, Iveric Bio, Regeneron, and Zeiss Meditec, and conducting research as a primary investigator for Janssen Pharmaceuticals. The other authors report no relevant financial relationships which, in the context of their contributions, could be perceived as a potential conflict of interest.

## REFERENCES

- Khalil H. Diabetes microvascular complications—a clinical update. *Diabetes Metab Syndr* 2017; 11(suppl 1):S133–S139. doi:10.1016/j.dsx.2016.12.022
- American Diabetes Association Professional Practice Committee. 12. Retinopathy, neuropathy, and foot care: standards of care in diabetes—2024. *Diabetes Care* 2024; 47(suppl 1):S231–S243. doi:10.2337/dc24-S012
- Centers for Disease Control and Prevention. National Diabetes Fact Sheet, 2011. <https://stacks.cdc.gov/view/cdc/13329>. Accessed July 19, 2024.
- Kang EY, Chen TH, Garg SJ, et al. Association of statin therapy with prevention of vision-threatening diabetic retinopathy. *JAMA Ophthalmol* 2019; 137(4):363–371. doi:10.1001/jamaophthalmol.2018.6399
- Teo ZL, Tham YC, Yu M, et al. Global prevalence of diabetic retinopathy and projection of burden through 2045: systematic review and meta-analysis. *Ophthalmology* 2021; 128(11):1580–1591. doi:10.1016/j.ophtha.2021.04.027
- Global Burden of Disease 2019 Blindness and Vision Impairment Collaborators. Causes of blindness and vision impairment in 2020 and trends over 30 years, and prevalence of avoidable blindness in relation to VISION 2020: the right to sight: an analysis for the Global Burden of Disease study [published correction appears in *Lancet Glob Health* 2021; 9(4):e408]. *Lancet Glob Health* 2021; 9(2):e144–e160. doi:10.1016/S2214-109X(20)30489-7
- Reddy NG, Venkatesh R, Jayadev C, et al. Diabetic retinopathy and diabetic macular edema in people with early-onset diabetes. *Clin Diabetes* 2022; 40(2):222–232. doi:10.2337/cd21-0110
- Flaxel CJ, Adelman RA, Bailey ST, et al. Diabetic retinopathy Preferred Practice Pattern® [published correction appears in *Ophthalmology* 2020; 127(9):1279]. *Ophthalmology* 2020; 127(1):P66–P145. doi:10.1016/j.ophtha.2019.09.025
- Jampol LM, Glassman AR, Sun J. Evaluation and care of patients with diabetic retinopathy. *N Engl J Med* 2020; 382(17):1629–1637. doi:10.1056/NEJMr1909637
- Lascar N, Brown J, Pattison H, Barnett AH, Bailey CJ, Bellary S. Type 2 diabetes in adolescents and young adults. *Lancet Diabetes Endocrinol* 2018; 6(1):69–80. doi:10.1016/S2213-8587(17)30186-9
- Jani PD, Forbes L, Choudhury A, Preisser JS, Viera AJ, Garg S. Evaluation of diabetic retinal screening and factors for ophthalmology referral in a telemedicine network. *JAMA Ophthalmol* 2017; 135(7):706–714. doi:10.1001/jamaophthalmol.2017.1150
- Taheri S. Type 2 diabetes remission: a new mission in diabetes care. *Diabetes Care* 2024; 47(1):47–49. doi:10.2337/dci23-0062



13. Widyaputri F, Rogers SL, Kandasamy R, Shub A, Symons RCA, Lim LL. Global estimates of diabetic retinopathy prevalence and progression in pregnant women with preexisting diabetes: a systematic review and meta-analysis. *JAMA Ophthalmol* 2022; 140(5):486–494. doi:10.1001/jamaophthalmol.2022.0050
14. US Food and Drug Administration. FDA permits marketing of artificial intelligence-based device to detect certain diabetes-related eye problems. <https://www.fda.gov/news-events/press-announcements/fda-permits-marketing-artificial-intelligence-based-device-detect-certain-diabetes-related-eye>. Accessed July 19, 2024.
15. US Department of Health and Human Services; ClinicalTrials.gov. Efficacy and safety of AEYE-DS software device for automated detection of diabetic retinopathy from digital fundus images. Updated August 1, 2023. <https://clinicaltrials.gov/study/NCT04612868>. Accessed July 19, 2024.
16. US Department of Health and Human Services; ClinicalTrials.gov. Assessment of EyeArt as an automated diabetic retinopathy screening tool. Updated July 30, 2018. <https://clinicaltrials.gov/study/NCT03112005>. Accessed July 19, 2024.
17. Abramoff MD, Lavin PT, Birch M, Shah N, Folk JC. Pivotal trial of an autonomous AI-based diagnostic system for detection of diabetic retinopathy in primary care offices. *NPJ Digit Med* 2018; 1:39. doi:10.1038/s41746-018-0040-6
18. Savoy M. IDx-DR for diabetic retinopathy screening. *Am Fam Physician* 2020; 101(5):307–308. PMID:32109029
19. Lim JJ, Regillo CD, Satta SR, et al. Artificial intelligence detection of diabetic retinopathy: subgroup comparison of the EyeArt system with ophthalmologists' dilated examinations. *Ophthalmol Sci* 2022; 3(1):100228. doi:10.1016/j.xops.2022.100228
20. Shah AR, Wu R. Disparities in diabetes-related retinal disease and approaches to improve screening rates. In: *A Practical Guide to Diabetes-Related Eye Care*. Arlington, VA: American Diabetes Association; 2022:16–19.
21. Song A, Lusk JB, Roh KM, et al. Practice patterns of fundoscopic examination for diabetic retinopathy screening in primary care. *JAMA Netw Open* 2022; 5(6):e2218753. doi:10.1001/jamanetworkopen.2022.18753
22. Wang Z, Cao D, Zhuang X, et al. Diabetic retinopathy may be a predictor of stroke in patients with diabetes mellitus. *J Endocr Soc* 2022; 6(8):bvac097. doi:10.1210/endo/bvac097
23. Hu K, Jiang M, Zhou Q, et al. Association of diabetic retinopathy with stroke: a systematic review and meta-analysis. *Front Neurol* 2021; 12:626996. doi:10.3389/fneur.2021.626996
24. Hsu CY, Lee CM, Chou KY, et al. The association of diabetic retinopathy and cardiovascular disease: a 13-year nationwide population-based cohort study. *Int J Environ Res Public Health* 2021; 18(15):8106. doi:10.3390/ijerph18158106
25. Modjtahedi BS, Wu J, Luong TQ, Gandhi NK, Fong DS, Chen W. Severity of diabetic retinopathy and the risk of future cerebrovascular disease, cardiovascular disease, and all-cause mortality. *Ophthalmology* 2021; 128(8):1169–1179. doi:10.1016/j.ophtha.2020.12.019
26. Saini DC, Kochar A, Poonia R. Clinical correlation of diabetic retinopathy with nephropathy and neuropathy. *Indian J Ophthalmol* 2021; 69(11):3364–3368. doi:10.4103/ijo.IJO\_1237\_21
27. Joshi D, Khan MA, Singh A. A clinical study of the association and risk factors for lower limb neuropathy in patients with diabetic retinopathy. *J Family Med Prim Care* 2020; 9(4):1891–1895. doi:10.4103/jfmpc.jfmpc\_231\_20
28. Diabetes Control and Complications Trial Research Group, Nathan DM, Genuth S, et al. The effect of intensive treatment of diabetes on the development and progression of long-term complications in insulin-dependent diabetes mellitus. *N Engl J Med* 1993; 329(14):977–986. doi:10.1056/NEJM199309303291401
29. Diabetes Control and Complications Trial/Epidemiology of Diabetes Interventions and Complications Research Group, Lachin JM, Genuth S, Cleary P, Davis MD, Nathan DM. Retinopathy and nephropathy in patients with type 1 diabetes four years after a trial of intensive therapy [published correction appears in *N Engl J Med* 2000; 342(18):1376]. *N Engl J Med* 2000; 342(6):381–389. doi:10.1056/NEJM200002103420603
30. ACCORD Study Group; ACCORD Eye Study Group, Chew EY, et al. Effects of medical therapies on retinopathy progression in type 2 diabetes [published correction appears in *N Engl J Med* 2011; 364(2):190] [published correction appears in *N Engl J Med* 2012; 367(25):2458]. *N Engl J Med* 2010; 363(3):233–244. doi:10.1056/NEJMoa1001288
31. Keech A, Simes RJ, Barter P, et al. Effects of long-term fenofibrate therapy on cardiovascular events in 9795 people with type 2 diabetes mellitus (the FIELD study): randomised controlled trial [published correction appears in *Lancet* 2006; 368(9545):1420] [published correction appears in *Lancet* 2006; 368(9545):1415]. *Lancet* 2005; 366(9500):1849–1861. doi:10.1016/S0140-6736(05)67667-2
32. Liu J, Wu YP, Qi JJ, Yue ZP, Hu CD. Effect of statin therapy on diabetes retinopathy in people with type 2 diabetes mellitus: a meta-analysis. *Clin Appl Thromb Hemost* 2021; 27:10760296211040109. doi:10.1177/10760296211040109
33. Mozetic V, Pacheco RL, Latorraca COC, Riera R. Statins and/or fibrates for diabetic retinopathy: a systematic review and meta-analysis. *Diabetol Metab Syndr* 2019; 11:92. doi:10.1186/s13098-019-0488-9
34. Chung YR, Park SW, Choi SY, et al. Association of statin use and hypertriglyceridemia with diabetic macular edema in patients with type 2 diabetes and diabetic retinopathy. *Cardiovasc Diabetol* 2017; 16(1):4. doi:10.1186/s12933-016-0486-2
35. Klein BE, Myers CE, Howard KP, Klein R. Serum lipids and proliferative diabetic retinopathy and macular edema in persons with long-term type 1 diabetes mellitus: the Wisconsin Epidemiologic Study of Diabetic Retinopathy. *JAMA Ophthalmol* 2015; 133(5):503–510. doi:10.1001/jamaophthalmol.2014.5108
36. American Diabetes Association. 10. Cardiovascular disease and risk management: standards of medical care in diabetes-2021 [published correction appears in *Diabetes Care* 2021; 44(9):2183–2185]. *Diabetes Care* 2021; 44(suppl 1):S125–S150. doi:10.2337/dc21-S010
37. Do DV, Han G, Abariga SA, Sleilati G, Vedula SS, Hawkins BS. Blood pressure control for diabetic retinopathy. *Cochrane Database Syst Rev* 2023; 3(3):CD006127. doi:10.1002/14651858.CD006127.pub3
38. Marso SP, Bain SC, Consoli A, et al. Semaglutide and cardiovascular outcomes in patients with type 2 diabetes. *N Engl J Med* 2016; 375(19):1834–1844. doi:10.1056/NEJMoa1607141
39. Wang F, Mao Y, Wang H, Liu Y, Huang P. Semaglutide and diabetic retinopathy risk in patients with type 2 diabetes mellitus: a meta-analysis of randomized controlled trials. *Clin Drug Investig* 2022; 42(1):17–28. doi:10.1007/s40261-021-01110-w
40. Albert SG, Wood EM, Ahir V. Glucagon-like peptide 1-receptor agonists and A1c: Good for the heart but less so for the eyes? *Diabetes Metab Syndr* 2023; 17(1):102696. doi:10.1016/j.dsx.2022.102696
41. Tsapas A, Avgerinos I, Karagiannis T, et al. Comparative effectiveness of glucose-lowering drugs for type 2 diabetes: a systematic review and network meta-analysis. *Ann Intern Med* 2020; 173(4):278–286. doi:10.7326/M20-0864
42. Bethel MA, Diaz R, Castellana N, Bhattacharya I, Gerstein HC, Lakshmanan MC. HbA1c change and diabetic retinopathy during GLP-1 receptor agonist cardiovascular outcome trials: a meta-analysis and meta-regression. *Diabetes Care* 2021; 44(1):290–296. doi:10.2337/dc20-1815
43. Husain M, Birkenfeld AL, Donsmark M, et al. Oral semaglutide and cardiovascular outcomes in patients with type 2 diabetes. *N Engl J Med* 2019; 381(9):841–851. doi:10.1056/NEJMoa1901118
44. Yoshida Y, Joshi P, Barri S, et al. Progression of retinopathy with glucagon-like peptide-1 receptor agonists with cardiovascular benefits in type 2 diabetes—a systematic review and meta-analysis. *J Diabetes Complications* 2022; 36(8):108255. doi:10.1016/j.jdiacomp.2022.108255
45. Marso SP, Daniels GH, Brown-Frandsen K, et al. Liraglutide and cardiovascular outcomes in type 2 diabetes. *N Engl J Med* 2016; 375(4):311–322. doi:10.1056/NEJMoa1603827
46. Bethel MA, Mentz RJ, Merrill P, et al. Microvascular and cardiovascular outcomes according to renal function in patients treated with once-weekly exenatide: insights from the EXSCEL Trial. *Diabetes Care* 2020; 43(2):446–452. doi:10.2337/dc19-1065

47. Wei J, Yang B, Wang R, et al. Risk of stroke and retinopathy during GLP-1 receptor agonist cardiovascular outcome trials: an eight RCTs meta-analysis. *Front Endocrinol (Lausanne)* 2022; 13:1007980. doi:10.3389/fendo.2022.1007980
48. Zhang X, Shao F, Zhu L, Ze Y, Zhu D, Bi Y. Cardiovascular and microvascular outcomes of glucagon-like peptide-1 receptor agonists in type 2 diabetes: a meta-analysis of randomized controlled cardiovascular outcome trials with trial sequential analysis. *BMC Pharmacol Toxicol* 2018; 19(1):58. doi:10.1186/s40360-018-0246-x
49. Gerstein HC, Colhoun HM, Dagenais GR, et al. Dulaglutide and cardiovascular outcomes in type 2 diabetes (REWIND): a double-blind, randomised placebo-controlled trial. *Lancet* 2019; 394(10193):121–130. doi:10.1016/S0140-6736(19)31149-3
50. Bain SC, Klufas MA, Ho A, Matthews DR. Worsening of diabetic retinopathy with rapid improvement in systemic glucose control: a review. *Diabetes Obes Metab* 2019; 21(3):454–466. doi:10.1111/dom.13538
51. Vilsbøll T, Bain SC, Leiter LA, et al. Semaglutide, reduction in glycosylated haemoglobin and the risk of diabetic retinopathy. *Diabetes Obes Metab* 2018; 20(4):889–897. doi:10.1111/dom.13172
52. Poonosamy J, Lopes P, Huret P, et al. Impact of intensive glycemic treatment on diabetes complications—a systematic review. *Pharmaceutics* 2023; 15(7):1791. doi:10.3390/pharmaceutics15071791
53. Shurter A, Genter P, Ouyang D, Ipp E. Euglycemic progression: worsening of diabetic retinopathy in poorly controlled type 2 diabetes in minorities. *Diabetes Res Clin Pract* 2013; 100(3):362–367. doi:10.1016/j.diabres.2013.03.018
54. Moshfeghi A, Garmo V, Sheinson D, Ghanekar A, Abbass I. Five-year patterns of diabetic retinopathy progression in US clinical practice. *Clin Ophthalmol* 2020; 14:3651–3659. doi:10.2147/OPTH.S275968
55. Bahr TA, Bakri SJ. Update on the management of diabetic retinopathy: anti-VEGF agents for the prevention of complications and progression of nonproliferative and proliferative retinopathy. *Life (Basel)* 2023; 13(5):1098. doi:10.3390/life13051098
56. Brown DM, Wykoff CC, Boyer D, et al. Evaluation of intravitreal aflibercept for the treatment of severe nonproliferative diabetic retinopathy: results from the PANORAMA randomized clinical trial. *JAMA Ophthalmol* 2021; 139(9):946–955. doi:10.1001/jamaophthalmol.2021.2809
57. Maturi RK, Glassman AR, Josic K, et al. Four-year visual outcomes in the Protocol W randomized trial of intravitreal aflibercept for prevention of vision-threatening complications of diabetic retinopathy [published correction appears in *JAMA* 2023; 28;329(12):1034]. *JAMA* 2023; 329(5):376–385. doi:10.1001/jama.2022.52029
58. Tieger MG, Bauman CR. Severe diabetic retinopathy without diabetic macular edema. *Retinal Physician* 2022; 19:18–21.
59. American Society of Retina Specialists. ASRS 2021 Global Trends in Retina. <https://www.asrs.org/content/documents/2021-global-trends-survey-highlights.pdf> Accessed July 19, 2024.
60. Hahn P, ed. ASRS 2023 Preferences and Trends Membership Survey. Chicago, IL: American Society of Retina Specialists; 2023.
61. Writing Committee for the Diabetic Retinopathy Clinical Research Network, Gross JG, Glassman AR, et al. Panretinal photocoagulation vs intravitreal ranibizumab for proliferative diabetic retinopathy: a randomized clinical trial [published correction appears in *JAMA* 2016; 315(9):944] [published correction appears in *JAMA* 2019; 321(10):1008]. *JAMA* 2015; 314(20):2137–2146. doi:10.1001/jama.2015.15217
62. Sivaprasad S, Prevost AT, Vasconcelos JC, et al. Clinical efficacy of intravitreal aflibercept versus panretinal photocoagulation for best corrected visual acuity in patients with proliferative diabetic retinopathy at 52 weeks (CLARITY): a multicentre, single-blinded, randomised, controlled, phase 2b, non-inferiority trial. *Lancet* 2017; 389(10085):2193–2203. doi:10.1016/S0140-6736(17)31193-5
63. Obeid A, Su D, Patel SN, et al. Outcomes of eyes lost to follow-up with proliferative diabetic retinopathy that received panretinal photocoagulation versus intravitreal anti-vascular endothelial growth factor. *Ophthalmology* 2019; 126(3):407–413. doi:10.1016/j.opthta.2018.07.027
64. Wykoff CC, Eichenbaum DA, Roth DB, Hill L, Fung AE, Haskova Z. Ranibizumab induces regression of diabetic retinopathy in most patients at high risk of progression to proliferative diabetic retinopathy. *Ophthalmol Retina* 2018; 2(10):997–1009. doi:10.1016/j.oret.2018.06.005
65. Figueira J, Henriques J, Carneiro Â, et al. Guidelines for the management of center-involving diabetic macular edema: treatment options and patient monitoring. *Clin Ophthalmol* 2021; 15:3221–3230. doi:10.2147/OPTH.S318026
66. Baker CW, Glassman AR, Beaulieu WT, et al. Effect of initial management with aflibercept vs laser photocoagulation vs observation on vision loss among patients with diabetic macular edema involving the center of the macula and good visual acuity: a randomized clinical trial. *JAMA* 2019; 321(19):1880–1894. doi:10.1001/jama.2019.5790
67. Jhaveri CD, Glassman AR, Ferris FL 3rd, et al. Aflibercept monotherapy or bevacizumab first for diabetic macular edema. *N Engl J Med* 2022; 387(8):692–703. doi:10.1056/NEJMoa2204225
68. Diabetic Retinopathy Clinical Research Network, Wells JA, Glassman AR, et al. Aflibercept, bevacizumab, or ranibizumab for diabetic macular edema. *N Engl J Med* 2015; 372(13):1193–1203. doi:10.1056/NEJMoa1414264
69. Chaudhary V; Retina Evidence and Trials International Alliance (RETINA) Study Group. The need for a pragmatic, individualized treat-and-extend (T&E) treatment paradigm for centre-involving diabetic macular oedema. *Eye (Lond)* 2023; 37(12):2431–2433. doi:10.1038/s41433-023-02455-6
70. Sarohia GS, Nanji K, Khan M, et al. Treat-and-extend versus alternate dosing strategies with anti-vascular endothelial growth factor agents to treat center involving diabetic macular edema: a systematic review and meta-analysis of 2,346 eyes. *Surv Ophthalmol* 2022; 67(5):1346–1363. doi:10.1016/j.survophthal.2022.04.003
71. Payne JF, Wykoff CC, Clark WL, et al. Randomized trial of treat and extend ranibizumab with and without navigated laser versus monthly dosing for diabetic macular edema: TREX-DME 2-year outcomes. *Am J Ophthalmol* 2019; 202:91–99. doi:10.1016/j.ajo.2019.02.005
72. Regeneron Pharmaceuticals, Inc. Eylea. Highlights of prescribing information. [https://www.regeneron.com/downloads/eylea\\_fpi.pdf](https://www.regeneron.com/downloads/eylea_fpi.pdf). Accessed July 19, 2024.
73. Genentech, Inc. Vabysmo. Highlights of prescribing information. [https://www.gene.com/download/pdf/vabysmo\\_prescribing.pdf](https://www.gene.com/download/pdf/vabysmo_prescribing.pdf). Accessed July 19, 2024.
74. Do DV. Aflibercept 8 mg for diabetic macular edema: 48-week results from the phase 2/3 PHOTON Trial. *Invest Ophthalmol Vis Sci* 2023; 64(8):2814 (abstract). <https://iovs.arvojournals.org/article.aspx?articleid=2787521&resultClick=1>. Accessed July 19, 2024.
75. Wykoff CC, Abreu F, Adamis AP, et al. Efficacy, durability, and safety of intravitreal faricimab with extended dosing up to every 16 weeks in patients with diabetic macular oedema (YOSEMITE and RHINE): two randomised, double-masked, phase 3 trials. *Lancet* 2022; 399(10326):741–755. doi:10.1016/S0140-6736(22)00018-6
76. American Society of Retina Specialists. ASRS 2022 Global Trends in Retina. <https://www.asrs.org/content/documents/2022-asrs-global-trends-in-retina-survey.pdf>. Accessed July 19, 2024.
77. Zur D, Loewenstein A. Should we still be performing macular laser for non-centre involving diabetic macular oedema? Yes. *Eye (Lond)* 2022; 36(3):483–484. doi:10.1038/s41433-021-01793-7
78. Mueller I, Talks JS. Should we still be performing macular laser for non-centre involving diabetic macular oedema? No. *Eye (Lond)* 2022; 36(3):485–486. doi:10.1038/s41433-021-01787-5
79. Patil NS, Mihalache A, Hatamnejad A, Popovic MM, Kertes PJ, Muni RH. Intravitreal steroids compared with anti-VEGF treatment for diabetic macular edema: a meta-analysis. *Ophthalmol Retina* 2023; 7(4):289–299. doi:10.1016/j.oret.2022.10.008

Address: Rishi P. Singh, MD, Cole Eye Institute, i-32, Cleveland Clinic, 9500 Euclid Avenue, Cleveland, OH 44195; [singhr@ccf.org](mailto:singhr@ccf.org)