

Rhea Ahuja, MDDepartments of Dermatology and Venereology,
All India Institute of Medical Sciences,
New Delhi, India**Purn Pragya, MBBS**Departments of Dermatology and Venereology,
All India Institute of Medical Sciences,
New Delhi, India

Stiff hands in a man with type 1 diabetes

A 23-YEAR-OLD MAN with type 1 diabetes presented with stiffness in both hands that had progressively worsened over the previous 6 months. He had trouble completely flexing or extending the small joints of his hands, resulting in the inability to make a fist or place his hands flat on a surface.

On examination, his skin looked waxy, yellowish, and hard. He was unable to press the palmar surfaces of the interphalangeal joints together, despite maximal effort, thus demonstrating the prayer sign (Figure 1). He did not have a history of pain, paresthesia, or early morning stiffness.

He had no palpable nodular or cord-like swelling on the palmar aspect or preferential involvement of the medial 2 fingers, as seen in Dupuytren contracture. Tinel and Phalen tests were negative, nor was there any tingling or numbness in any of the fingers, ruling out carpal tunnel syndrome. There were no signs of sclerodactyly, loss of finger-pad contour, Raynaud phenomenon, or associated digital tip ulcers or scars suggestive of systemic sclerosis.

The patient's glycemic management was poor, as evidenced by a recent hemoglobin A1c of 7.2% (reference range 4% to 5.7%). He was on injectable insulin for the past 6 years, with frequent dose titrations because of poor control.

Funduscopy showed severe nonproliferative diabetic retinopathy in the right eye and proliferative diabetic retinopathy in the left eye. Urine tests did not show any microalbuminuria. A diagnosis of diabetic cheiroarthropathy was made based on the patient's inability to completely extend or flex the small joints of his hand, along with the waxy and yellowish thickening of his palmar skin.

The patient was advised to begin physiotherapy and increase his dosage of both long-acting and regu-

doi:10.3949/cjcm.90a.23046

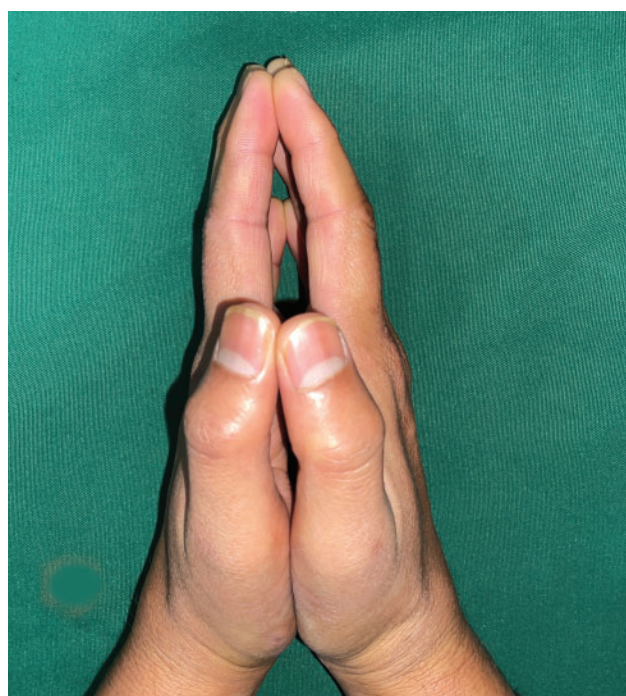


Figure 1. The prayer sign in diabetic cheiroarthropathy, ie, the inability to completely press the palmar aspect of interphalangeal joints together despite maximal effort.

lar insulin. However, after 6 weeks, no improvement in his hand stiffness was observed. He was advised to continue physiotherapy and injectable insulin. He was thereafter lost to follow-up.

■ DIABETIC CHEIROARTHROPATHY

Diabetic cheiroarthropathy is a recognized complication of type 1 and type 2 diabetes. It is known to occur in 18.3% to 28.5% of patients with diabetes^{1,2} and is more common in those with type 1 diabetes.³ Increased

blood glucose leads to glycosylation and cross-linking of collagen, hindering its degradation and resulting in tight, waxy skin over the hands. An association between the severity of joint mobility restriction and the presence of diabetes-related microvascular complications has been reported.¹ Our patient also had associated diabetic retinopathy but no nephropathy.

■ DIFFERENTIAL DIAGNOSIS OF STIFF HANDS

Dupuytren contracture mimics diabetic cheiroarthropathy and has been reported in 16% to 42% of patients with diabetes.^{4,5} It involves thickening of the palmar aponeurosis, leading to the formation of nodules and flexion contractures, commonly affecting the fourth finger. However, in our patient, limited joint mobility was observed in all four fingers, without the presence of taut fibrotic bands.

Flexor tenosynovitis is another condition that mimics diabetes-related cheiroarthropathy,⁶ but it differs in that the contracture is not fixed and can be released, which produces a distinct snap.²

Magnetic resonance imaging has revealed thickening of the flexor tendon sheaths,⁷ but this finding is nonspecific and should be interpreted within the appropriate clinical context.

■ REFERENCES

1. Paul A, Gnanamoorthy K. The association of diabetic cheiroarthropathy with microvascular complications of type 2 diabetes mellitus: a cross-sectional study. *Cureus* 2023; 15(3):e36701. doi:10.7759/cureus.36701
2. Ravindran Rajendran S, Bhansali A, Walia R, Dutta P, Bansal V, Shanmugasundar G. Prevalence and pattern of hand soft-tissue changes in type 2 diabetes mellitus. *Diabetes Metab* 2011; 37(4): 312–317. doi:10.1016/j.diabet.2010.09.008
3. Rydberg M, Zimmerman M, Gottsäter A, Svensson AM, Eeg-Olofsson K, Dahlin LB. Diabetic hand: prevalence and incidence of diabetic hand problems using data from 1.1 million inhabitants in southern Sweden. *BMJ Open Diabetes Res Care* 2022; 10(1):e002614. doi:10.1136/bmjdr-2021-002614
4. Noble J, Heathcote JG, Cohen H. Diabetes mellitus in the aetiology of Dupuytren's disease. *J Bone Joint Surg Br* 1984; 66(3):322–325. doi:10.1302/0301-620X.66B3.6725338
5. Loos B, Puschkin V, Horch RE. 50 years experience with Dupuytren's

■ TREATMENT RECOMMENDATIONS

The primary focus of treatment lies in improving glycemic control and implementing physical therapy. There have been reports suggesting symptom relief, improved joint mobility, and overall improvement with these interventions.⁸ Unfortunately, in our patient, significant improvement was not observed. Symptom-targeted therapies like anti-inflammatory drugs, analgesics, and intralesional corticosteroids have also been used, but their effectiveness is limited. Improving glycemic control remains the cornerstone of management to prevent further progression and irreversible disability.⁹

Limited joint mobility, or diabetic cheiroarthropathy,⁶ is a commonly occurring but often overlooked complication in patients with diabetes. This is important to recognize not only because of its potential to cause severe disability, but also because it is often associated with diabetes-related microvascular complications. ■

■ DISCLOSURES

The authors report no relevant financial relationships which, in the context of their contributions, could be perceived as a potential conflict of interest.

contracture in the Erlangen University Hospital—a retrospective analysis of 2919 operated hands from 1956 to 2006. *BMC Musculoskelet Disord* 2007; 8:60. doi:10.1186/1471-2474-8-60

6. Gerrits EG, Landman GW, Nijenhuis-Rosien L, Bilo HJ. Limited joint mobility syndrome in diabetes mellitus: a minireview. *World J Diabetes* 2015; 6(9):1108–1112. doi:10.4239/wjd.v6.i9.1108
7. Khanna G, Ferguson P. MRI of diabetic cheiroarthropathy [published correction appears in *AJR Am J Roentgenol* 2007; 188(5):1170]. *AJR Am J Roentgenol* 2007; 188(1):W94–W95. doi:10.2214/AJR.06.0672
8. Cherqaoui R, McKenzie S, Nunlee-Bland G. Diabetic cheiroarthropathy: a case report and review of the literature. *Case Rep Endocrinol* 2013; 2013:257028. doi:10.1155/2013/257028
9. Abate M, Schiavone C, Salini V, Andia I. Management of limited joint mobility in diabetic patients. *Diabetes Metab Syndr Obes* 2013; 6:197–207. doi:10.2147/DMSO.S33943

Address: Rhea Ahuja, MD, Departments of Dermatology and Venereology, All India Institute of Medical Sciences, Fourth Floor, Teaching Block, Ansari Nagar, New Delhi 110029, India; ahujarhea1@gmail.com