

# FIBROMAS OF THE OVARY SIMULATING MALIGNANT TUMORS

GEORGE CRILE, Jr., M.D.

Fibromas of the ovary are benign tumors, their removal is attended by little risk, and the operation is followed by complete and permanent alleviation of the patient's symptoms. Because prior to operation the syndrome is frequently interpreted as being the result of an extensive pelvic malignancy, the dramatic reversal of a poor prognosis and the patient's complete recovery are exceptionally gratifying to both patient and physician.

Fibromas of the ovary may be divided into two groups. (1) The small, symptomless, "incidental" fibromas, 1 or 2 cm. in diameter, which are found in the course of laparotomies, are of no clinical significance and will not be discussed. (2) In the second group are the rapidly growing fibromas of the ovary which attain large size with surprising rapidity, and occur characteristically in patients well beyond the menopause. They tend to produce ascites or to become twisted on their pedicles and form a large, fixed, tender mass in the pelvis. Because these tumors occur in women of the "cancer age" and grow so fast that it seems inconceivable that they could be benign, and because they are frequently associated with ascites and fixation of the tumor mass, it is little wonder that at first such tumors are frequently thought to be malignant and are only recognized as benign at operation.

The latter type of fibroma of the ovary is not common. In the last twelve years, only seven such tumors have been removed at the Cleveland Clinic Hospital. In each instance the patient has been over 50 years of age.

According to the symptoms produced these tumors may be divided into three groups.

Group 1. The first type is the painless, rapidly enlarging, abdominal tumor which feels like a fibroid on examination, but tends to be harder and does not seem to be attached to the uterus. In one instance a tumor nearly as large as a football was found in an elderly woman who had had a pelvic examination by a competent physician less than four years previously and had been told that the pelvis was perfectly normal at that time. In other instances the patients themselves have noted the extreme rapidity with which the tumors enlarge. The sudden appearance and rapid enlargement of a hard pelvic mass in a woman in her sixties naturally cannot fail to arouse the suspicion of malignancy.

*Case 1.* A married woman, aged 67, complained of constipation and indigestion. Upon examination the entire pelvis was found to be filled with a large nodular mass. It

## FIBROMAS OF THE OVARY SIMULATING MALIGNANT TUMORS

could not be determined whether this mass arose from the uterus or adnexa. The patient gave a history of having had a normal pelvis upon examination four years previously by a competent physician, who confirmed the report.

In view of the rapid enlargement of the tumor a malignancy of the ovary was suspected, and operation was advised. At the time of operation a fibroma of the right ovary, weighing 417 grams, was found. The patient has been well since the operation.

Group 2. The symptoms produced by the second category of fibromas of the ovary result from torsion of the pedicles. As a rule the patient complains of abdominal pain. These tumors do not tend to be adherent, and their pedicles are often long. It is not surprising, therefore, that the tumor tends to rotate in the abdomen with associated torsion of the pedicle and interference with the blood supply of the tumor. When this occurs, the tumor becomes necrotic and adherent to the pelvic peritoneum, and upon pelvic examination a hard, fixed, slightly tender mass is found to fill the pelvis. In these cases a hard, fixed, degenerating fibroma of the ovary may be almost indistinguishable from the so-called "frozen pelvis" associated with advanced carcinoma of the pelvis.

*Case 2.* An unmarried woman, aged 64, complained of abdominal distention and pain, constipation and weakness. A diagnosis of carcinoma of the colon had been made on the basis of roentgenograms at another hospital. On pelvic examination a large, fixed, tender mass was felt. Proctoscopic examination was normal, and x-ray of the colon showed some deformity from an extrinsic tumor and a few small diverticula. A diagnosis of probable extensive pelvic carcinoma was made, and exploratory operation was advised.

Upon exploration a fibroma of the ovary with a twisted pedicle was found. The tumor which was undergoing necrosis was fixed to the pelvic peritoneum by rather firm adhesions and was so wedged into the pelvis that it was difficult to mobilize.

Following removal of the tumor the patient had an uneventful convalescence and has had no further difficulty. The tumor was described histologically as a fibroma and weighed 560 grams.

Group 3. In the third category are those patients who develop ascites as a result of fibromas of the ovary. This syndrome was first reported by Meigs<sup>1</sup>, and in several of his cases he observed not only ascites but also hydrothorax. In only two cases in our series was ascites noted, and hydrothorax did not occur.

As a general rule, ascites associated with a hard pelvic tumor indicates the presence of advanced carcinoma with implantation on the peritoneal surfaces. Therefore, it is particularly gratifying to find that the ascites in these cases is caused by a benign and curable condition, and that following the removal of the fibroma, does not recur. The exact cause of the ascites is not known, but it is possible that some circulatory disturbance increases the venous pressure in the tumor with a resultant filtration of serum from the serous surfaces. The following case is illustrative of ascites from a fibroma of the ovary.

*Case 3.* A woman, aged 56, complained of a burning pain in the right costal margin of fifteen years' duration, and of constipation of six months' duration. In addition, she had noticed that her abdomen was increasing in size.

On abdominal examination a large, very hard, movable tumor was found which apparently arose from the pelvis. Ascites was present as indicated by shifting dullness and the examiner's ability to ballotte the tumor. A preoperative diagnosis of fibroma of the ovary was made.

At operation a tumor weighing 1,770 grams was removed which was described histologically as a fibroma. The patient had an uneventful convalescence and has had no difficulty since operation.

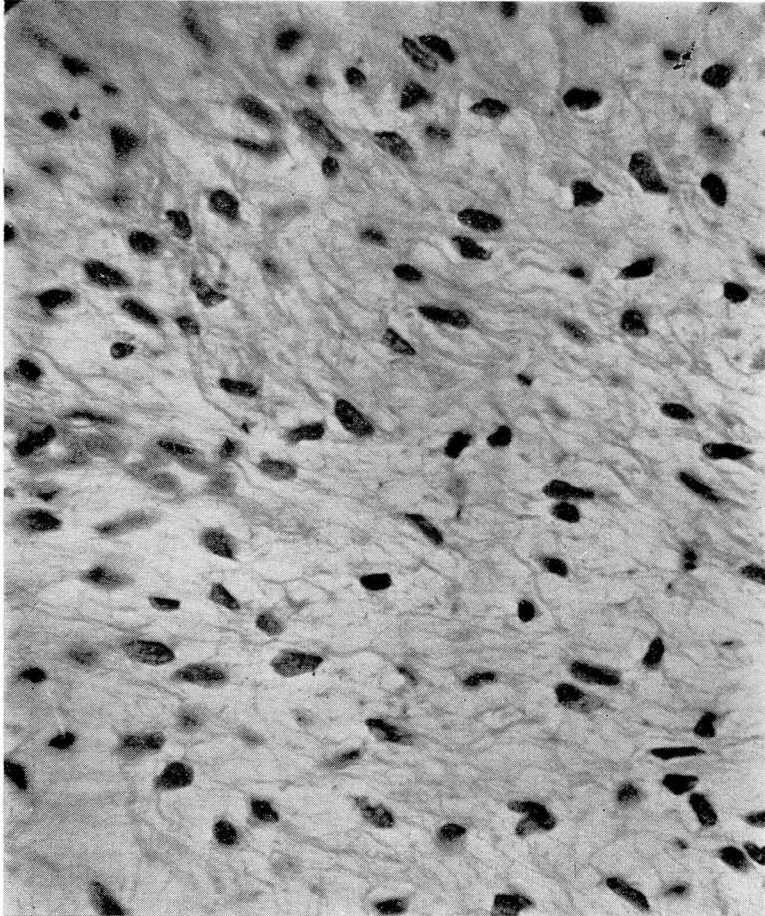


FIGURE 1. Photomicrogram showing histology of a fibroma of the ovary in Case 3.

The clinical and pathologic features of fibroma of the ovary are hard to reconcile. These tumors behave clinically like carcinomas in that they occur in the aged and grow rapidly, yet histologically they seem to be perfectly benign and, in our experience, neither recur nor

metastasize. Some writers<sup>2</sup> raise the question as to whether many of these "fibromas" are not really benign tumors of epithelial origin. I am not qualified to discuss the pathologic aspects of this question except to say that the tumors in our series contained no epithelial elements demonstrable by ordinary staining methods. On the other hand, the rapid growth and the age incidence of fibromas of the ovary could be better explained if they could be demonstrated to be of epithelial origin.

Regardless of the true nature of fibromas of the ovary, it is important to remember that on exploration an apparently advanced and incurable malignancy of the pelvic organs may prove to be a benign and curable tumor of the ovary. In the presence of ascites or fixed pelvic masses of undetermined origin, or of the sudden development of a rapidly enlarging abdominal tumor in an elderly woman, the possibility of a fibroma of the ovary must be considered.

#### SUMMARY

1. Fibromas of the ovary characteristically occur in elderly women.
2. Fibromas of the ovary may enlarge so rapidly that the presence of a malignant tumor may be suspected.
3. Fibromas of the ovary may produce ascites and accordingly suggest the presence of malignancy.
4. Fibromas of the ovary may become twisted on their pedicles and form a hard fixed mass in the pelvis which simulates extensive metastasis from a carcinoma.
5. Fibromas of the ovary are easily removed and do not recur.

#### REFERENCES

1. Meigs, J. V.: Fibroma of ovary with ascites and hydrothorax; further report. *Ann. Surg.*, 110:731-754, (October) 1939.
2. Dockerty, M. B.: Brenner's tumor of ovary. *Proc. Staff. Meet. Mayo Clin.*, 15:229-233, (April 10) 1940.