

**Justin R. Abbateamarco, MD**Mellen Center for Multiple Sclerosis,  
Cleveland Clinic, Cleveland, OH**Chen Yan, MD**Mellen Center for Multiple Sclerosis,  
Cleveland Clinic, Cleveland, OH**Amy Kunchok, MBBS**Mellen Center for Multiple Sclerosis,  
Cleveland Clinic, Cleveland, OH**Alexander Rae-Grant, MD, FAAN, FRCPC**Mellen Center for Multiple Sclerosis, Cleveland Clinic,  
Cleveland, OH

# Antibody-mediated autoimmune encephalitis: A practical approach

## ABSTRACT

Antibody-mediated autoimmune encephalitis (AE) is a heterogeneous group of inflammatory central nervous system disorders. Symptoms typically include subacute, progressive neuropsychiatric symptoms with associated cognitive dysfunction, movement disorders, and autoimmune seizures. The diagnosis should be based on objective neurologic dysfunction in combination with autoantibody testing. Treatment with immunotherapies requires both short-term and long-term strategies depending on the specific syndrome and potential for relapse. In this paper, we review key features of AE, focusing on syndromes involving cell surface and synaptic proteins, and share a practical approach to the diagnosis and management, including common pitfalls associated with nonspecific antibody findings.

## KEY POINTS

AE is an umbrella term for a group of inflammatory central nervous system disorders associated with neuronal autoantibodies or other biomarkers of central nervous system autoimmunity.

Common clinical presentations include progressive neurocognitive symptoms with concomitant movement disorders, seizures, and autonomic dysfunction that worsens over weeks to months.

Objective clinical findings are needed to make the diagnosis of AE, including changes on magnetic resonance imaging, electroencephalography, and cerebrospinal fluid analysis.

THE SPECTRUM AND UNDERSTANDING OF antibody-mediated autoimmune encephalitis (AE)—an umbrella term for a group of noninfectious, inflammatory central nervous system diseases—have expanded dramatically over the past few years. Familiarity with AE syndromes ensures prompt diagnosis and treatment. Practitioners need to stay abreast of developments in this field as the breadth of immune-mediated disorders of the nervous system continues to evolve.

In this paper, we will focus on the clinical features of common central nervous system cell surface and synaptic antibody syndromes in adults and on the emerging evidence in this area that has led to rapid changes in management and treatment over the past decade. We will also briefly comment on antibody-negative AE.

Antibody-related syndromes such as intracellular neuronal antibody-associated encephalitis and encephalitis occurring with demyelinating disorders are less commonly encountered in clinical practice and are beyond the scope of this article.

## ■ GENERAL FEATURES OF AUTOIMMUNE ENCEPHALITIS

Potential associations of AE encompass paraneoplastic, parainfectious triggers along with adverse events related to various immunotherapies.<sup>1–3</sup>

Onset of AE is usually subacute over weeks to months, with progressive neurocognitive symptoms including encephalopathy, cognitive dysfunction, neuropsychiatric symptoms, and seizures. Other features may include brainstem syndromes, dysautonomia, and movement disorders.

doi:10.3949/ccjm.88a.20122

The prevalence and incidence are increasing as testing becomes more widely available. A recent study in Olmsted County, MN, showed a prevalence of AE of 13.7 per 100,000, similar to that of infectious encephalitis.<sup>4</sup>

## ■ HOW IS AUTOIMMUNE ENCEPHALITIS CLASSIFIED?

Over the past few decades, there has been rapid growth in the discovery of antibody-associated neurologic diseases. Autoantibodies that target neuronal antigens can cause a diverse set of neurologic disorders. This has significantly raised awareness of the wide spectrum of disease presentations that may have an underlying autoimmune component.

Antibodies associated with AE are commonly divided into 2 groups depending on the location of the antigen. The traditional “well-defined” syndromes (eg, anti-Hu or ANNA-1, anti-Ri or ANNA-2) target intracellular neuronal antigens.<sup>5</sup> And more recently, a new group of neuronal cell surface/synaptic proteins has been described in association with AE. This distinction is important for diagnosis and prognosis. Intracellular antibody-mediated syndromes appear to be driven primarily by a CD8+ T-cell cytotoxic response and usually have a poorer prognosis, with a limited response to immunotherapy (Table 1). In contrast, cell surface/synaptic antibodies appear to be directly pathogenic and are more responsive to multimodal immunotherapies (Table 2).<sup>1,5</sup> Detailed discussions of the pathophysiology of AE have been published by Bradshaw and Linnoila<sup>6</sup> and by McKeon.<sup>7</sup>

Though the terms paraneoplastic syndrome and AE are sometimes used interchangeably, not all AE syndromes are paraneoplastic. Paraneoplastic syndromes are defined as neurologic syndromes occurring in the setting of cancer, sometimes preceding the diagnosis of neoplasm by months or years.<sup>1</sup> Paraneoplastic disorders are usually related to intracellular neuronal antibodies. Cell surface/synaptic antibody-mediated syndromes, however, may also be associated with cancer, though they are usually classified as phenotypes of low to moderate risk, as these disorders can occur with or without cancer. The strength of association with an underlying neoplasm varies depend-

ing on the specific antibody or antibodies.<sup>5</sup>

## ■ WHEN SHOULD I CONSIDER THE DIAGNOSIS?

AE may be considered in patients presenting with subacute onset (over 1 to 3 months) of cognitive or memory deficits, alterations in consciousness, seizures, movement disorders, or other neuropsychiatric symptoms.<sup>8</sup> Accompanying neurologic or systemic symptoms suggestive of a specific antibody-mediated syndrome can increase clinical suspicion for AE. Examples include the following:

- Dystonia-chorea for anti-*N*-methyl-D-aspartate (anti-NMDA) receptor encephalitis
- Hyperkplexia (exaggerated startle reflex) for anti-glycine receptor (Gly-R) antibody syndrome
- Faciobrachial dystonic seizure (focal or lateralized coordinated contractions of an arm and the face) for anti-leucine-rich glioma-inactivated protein 1 (LG11) encephalitis
- Peripheral nerve hyperexcitability (diffuse involuntary motor-unit activity due to hyperexcitability of the motor nerve or its terminal)<sup>9</sup> for anti-contactin-associated protein-like 2 (Caspr2) syndrome
- Weight loss accompanying gastrointestinal symptoms for anti-dipeptidyl-peptidase-like protein 6 (DPPX) encephalitis.<sup>5,10</sup>

While certain autoantibody disorders have a specific phenotype, a number of patients with AE do not present with classic “limbic encephalitis” and can present with a range of central nervous system and peripheral nervous system involvement.<sup>11</sup> Table 3 provides a list of potential clinical and radiographic findings suggestive of AE.

It is also important to recognize that AE can be antibody-negative. Antibody-negative AE may occur due to limitations of currently available testing, especially as novel autoantibodies are being discovered. However, objective clinical and radiologic criteria exist to aid diagnosis.<sup>8</sup>

Despite the challenges, the diagnosis of AE should be driven by the patient’s clinical presentation and diagnostic evaluation. This approach includes a detailed clinical history

**A 2018 study found the prevalence of autoimmune encephalitis was similar to that of infectious encephalitis**

TABLE 1

### Autoantibody biomarkers of autoimmune encephalitis: Intracellular autoantibodies

ANTIBODY TARGET	CENTRAL NERVOUS SYSTEM FEATURES	PERIPHERAL NERVOUS SYSTEM FEATURES	OTHER	ASSOCIATED MALIGNANCY
<b>High-risk paraneoplastic autoantibodies</b>				
ANNA-1 (Hu)	Limbic encephalitis Encephalomyelitis Cerebellar ataxia	Sensory neuropathy	Gastrointestinal dysmotility	SCLC Rare: neuroblastoma
ANNA-2 (Ri)	Encephalomyelitis Cerebellar ataxia Rhombencephalitis		Jaw dystonia Laryngospasm	SCLC Breast carcinoma
ANNA-3	Limbic encephalitis Encephalomyelitis Cerebellar degeneration	Sensory and sensori-motor neuropathies		SCLC
Amphiphysin	Stiff-person spectrum disorder			SCLC Breast or ovarian carcinoma
CRMP-5	Limbic encephalitis Cerebellar ataxia Chorea Myelopathy Cranial neuropathies (optic neuritis)	Polyradiculo-neuropathy		SCLC Thymoma carcinoma
GAD65	Stiff-person spectrum disorder Limbic encephalitis Cerebellar ataxia			Rare
GFAP	Meningoencephalitis Myelitis Optic neuritis			Ovarian teratoma Adenocarcinomas of various sites
PCA-1 (Yo)	Cerebellar ataxia			Breast or ovarian carcinoma
PCA-2	Limbic encephalitis Cerebellar ataxia	Polyneuropathy		SCLC
PCA-Tr (DNER)	Limbic encephalitis Cerebellar ataxia			Hodgkin lymphoma
Ma 1 and Ma 2 (Ta)	Diencephalitis Limbic encephalitis Brain stem encephalitis Cerebellar degeneration			Ma1: Common, diverse Ma2: Testicular seminoma

ANNA = antineuronal nuclear antibody; CRMP-5 = collapsin response mediator protein 5; DNER = delta/notch-like epidermal growth factor-related receptor; GAD = glutamic acid decarboxylase; GFAP = glial fibrillary acidic protein; PCA = Purkinje cell cytoplasmic antibody; SCLC = small-cell lung cancer

**Negative antibody testing does not rule out autoimmune encephalitis**

**TABLE 2**

**Autoantibody biomarkers of autoimmune encephalitis:  
Cell-surface and synaptic antibodies**

ANTIBODY	CENTRAL NERVOUS SYSTEM FEATURES	PERIPHERAL NERVOUS SYSTEM FEATURES	OTHER FEATURES	ASSOCIATED MALIGNANCY
AMPA	Limbic encephalitis			SCLC Breast carcinoma Thymoma
Caspr2	Limbic encephalitis	Peripheral nerve hyperexcitability		Rare, but thymoma carcinoma reported
DPPX	Encephalopathy Myelopathy		GI dysmotility Sleep disorder	Rare, but lymphoma reported
D2R	Parkinsonism Encephalitis			
GABA A receptor	Encephalitis Status epilepticus			Thymoma
GABA B receptor	Limbic encephalitis Status epilepticus Opsoclonus myoclonus			SCLC
GQ1b	Bickerstaff brain stem encephalitis	Guillain-Barré-like illness		
IgLON5	Sleep disorder Dementia		Dysphagia Respiratory failure	Rare
LGI1	Limbic encephalitis Faciobrachial dystonic seizures			Thymoma
NMDA-R	Limbic encephalitis Status epilepticus Movement disorders Psychosis Catatonia			Ovarian teratoma
mGluR1	Cerebellar ataxia		Dysgeusia	Hodgkin lymphoma
mGluR5	Limbic encephalitis			Hodgkin lymphoma
Glycine receptor	Stiff-person spectrum disorder			Rare

AMPA = 2-amino-3-(5-methyl-3-oxo-1,2-oxazol-4-yl) propanoic acid receptor; Caspr2 = contactin-associated protein-like 2; D2R = dopamine 2 receptor; DPPX = dipeptidyl-peptidase-like protein 6; GABA = gamma-aminobutyric acid; GI = gastrointestinal; LGI1 = leucine-rich glioma-inactivated 1; mGluR = metabotropic glutamate receptor; NMDA-R = anti-N-methyl-D-aspartate receptor; SCLC = small cell lung cancer

**Ruling out an infectious process is important, given that immunotherapies can worsen infection**

including a personal or family history of autoimmunity, identifying infectious risk factors (ie, exposure and travel history) while excluding other conditions in the differential diagnosis.<sup>8</sup> It should also be noted that a patient

with AE may not exhibit all the disease characteristics discussed below. For example, normal findings on magnetic resonance imaging (MRI) and electroencephalography (EEG) are not uncommon in anti-LGI1 encephalitis.<sup>12</sup>

TABLE 3

**Clinical, diagnostic, and radiographic clues to autoimmune encephalitis**

FINDINGS	COMMENTS
Subacute clinical course	1–3 months of symptoms
Viral-like prodrome	Fever, malaise, headache, gastrointestinal symptoms, etc
Neurocognitive deficits	Agitation, apathy, catatonia, delusions, irritability, mania, psychosis, and paranoia
Neurologic examination abnormalities	Ataxia, brain stem abnormalities, myoclonus, tremor, or myelopathy
New-onset focal seizure disorder or status epilepticus	Often not responsive to antiepileptic medications
New focal electroencephalogram abnormalities	Focal epileptic or slow-wave activity particularly arising from the temporal lobes
Subacute movement disorder	Dyskinesias, dystonia, or choreoathetosis
Subacute sleep disturbance	Central sleep apnea, central neurogenic hypoventilation, or narcolepsy
Subacute autonomic dysfunction	Hyperhidrosis, tachyarrhythmias, labile blood pressure, central hypoventilation, gastrointestinal dysmotility, urinary dysfunction
Brain MRI abnormalities	Bilateral T2-weighted FLAIR hyperintensities in the medial aspect of the temporal lobes, although multifocal changes involving the gray and white matter are also possible
Inflammatory cerebrospinal fluid	Mild to moderate pleocytosis (white blood cell count 5–100/μL)
Previous or current oncologic disorder or risk factors for malignancy such as smoking	Increased risk of a paraneoplastic disorder

FLAIR = fluid-attenuated inversion recovery; MRI = magnetic resonance imaging

### ■ WHAT ARE THE COMMON CELL-SURFACE/ SYNAPTIC ANTIBODY SYNDROMES IN AUTOIMMUNE ENCEPHALITIS?

#### Anti-NMDA receptor encephalitis

Anti-NMDA receptor encephalitis was initially characterized in 12 women showing a characteristic progression of psychiatric symptoms ranging from subtle behavioral changes, such as irritability, to frank psychosis. These symptoms were followed by movement disorders, autonomic dysfunction, hypoventilation, seizures, and coma.<sup>13</sup> Anti-NMDA is one of the most frequently identified neuronal autoantibodies in AE.<sup>1</sup> Anti-NMDA receptor encephalitis frequently affects young adults, with a strong female predominance (4:1), though it has been described in all ages including children and the elderly, with variable phenotypes.<sup>14</sup> The median age is 20.

**Viral-like prodrome.** Some patients experience a viral-like prodrome that includes headache or fever during the initial 1 to 2

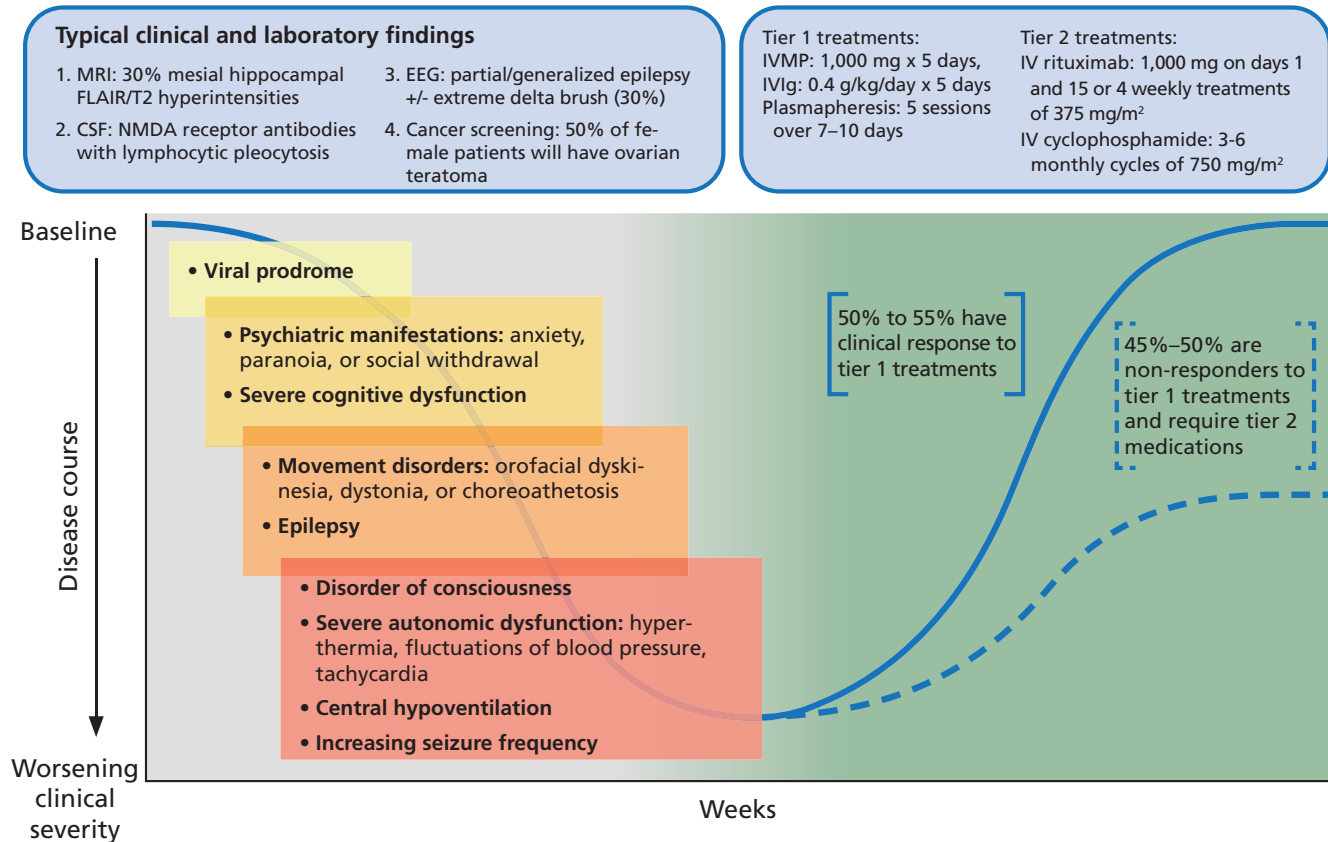
weeks of the illness (**Figure 1**). Soon after, subacute psychiatric symptoms develop including anxiety, personality changes, hallucinations, paranoid ideas, and frank psychosis. It is not unusual for patients to alternate between hyperactive and catatonic states. Concomitant movement disorders such as dyskinesia (typically orofacial or limb), dystonia, and choreoathetosis are common. From 60% to 75% of adult patients have been reported to experience behavioral problems or movement disorders during the first month of the disorder.<sup>15</sup>

**Autonomic dysfunction.** As the disease progresses, autonomic dysfunction becomes more prominent and commonly necessitates monitoring in an intensive care unit.

**Potential complications** include tachyarrhythmias, hypotension, and central hypoventilation requiring mechanical ventilation. Approximately 80% of patients require ICU admission.<sup>15</sup>

**Seizures** can occur at any time and are

## NMDA receptor encephalitis: Typical clinical course



**Figure 1.** Typical clinical course associated with anti-NMDA receptor encephalitis.

CSF = cerebrospinal fluid; EEG = electroencephalography; FLAIR = fluid-attenuated inversion recovery; IV = intravenous; IVIg = intravenous immunoglobulin; IVMP = intravenous methylprednisolone; MRI = magnetic resonance imaging; NMDA = anti-*N*-methyl-D-aspartate receptor

Based on information in reference 15.

often not responsive to antiepileptic medications alone. In a case series of 75 patients with anti-NMDA receptor encephalitis, almost 80% suffered from generalized tonic-clonic seizures, and 74% had focal seizures without impaired awareness.<sup>16</sup> There has been some evidence to suggest antiepileptic drugs with sodium channel-blocking properties (eg, carbamazepine, oxcarbazepine, lacosamide, phenytoin) may be more effective, though seizure freedom is usually achieved only when paired with immunotherapies.<sup>16,17</sup>

**NMDA receptor immunoglobulin G (IgG)** testing should always be done with cerebrospinal fluid (CSF), as serum testing is less reliable (100% sensitivity for CSF vs 85% for serum).<sup>15</sup> CSF analysis usually reveals a moderate lymphocytic pleocytosis, elevated pro-

tein, and intrathecal antibody production.

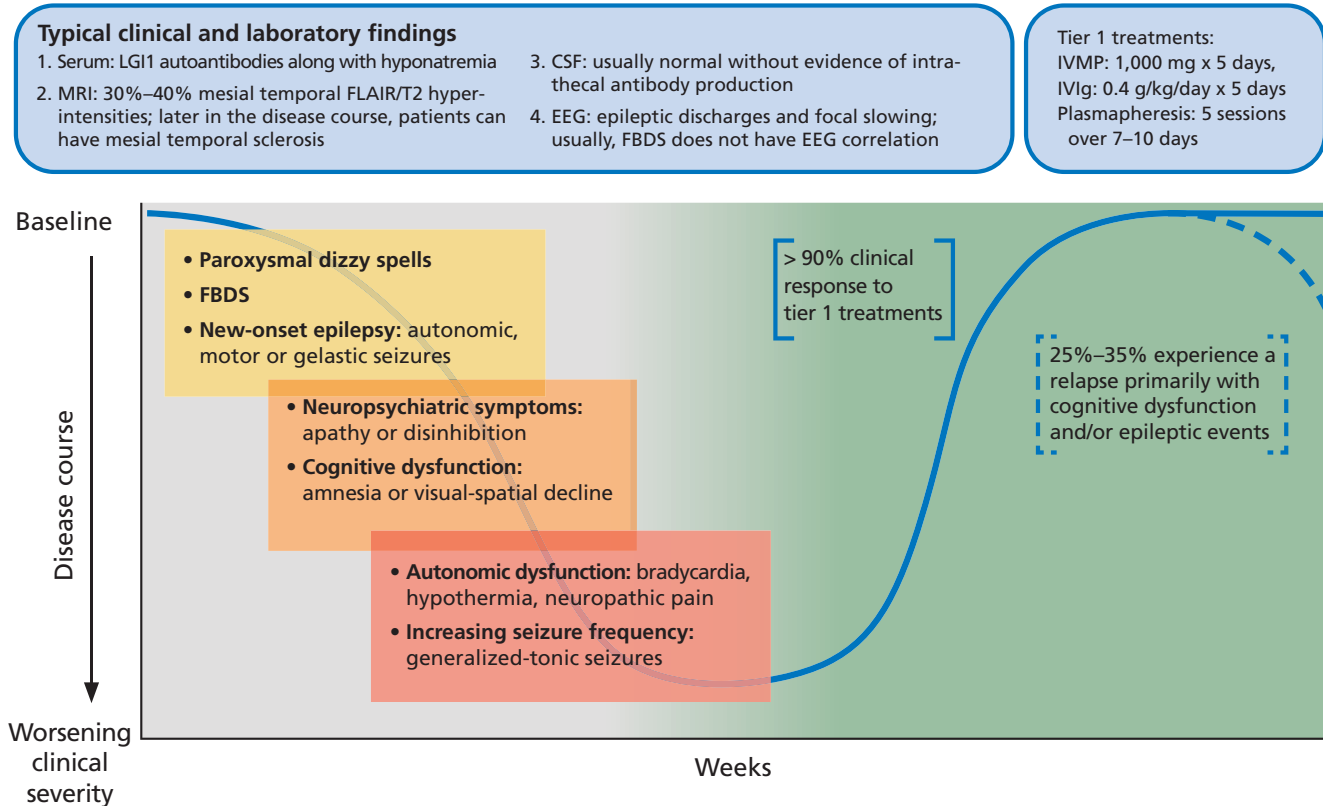
**Patterns on EEG** can vary and often simply demonstrate slowing.<sup>11</sup> Approximately one-third of patients develop extreme delta brush; this is described as slowing with delta activity 1–3 Hz and superimposed bursts of rhythmic activity (beta activity 20–30 Hz) on these slow waves and may be a poor prognostic sign.<sup>18</sup>

**MRI findings.** MRI is usually normal but may show subtle mesial hippocampal fluid-attenuated inversion recovery (FLAIR) hyperintensities. Titulaer et al reported that 76% of patients had a CSF pleocytosis, one-third of the cohort had an abnormal brain MRI, and 90% had changes on EEG including slowing.<sup>15</sup>

**Teratomas.** Anti-NMDA receptor encephalitis may be associated with ovarian



## LGI1 encephalitis: Typical clinical course



**Figure 2.** Typical clinical course associated with anti-LGI1 encephalitis.

CSF = cerebrospinal fluid; EEG = electroencephalography; FBDS = faciobrachial dystonic seizures; FLAIR = fluid-attenuated inversion recovery; IVIg = intravenous immunoglobulin; IVMP = intravenous methylprednisolone; LGI1 = leucine-rich glioma-inactivated 1; MRI = magnetic resonance imaging

or extraovarian teratomas in 30% to 40% of patients, particularly in young women. It requires prompt surgical treatment.<sup>15</sup>

**Infection.** Herpes simplex virus infection of the central nervous system can also trigger the production of NMDA receptor IgG.<sup>19</sup> In a large prospective study, 27% of patients with herpes simplex encephalitis developed anti-NMDA receptor antibodies within 16 weeks of completing their acyclovir treatment.<sup>19</sup> None of the patients had NMDA receptor IgG at the index admission. Interestingly, 3 patients (6%) developed CSF NMDA receptor IgG without clinical correlation, but the antibody production was not detectable at 1-year follow-up.<sup>19</sup> There have been reports of pediatric anti-NMDA receptor encephalitis developing after Japanese encephalitis infection, but no other clear postinfectious or vaccination pattern has

emerged in the literature.<sup>20,21</sup>

**Immunotherapy.** Anti-NMDA receptor encephalitis responds to immunotherapy, but the response can be slow. In the largest study to date of patients with anti-NMDA receptor encephalitis, 81% had significant recovery at 24 months, but only 53% had clinical improvement within 4 weeks of diagnosis.<sup>15</sup>

From 10% to 25% of patients have a clinical relapse, though symptoms are less severe than in the initial presentation.<sup>1,22</sup>

Maintenance immunotherapy can be used to optimize acute treatment response while preventing relapses.<sup>15</sup> Commonly used agents include oral corticosteroids, intravenous immunoglobulin (IVIg), and steroid-sparing agents such as mycophenolate mofetil, azathioprine, rituximab, and cyclophosphamide.<sup>23</sup>

## Anti-LGI1 encephalitis

Anti-LGI1 encephalitis was first characterized in 2010.<sup>24</sup> In contrast to anti-NMDA receptor encephalitis, it typically occurs in men over age 60, presenting with subacute cognitive dysfunction and behavioral changes.

About 50% of patients also develop faciobrachial dystonic seizures characterized by focal or lateralized rapid coordinated movements of an arm or the face that may occur hundreds of times a day. These dystonic seizures are very specific for anti-LGI1 encephalitis but are not universally present. Most patients will have normal surface activity on EEG even if the faciobrachial seizure events are captured during the recording. The exact reason for this is unclear, but it may reflect subcortical seizure origin, as some of these patients have contralateral basal ganglia lesions on MRI.<sup>25</sup>

**Other associated seizure subtypes** include subtle autonomic focal seizures and generalized tonic-clonic seizures (**Figure 2**).<sup>12</sup> Autonomic hyperactivity has also been reported. This includes hyperhidrosis, tachycardia, blood pressure lability, and urinary dysfunction.<sup>26</sup>

**The initial workup** for anti-LGI1 encephalitis includes MRI, EEG, and CSF analysis but is usually unrevealing aside from a mild hyponatremia on basic metabolic testing. CSF-specific oligoclonal bands may be seen, but CSF can also be non-inflammatory. Initial brain MRI can occasionally demonstrate T2-FLAIR hyperintensity of the hippocampus.<sup>27</sup> Unlike in anti-NMDA receptor encephalitis, CSF is less sensitive than serum for the detection of LGI1 antibodies (serum 100% vs CSF about 88%).<sup>27,28</sup>

**Treatment response.** This syndrome characteristically responds briskly to tier 1 treatments (corticosteroids, intravenous immunoglobulin, plasmapheresis), but 20% to 30% of patients may experience a relapse necessitating long-term immunosuppression.<sup>22</sup> In one small randomized control trial, IVIg treatment was associated with a significant reduction in seizure burden and can be considered a steroid-sparing agent.<sup>29</sup>

**Malignancy.** From 5% to 15% of patients have an underlying malignancy, most commonly thymoma.<sup>30</sup> Patients may have residual cognitive deficits despite initial recovery.

## WHAT TESTING SHOULD I CONSIDER FOR AE DIAGNOSIS?

When AE is highly suspected (**Table 3**), initial testing should include an antibody panel. Both serum and CSF should be tested for antibodies since CSF is more sensitive and specific for certain antibodies such as NMDA receptor IgG, GAD65 IgG, and GFAP IgG, whereas serum is more sensitive for other antibodies such as LGI1 IgG and Caspr2 IgG.

Antibody panels are preferred over specific antibody tests, given the often overlapping clinical syndromes and the possibility of multiple positive antibodies.

Common testing sites include Mayo Clinic or Associated Regional and University Pathologists (ARUP) laboratory. Antibody panels include:

- Mayo ENS-2 panel in serum ([www.mayocliniclabs.com/test-catalog/Overview/92116](http://www.mayocliniclabs.com/test-catalog/Overview/92116))
- Mayo ENC-2 panel in CSF ([www.mayocliniclabs.com/test-catalog/Overview/92117](http://www.mayocliniclabs.com/test-catalog/Overview/92117))
- ARUP Autoimmune Encephalitis Extended Panel in serum (<https://ltd.aruplab.com/Tests/Pub/3001431>).

## Encephalitis has a broad differential diagnosis

The differential diagnosis for encephalitis is very broad and includes infections, toxic-metabolic encephalopathy, mitochondrial disorders, nutritional deficiencies, vascular disorders, malignancy, and demyelinating disorders. Clinicians should be particularly concerned about ruling out an infectious process given the immunotherapies utilized to treat AE. Infections to consider include herpes simplex virus encephalitis, human herpesvirus 6, human immunodeficiency virus, fungal infection (eg, cryptococcal), mycobacterial infection, Whipple disease, and neurosyphilis.

In general, viral infections usually cause a more profound CSF pleocytosis (a white blood cell count of 50–100/ $\mu$ L). Bacterial or mycobacterial infections can have a lower of CSF glucose concentration, whereas AE usually has normal glucose levels.<sup>31</sup>

Overall, careful examination usually reveals subtle neurologic deficits that should prompt further evaluation for AE. Diagnos-

**Viral infections usually cause a more profound CSF pleocytosis**



tic red flags include newly occurring epileptic seizures, movement disorders, and neurocognitive symptoms, especially in the setting of MRI or CSF abnormalities.

It should be mentioned that the prevalence of primary psychiatric disorders is much higher than the prevalence of AE. For example, the overall prevalence of schizophrenia, with incidence peaking in young adults, is estimated to be 2.7 to 8.3 per 1,000,<sup>32</sup> whereas the overall prevalence of AE is 13.7 per 100,000.<sup>4</sup> Thus, in a young patient with new mood disorder, a primary psychiatric diagnosis remains more likely than AE.

While patients with a preexisting psychiatric disorder can develop a concomitant autoimmune condition, it should also be mentioned that a specific isolated psychiatric AE phenotype has not emerged in the literature despite extensive investigations.<sup>21</sup>

## ■ A COMPREHENSIVE EVALUATION FOR AUTOIMMUNE ENCEPHALITIS

A comprehensive evaluation for suspected AE includes a range of laboratory studies and imaging.

### Serum testing

Serum testing with an AE antibody panel to human immunodeficiency virus, thyroid-stimulating hormone, vitamin deficiency (B<sub>1</sub>, B<sub>12</sub>, E, folic acid).

### Evaluation for other disease markers

Patients with autoimmune encephalitis are at increased risk of having a second autoimmune disorder. Choice of any specific testing should be based on clinical suspicion.<sup>7,33</sup>

### Cerebrospinal fluid testing

CSF studies include an AE antibody panel, routine studies, CSF IgG index, CSF-specific oligoclonal bands, and comprehensive infectious evaluations with specific attention to viral agents (ie, herpes simplex virus type 1, varicella-zoster virus, West Nile virus, John Cunningham virus, and human herpesvirus 6).

### Urine toxicology screen

A urine toxicology test should include screening for marijuana and cocaine.

### Magnetic resonance imaging

MRI of the brain with and without gadolinium contrast is appropriate. Consider completing an epilepsy protocol, which may vary between institutions but usually consists of standard T1- and T2-weighted images, FLAIR, gradient-echo (T2) sequences, and diffusion-weighted sequences. Imaging sequences should also include contiguous, thin slices to ensure that hippocampal and temporal lobe lesions can be identified.<sup>34</sup>

Consider spinal cord MRI if neurologic abnormalities suggest concomitant myelitis. Symptoms could encompass motor, sensory, and autonomic (bladder, bowel, sexual) dysfunction that localizes to the spinal cord. An example could be a well-defined truncal sensory level below which the sensation is altered.<sup>35</sup>

### Electroencephalographic monitoring

Continuous monitoring with EEG can clarify the cause of motor symptoms, identify suggestive patterns such as extreme delta brush, and characterize seizure burden.

### Positron emission tomography

Brain fluorodeoxyglucose-positron emission tomography with computed tomography (FDG-PET/CT) may illustrate either hypometabolism that may correlate with impairment of neuronal activity even in the absence of structural disturbance<sup>36</sup> or hypermetabolism that could correlate with increased glucose metabolism caused by synaptic dysfunction or ongoing seizure activity.<sup>37</sup> Overall, PET may be a sensitive marker for AE but is limited by its higher cost, lack of diagnostic specificity and clinical availability.<sup>36</sup>

Body FDG-PET/CT can be done to screen for malignancy.<sup>38</sup>

## ■ WHICH AUTOANTIBODY FINDINGS SHOULD BE INTERPRETED CAUTIOUSLY?

The development of broad antibody panels has led to some unintended consequences, particularly as these panels may include disorders of the central nervous system and the peripheral nervous system.<sup>39</sup> In addition, the specificity and sensitivity can vary for the different autoantibodies and the association with AE. Therefore, interpretation of autoantibody

**Paraneoplastic syndromes sometimes precede a cancer diagnosis by months or years**

testing should be combined with a comprehensive clinical evaluation as outlined above in the section “A comprehensive evaluation for autoimmune encephalitis.”<sup>8</sup>

Caution is particularly needed when interpreting tests for autoantibodies that have low specificity for AE. For example, anti-voltage-gated potassium channel (VGKC) antibodies were initially detected in peripheral nerve hyperexcitability disorders such as neuromyotonia and Morvan syndrome. Further laboratory evaluation has elucidated that LGI1 and Caspr2 are the usual targets of these complex antibodies and not the VGKC itself. VGKC antibodies alone are not specific for AE and can be seen in 5% of healthy controls.<sup>40</sup> In VGKC-positive patients without LGI1 and Caspr2 antibodies, additional testing is not usually warranted, as there is no clear evidence that VGKC titers are indicative of an autoimmune disorder.<sup>30</sup>

Hashimoto encephalopathy, also known as steroid-responsive encephalopathy associated with autoimmune thyroiditis, has been historically linked to elevated serum levels of thyroid peroxidase antibodies.<sup>41</sup> In the era of more neuronal-specific antibodies, thyroid peroxidase antibodies have been found to have limited diagnostic value. An extensive evaluation to exclude other causes of AE should be pursued in cases with elevated thyroid peroxidase antibody titers, given the unclear clinical significance of these antibodies in neurologic disorders.<sup>42,43</sup>

## ■ WHAT IS THE INITIAL TREATMENT FOR AUTOIMMUNE ENCEPHALITIS?

Current treatment guidelines for AE are based on a combination of expert opinion, case series, and case reports, and evidence from high-quality multicenter randomized trials is lacking.<sup>29</sup> But existing evidence suggests that early initiation of therapy and prompt escalation to second-line immunotherapy may lead to improved clinical outcomes.<sup>15,22</sup>

Still, unanswered questions include the time frame associated with a response to the first-line immunotherapy and the optimal duration of sustained immunotherapy. A comprehensive evaluation for malignancy is also vital as early detection and treatment are im-

portant for improved patient outcomes.

An important caveat for all clinicians is that although response to corticosteroid therapy is a typical feature of AE, it does not confirm the diagnosis of AE. Disorders such as lymphoma and vasogenic edema associated with a brain tumor can also respond dramatically to steroids. Additionally, some AE patients do not respond to corticosteroids but require prolonged treatment with other immunotherapies.<sup>8</sup>

Initiation and escalation of treatment depend on the pretest probability of AE along with the clinical severity. If there is a high pretest probability of a known syndrome, waiting for the results of antibody testing should not delay treatment. For example, a case of refractory autoimmune-mediated status epilepticus in the intensive care unit requires prompt and aggressive treatment. Caution should be used when the diagnosis is less certain.<sup>8</sup>

## First-line treatments

First-line treatment for AE involves corticosteroids combined with either IVIg or plasmapheresis.<sup>22,44</sup>

- Methylprednisolone 1 g daily for 5 days, followed by oral prednisone 1 mg/kg (maximum dose 60–80 mg daily, with a prolonged taper over 3–6 months)
- IVIg 400 mg/kg/day for 5 days
- Plasmapheresis, with 5 exchanges over 7 to 8 days.

## Second-line treatments

Second-line treatments can be given as monotherapy or in combination for refractory disease activity 1 to 2 weeks from completion of first-line treatment.<sup>22</sup>

- Rituximab 1,000 mg IV, with a repeat dose in 2 weeks, or 375 mg/m<sup>2</sup> weekly IV infusion for 4 weeks
- Cyclophosphamide 750 mg/m<sup>2</sup> IV monthly for 3 to 6 months.

## Maintenance treatments<sup>45</sup>

- Rituximab, repeat every 6 months, same dosing schedule as second-line therapy
- IVIg 0.4 g/kg every 2 to 4 weeks
- Mycophenolate mofetil 500 to 3,000 mg/day
- Azathioprine 1 to 3 mg/kg/day
- Cyclophosphamide 1 to 2 mg/kg/day orally.

## ■ HOW DO I MONITOR RESPONSE TO TREATMENT IN AE?

There are no validated biological markers to assess treatment response in AE. Although some studies have suggested that early reduction in titers can correlate with better clinical outcomes, antibodies can remain positive even in patients with good outcomes.<sup>46</sup> Further, the change in antibody titers does not consistently correlate with risk of relapse.<sup>47</sup> Therefore, serum or CSF antibody titers in isolation are not reliable for monitoring treatment response in AE.

Imaging, when abnormal, can be repeated to look for improvements over time. Unfortunately, even after appropriate treatment is initiated for AE, brain MRI may show irreversible changes such as generalized or focal atrophy on follow-up.

Monitoring of the treatment response is therefore primarily based on the clinical examination. We urge clinicians to use objective measures to determine the true efficacy of a given treatment. For example, clinicians can use the Scale for the Assessment and Rating of Ataxia (SARA),<sup>48</sup> Symbol Digit Modalities Test, or the Montreal Cognitive Assessment (MoCA)<sup>49</sup> for reliable scores to measure the success of a trial and the utility of long-term treatments. Formal neuropsychological testing is also a valuable tool to document the extent of cognitive damage and to evaluate immunotherapy response.

## ■ WHAT ONCOLOGIC EVALUATION IS APPROPRIATE FOR PATIENTS WITH AE?

Paraneoplastic AE can occur in association with an underlying malignancy. In particular, small-cell lung cancer, non-small-cell lung cancer, and neuroblastoma trigger the production of paraneoplastic autoantibodies.<sup>50</sup> The neurologic sequelae can occur prior to detection of the cancer allowing for early discovery and oncologic treatment.

Though treating the cancer is the main goal in these patients, they may still require short-term or long-term immunotherapy for the paraneoplastic disorder. Immunotherapies that may have dual benefit to treat the cancer and autoimmune disorder, such as cyclophosphamide, can be considered.

All treatment decisions must be made in coordination with the treating oncologist.<sup>6</sup> Additionally, patients may have permanent neurologic deficits with relatively little hope for recovery.

The type and frequency of screening for malignancy depends on the specific antibody syndrome.<sup>50</sup> If a patient is diagnosed with an autoantibody commonly associated with paraneoplastic syndromes, frequent monitoring is recommended. In those cases, we typically order surveillance testing every 6 to 12 months for at least 3 to 5 years. If the patient has an antibody with a low likelihood of an underlying neoplasm, we consider reevaluating once a year for 3 years after the index diagnosis.<sup>50</sup>

Based on the 2011 European Federation of the Neurological Societies guidelines, we will utilize either whole-body FDG-PET or CT of the chest, abdomen, and pelvis as a screening measure for certain AE patients, with clinical consideration of the known cancer associations, cancer risk factors, or family history of cancer.<sup>50</sup>

In particular, the nature of the antibody determines the risk and type of an underlying malignancy and therefore the investigation. For example, anti-Yo autoantibody has a greater than 90% association with breast or ovarian malignancy, so an extensive evaluation should be pursued to identify the underlying neoplasm.<sup>50</sup>

In addition, sex-specific tests such as pelvic ultrasonography, mammography, and testicular ultrasonography should be considered if the initial evaluation is unrevealing. Further, all patients should complete routine age- and sex-appropriate screening measures including screening for breast, colorectal, cervical, and prostate cancer, along with lung cancer when applicable, based on US Preventive Services Task Force recommendations.

## ■ TAKE-HOME MESSAGE

Our understanding of AE has expanded dramatically over the past few years. Familiarity with different AE syndromes will ensure prompt diagnosis and treatment. In cases that are less clear, a sound diagnostic approach anchored on objective clinical or radiographic findings is important for optimizing outcomes. Clinicians

**Anti-NMDA receptor encephalitis responds to immunotherapies, but response can be slow**

need to stay abreast of developments in this field as the breadth of immune-mediated disorders of the nervous system continues to evolve.

## DISCLOSURES

The authors report no relevant financial relationships which, in the context of their contributions, could be perceived as a potential conflict of interest.

## REFERENCES

- Dalmau J, Graus F. Antibody-mediated encephalitis. *N Engl J Med* 2018; 378(9):840–851. doi:10.1056/NEJMr1708712
- Zekeridou A, Lennon VA. Neurologic autoimmunity in the era of checkpoint inhibitor cancer immunotherapy. *Mayo Clin Proc* 2019; 94(9):1865–1878. doi:10.1016/j.mayocp.2019.02.003
- Kunchok A, Aksamit AJ Jr, Davis JM 3rd, et al. Association between tumor necrosis factor inhibitor exposure and inflammatory central nervous system events. *JAMA Neurol* 2020; 77(8):937–946. doi:10.1001/jamaneurol.2020.1162
- Dubey D, Pittock SJ, Kelly CR, et al. Autoimmune encephalitis epidemiology and a comparison to infectious encephalitis. *Ann Neurol* 2018; 83(1):166–177. doi:10.1002/ana.25131
- Lancaster E. The diagnosis and treatment of autoimmune encephalitis. *J Clin Neurol* 2016; 12(1):1–13. doi:10.3988/jcn.2016.12.1.1
- Bradshaw MJ, Linnoila JJ. An overview of autoimmune and paraneoplastic encephalitis. *Semin Neurol* 2018; 38(3):330–343. doi:10.1055/s-0038-1660821
- McKeon A. Autoimmune encephalopathies and dementias. *Continuum (Minneapolis)* 2016; 22(2 Dementia):538–558. doi:10.1212/CON.0000000000000299
- Graus F, Titulaer MJ, Balu R, et al. A clinical approach to diagnosis of autoimmune encephalitis. *Lancet Neurol* 2016; 15(4):391–404. doi:10.1016/S1474-4422(15)00401-9
- Auger RG. AAEM minimonograph #44: diseases associated with excess motor unit activity. *Muscle Nerve* 1994; 17(11):1250–1263. doi:10.1002/mus.880171103
- Dutra LA, Abrantes F, Toso FF, Pedrosa JL, Barsottini OGP, Hoftberger R. Autoimmune encephalitis: a review of diagnosis and treatment. *Arq Neuropsiquiatr* 2018; 76(1):41–49. doi:10.1590/0004-282X20170176
- Ariño H, Armangué T, Petit-Pedrol M, et al. Anti-LGI1-associated cognitive impairment: presentation and long-term outcome. *Neurology* 2016; 87(8):759–765. doi:10.1212/WNL.0000000000003009
- Bastiaansen AEM, van Sonderen A, Titulaer MJ. Autoimmune encephalitis with anti-leucine-rich glioma-inactivated 1 or anti-contactin-associated protein-like 2 antibodies (formerly called voltage-gated potassium channel-complex antibodies). *Curr Opin Neurol* 2017; 30(3):302–309. doi:10.1097/WCO.0000000000000444
- Dalmau J, Tüzün E, Wu HY, et al. Paraneoplastic anti-N-methyl-D-aspartate receptor encephalitis associated with ovarian teratoma. *Ann Neurol* 2007; 61(1):25–36. doi:10.1002/ana.21050
- Guasp M, Dalmau J. Encephalitis associated with antibodies against the NMDA receptor. *Med Clin (Barc)* 2018; 151(2):71–79. doi:10.1016/j.medcli.2017.10.015
- Titulaer MJ, McCracken L, Gabilondo I, et al. Treatment and prognostic factors for long-term outcome in patients with anti-NMDA receptor encephalitis: an observational cohort study. *Lancet Neurol* 2013; 12(2):157–165. doi:10.1016/S1474-4422(12)70310-1
- de Bruijn MAAM, van Sonderen A, van Coevorden-Hameete MH, et al. Evaluation of seizure treatment in anti-LGI1, anti-NMDAR, and anti-GABABR encephalitis. *Neurology* 2019; 92(19):e2185–e2196. doi:10.1212/WNL.00000000000007475
- Feyissa AM, López Chiriboga AS, Britton JW. Antiepileptic drug therapy in patients with autoimmune epilepsy. *Neurol Neuroimmunol Neuroinflamm* 2017; 4(4):e353. doi:10.1212/NXI.0000000000000353
- Schmitt SE, Pargeon K, Frechette ES, Hirsch LJ, Dalmau J, Friedman D. Extreme delta brush: a unique EEG pattern in adults with anti-NMDA receptor encephalitis. *Neurology* 2012; 79(11):1094–1100. doi:10.1212/WNL.0b013e3182698cd8
- Armangué T, Spatola M, Vlagea A, et al. Frequency, symptoms, risk factors, and outcomes of autoimmune encephalitis after herpes simplex encephalitis: a prospective observational study and retrospective analysis. *Lancet Neurol* 2018; 17(9):760–772. doi:10.1016/S1474-4422(18)30244-8
- Ma J, Zhang T, Jiang L. Japanese encephalitis can trigger anti-N-methyl-D-aspartate receptor encephalitis. *J Neurol* 2017; 264(6):1127–1131. doi:10.1007/s00415-017-8501-4
- Dalmau J, Armangué T, Planagumà J, et al. An update on anti-NMDA receptor encephalitis for neurologists and psychiatrists: mechanisms and models. *Lancet Neurol* 2019; 18(11):1045–1057. doi:10.1016/S1474-4422(19)30244-3
- Nosadini M, Mohammad SS, Ramanathan S, Brilot F, Dale RC. Immune therapy in autoimmune encephalitis: a systematic review. *Expert Rev Neurother* 2015; 15(12):1391–1419. doi:10.1586/14737175.2015.1115720
- López-Chiriboga AS, Flanagan EP. Diagnostic and therapeutic approach to autoimmune neurologic disorders. *Semin Neurol* 2018; 38(3):392–402. doi:10.1055/s-0038-1660819
- Irani SR, Alexander S, Waters P, et al. Antibodies to Kv1 potassium channel-complex proteins leucine-rich, glioma inactivated 1 protein and contactin-associated protein-2 in limbic encephalitis, Morvan's syndrome and acquired neuromyotonia. *Brain* 2010; 133(9):2734–2748. doi:10.1093/brain/awq213
- Flanagan EP, Kotsenas AL, Britton JW, et al. Basal ganglia T1 hyperintensity in LGI1-autoantibody faciobrachial dystonic seizures. *Neurol Neuroimmunol Neuroinflamm* 2015; 2(6):e161. doi:10.1212/NXI.0000000000000161
- Vernino S. Autoimmune autonomic disorders. *Continuum (Minneapolis)* 2020; 26(1):44–57. doi:10.1212/CON.0000000000000812
- van Sonderen A, Thijs RD, Coenders EC, et al. Anti-LGI1 encephalitis: clinical syndrome and long-term follow-up. *Neurology* 2016; 87(14):1449–1456. doi:10.1212/WNL.00000000000003173
- Gadoth A, Pittock SJ, Dubey D, et al. Expanded phenotypes and outcomes among 256 LGI1/CASPR2-IgG-positive patients. *Ann Neurol* 2017; 82(1):79–92. doi:10.1002/ana.24979
- Dubey D, Britton J, McKeon A, et al. Randomized placebo-controlled trial of intravenous immunoglobulin in autoimmune LGI1/CASPR2 epilepsy. *Ann Neurol* 2020; 87(2):313–323. doi:10.1002/ana.25655
- van Sonderen A, Schreurs MW, de Bruijn MA, et al. The relevance of VGKC positivity in the absence of LGI1 and Caspr2 antibodies. *Neurology* 2016; 86(18):1692–1699. doi:10.1212/WNL.00000000000002637
- Armangué T, Leypoldt F, Dalmau J. Autoimmune encephalitis as differential diagnosis of infectious encephalitis. *Curr Opin Neurol* 2014; 27(3):361–368. doi:10.1097/WCO.0000000000000087
- Messias EL, Chen CY, Eaton WW. Epidemiology of schizophrenia: review of findings and myths. *Psychiatr Clin North Am* 2007; 30(3):323–338. doi:10.1016/j.psc.2007.04.007
- Galli JR, Austin SD, Greenlee JE, Clardy SL. Stiff person syndrome with Anti-GAD65 antibodies within the national veterans affairs health administration. *Muscle Nerve* 2018; 58(6):801–804. doi:10.1002/mus.26338
- Bernasconi A, Cendes F, Theodore WH, et al. Recommendations for the use of structural magnetic resonance imaging in the care of patients with epilepsy: a consensus report from the International League Against Epilepsy Neuroimaging Task Force. *Epilepsia* 2019; 60(6):1054–1068. doi:10.1111/epi.15612
- Frohmman EM, Wingerchuk DM. Clinical practice. Transverse myelitis. *N Engl J Med* 2010; 363(6):564–572. doi:10.1056/NEJMc1001112
- Probasco JC, Solnes L, Nalluri A, et al. Abnormal brain metabolism on FDG-PET/CT is a common early finding in autoimmune encephalitis. *Neurol Neuroimmunol Neuroinflamm* 2017; 4(4):e352. doi:10.1212/NXI.0000000000000352
- Leypoldt F, Buchert R, Kleiter I, et al. Fluorodeoxyglucose positron emission tomography in anti-N-methyl-D-aspartate receptor en-



- cephalitis: distinct pattern of disease. *J Neurol Neurosurg Psychiatry* 2012; 83(7):681–686. doi:10.1136/jnnp-2011-301969
38. **McKeon A, Apiwattanakul M, Lachance DH, et al.** Positron emission tomography-computed tomography in paraneoplastic neurologic disorders: systematic analysis and review. *Arch Neurol* 2010; 67(3):322–329. doi:10.1001/archneurol.2009.336
39. **Ebright MJ, Li SH, Reynolds E, et al.** Unintended consequences of Mayo paraneoplastic evaluations. *Neurology* 2018; 91(22):e2057–e2066. doi:10.1212/WNL.00000000000006577
40. **Rossi M, Mead S, Collinge J, Rudge P, Vincent A.** Neuronal antibodies in patients with suspected or confirmed sporadic Creutzfeldt-Jakob disease. *J Neurol Neurosurg Psychiatry* 2015; 86(6):692–694. doi:10.1136/jnnp-2014-308695
41. **Schiess N, Pardo CA.** Hashimoto's encephalopathy. *Ann N Y Acad Sci* 2008; 1142:254–265. doi:10.1196/annals.1444.018
42. **Mattozzi S, Sabater L, Escudero D, et al.** Hashimoto encephalopathy in the 21st century. *Neurology* 2020; 94(2):e217–e224. doi:10.1212/WNL.00000000000008785
43. **Valencia-Sanchez C, Pittcock SJ, Mead-Harvey C, et al.** Brain dysfunction and thyroid antibodies: autoimmune diagnosis and misdiagnosis. *Brain Commun* 2021. doi:10.1093/braincomms/fcaa233.
44. **de Montmollin E, Demeret S, Brulé N, et al.** Anti-N-methyl-D-aspartate receptor encephalitis in adult patients requiring intensive care. *Am J Respir Crit Care Med* 2017; 195(4):491–499. doi:10.1164/rccm.201603-0507OC
45. **Shin YW, Lee ST, Park KI, et al.** Treatment strategies for autoimmune encephalitis. *Ther Adv Neurol Disord* 2018; 11:1–19. doi:10.1177/1756285617722347
46. **Dalmau J, Gleichman AJ, Hughes EG, et al.** Anti-NMDA-receptor encephalitis: case series and analysis of the effects of antibodies. *Lancet Neurol* 2008; 7(12):1091–1098. doi:10.1016/S1474-4422(08)70224-2
47. **Irani SR, Bera K, Waters P, et al.** N-methyl-D-aspartate antibody encephalitis: temporal progression of clinical and paraclinical observations in a predominantly non-paraneoplastic disorder of both sexes. *Brain* 2010; 133(pt 6):1655–1667. doi:10.1093/brain/awq113
48. **Schmitz-Hübsch T, du Montcel ST, Baliko L, et al.** Scale for the assessment and rating of ataxia: development of a new clinical scale. *Neurology* 2006; 66(11):1717–1720. doi:10.1212/01.wnl.0000219042.60538.92
49. **Hébert J, Day GS, Steriade C, Wennberg RA, Tang-Wai DF.** Long-term cognitive outcomes in patients with autoimmune encephalitis. *Can J Neurol Sci* 2018; 45(5):540–544. doi:10.1017/cjn.2018.33
50. **Titulaer MJ, Soffietti R, Dalmau J, et al.** Screening for tumours in paraneoplastic syndromes: report of an EFNS task force. *Eur J Neurol* 2011; 18(1):19–e3. doi:10.1111/j.1468-1331.20

**Address:** Justin R. Abbatemarco, MD, Mellen Center for Multiple Sclerosis, U10, Cleveland Clinic, 9500 Euclid Avenue, Cleveland, OH 44195; justinabbatemarco@gmail.com