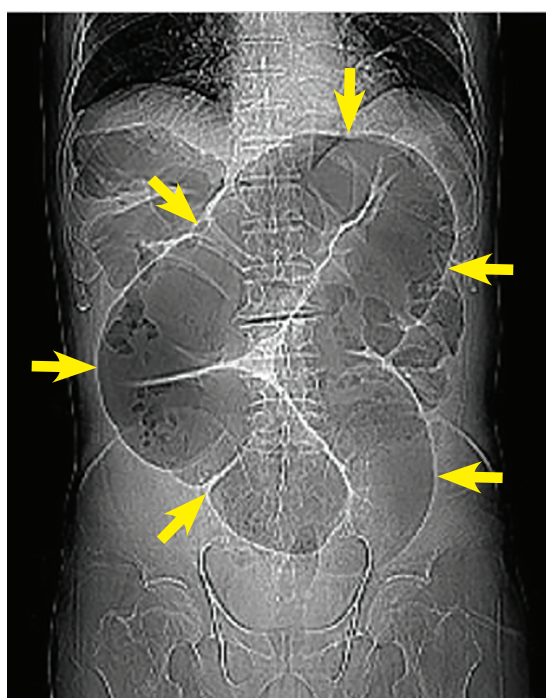
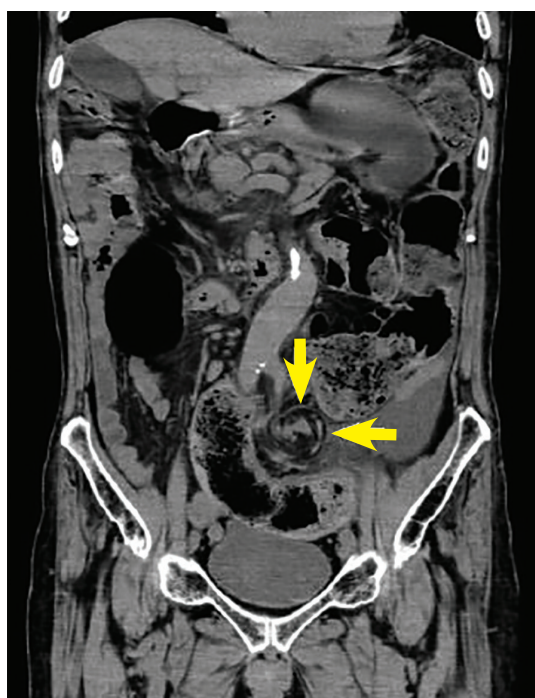


# Sigmoid volvulus: Coffee bean sign, whirl sign



**Figure 1.** Computed tomography preliminary view showed a distended sigmoid loop with an inverted U-shape (arrows), also known as the coffee bean sign.



**Figure 2.** Computed tomography coronal view showed the whirl sign, representing twisted bowel and mesentery (arrows).

**A 79-year-old man with cortical cerebellar atrophy presented with progressive abdominal distention and constipation**

**A** 79-YEAR-OLD MAN with cortical cerebellar atrophy presented to the gastroenterology department with a 7-day history of progressive abdominal distention and constipation. He had a history of chronic constipation due to neurogenic bowel dysfunction. The dysfunction had been managed with laxatives.

On physical examination, his abdomen was distended and tender, and bowel sounds were absent. There was no fever, abdominal rigidity, or guarding.

doi:10.3949/ccjm.87a.19064

## ■ 'COFFEE BEAN' SIGN AND 'WHIRL' SIGN

The preliminary view on abdominal computed tomography (CT) showed a distended sigmoid loop with an inverted U-shape, also known as the coffee bean sign, bent innertube sign, or kidney bean sign (**Figure 1**). This feature was also seen on plain abdominal radiography. In addition, the CT coronal view revealed the whirl sign, representing twisted bowel and mesentery (**Figure 2**). These findings were consistent with sigmoid volvulus.

Emergency endoscopy confirmed torsion

of the sigmoid colon without mucosal ischemia or masses. The colonoscope was successfully passed through the volvulus and into the dilated colon, resulting in reduction of the volvulus.

### ■ SIGMOID VOLVULUS

Sigmoid volvulus is the third most common cause of bowel obstruction after cancer and diverticulitis.<sup>1</sup> Risk factors include chronic constipation, diabetes mellitus, neurologic disorders, and previous abdominal surgery.<sup>2</sup> The classic clinical presentation is a triad of abdominal pain, distention, and constipation.<sup>3</sup>

Sigmoid volvulus is potentially life-threatening, and early diagnosis and treatment are

essential. Endoscopic procedures such as decompression and reduction are the emergency treatments of choice in uncomplicated acute sigmoid volvulus.<sup>2</sup> Flexible sigmoidoscopy or even rigid proctoscopy is usually used as non-operative treatment; colonoscopy is not necessarily needed for decompression.

Emergency surgery is an option only when nonoperative treatment is unsuccessful, or in patients with perforation, bowel infarction, or peritonitis.<sup>2,4</sup>

Because of the high recurrence rate after endoscopic treatment, elective surgery is recommended to reduce morbidity and mortality risk.<sup>4</sup>

### ■ REFERENCES

1. Lee YS, Lee WJ. Coffee-bean sign. *CMAJ* 2008; 178(13):1657. doi:10.1503/cmaj.071760
2. Lou Z, Yu ED, Zhang W, Meng RG, Hao LQ, Fu CG. Appropriate treatment of acute sigmoid volvulus in the emergency setting. *World J Gastroenterol* 2013; 19(30):4979–4983. doi:10.3748/wjg.v19.i30.4979
3. Levsky JM, Den EI, DuBrow RA, Wolf EL, Rozenblit AM. CT findings of sigmoid volvulus. *AJR Am J Roentgenol* 2010; 194(1):136–143. doi:10.2214/AJR.09.2580
4. ASGE Standards of Practice Committee; Harrison ME, Anderson MA, Appalaneni V, et al. The role of endoscopy in the management of patients with known and suspected colonic obstruction and pseudo-obstruction. *Gastrointest Endosc* 2010; 71(4):669–679. doi:10.1016/j.gie.2009.11.027

Address: Yusaku Kajihara, MD, FACP, Department of Gastroenterology, Fuyoukai Murakami Hospital, 3-3-14 Hamada, Aomori 030-0843, Japan; y\_kaji2012@yahoo.co.jp