

THE CLINICAL PICTURE

AHMAD MUNEEB SHARAYAH, MD
Department of Internal Medicine, Monmouth
Medical Center, Long Branch, NJ

NOOR HAJJAJ, MD
Faculty of Medicine,
University of Jordan,
Amman, Jordan

RAMY OSMAN, MD
Department of Internal Medicine,
Monmouth Medical Center,
Long Branch, NJ

DOUGLAS LIVORNESE, MD
Department of Pulmonary and Critical Care
Medicine, Monmouth Medical Center,
Long Branch, NJ

Gastroparesis in a patient with diabetic ketoacidosis

Diabetic ketoacidosis can cause symptoms similar to those of gastroparesis

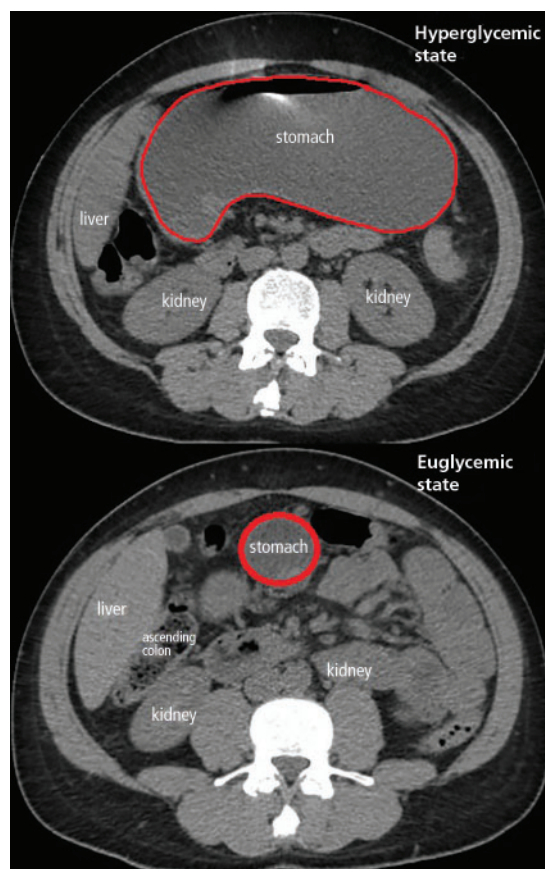


FIGURE 1. Computed tomography at presentation (top) and 11 months previously (bottom).

A 40-YEAR-OLD MAN with type 1 diabetes mellitus and recurrent renal calculi presented to the emergency department with nausea, vomiting, and abdominal pain for the past day. He had been checking his blood glucose level regularly, and it had usually been within the normal range until 2 or 3 days previously,

doi:10.3949/cjcm.86a.18116

when he stopped taking his insulin because he ran out and could not afford to buy more.

He said he initially vomited clear mucus but then had 2 episodes of black vomit. His abdominal pain was diffuse but more intense in his flanks. He said he had never had nausea or vomiting before this episode.

In the emergency department, his heart rate was 136 beats per minute and respiratory rate 24 breaths per minute. He appeared to be in mild distress, and physical examination revealed a distended abdomen, decreased bowel sounds on auscultation, tympanic sound elicited by percussion, and diffuse abdominal tenderness to palpation without rebound tenderness or rigidity. His blood glucose level was 993 mg/dL, and his anion gap was 36 mmol/L.

Computed tomography (CT) showed new severe gastric distention; a scan 11 months previously to look for renal stones had been normal (**Figure 1**). The patient's presentation, physical examination, and laboratory and radiographic investigations narrowed the working diagnosis to gastric outlet obstruction or acute gastroparesis, but since CT showed no obstructing mass, the diagnosis of acute gastroparesis that coexisted with diabetic ketoacidosis was more likely.

The patient was treated with hydration, insulin, and a nasogastric tube to relieve the pressure. The following day, his symptoms had significantly improved, his abdomen was less distended, his bowel sounds had returned, and his plasma glucose levels were in the normal range. The nasogastric tube was removed after he started to have bowel movements; he was given liquids by mouth and eventually solid food. Since his condition had significantly improved and he had started to have bowel

movements, no follow-up imaging was done. The next day, he was symptom-free, his laboratory values were normal, and he was discharged home.

■ GASTROPARESIS

Gastroparesis is defined by delayed gastric emptying in the absence of a mechanical obstruction, with symptoms of nausea, vomiting, bloating, and abdominal pain. Most commonly it is idiopathic or caused by long-standing uncontrolled diabetes.

Diabetic gastroparesis is thought to result from impaired neural control of gastric function. Damage to the pacemaker interstitial cells of Cajal and underlying smooth muscle may be contributing factors.¹ It is usually chronic, with a mean duration of symptoms of 26.5 months.² However, acute gastroparesis can occur after an acute elevation in the plasma glucose concentration, which can affect gastric sensory and motor function³ via relaxation of the proximal stomach, decrease in antral pressure waves, and increase in pyloric pressure waves.⁴

Patients with diabetic ketoacidosis often present with symptoms similar to those of gastroparesis, including nausea, vomiting, and abdominal pain.⁵ But acute gastroparesis can coexist with diabetic ketoacidosis, as in our patient, and the gastroparesis can go undiagnosed, since imaging studies are not routinely done for diabetic ketoacidosis unless there is another reason—as in our patient.

More study is needed to answer questions on long-term outcomes for patients presenting with acute gastroparesis: Do they develop

chronic gastroparesis? And is there is a correlation with progression of neuropathy?

The diagnosis usually requires a high level of suspicion in patients with nausea, vomiting, fullness, abdominal pain, and bloating; exclusion of gastric outlet obstruction by a mass or antral stenosis; and evidence of delayed gastric emptying. Gastric outlet obstruction can be ruled out by endoscopy, abdominal CT, or magnetic resonance enterography. Delayed gastric emptying can be quantified with scintigraphy and endoscopy. In our patient, gastroparesis was diagnosed on the basis of the clinical symptoms and CT findings.

Treatment is usually directed at symptoms, with better glycemic control and dietary modification for moderate cases, and prokinetics and a gastrostomy tube for severe cases.

■ TAKE-HOME POINTS

- Gastroparesis is usually chronic but can present acutely with acute severe hyperglycemia.
- Gastrointestinal tract motor function is affected by plasma glucose levels and can change over brief intervals.
- Diabetic ketoacidosis symptoms can mask acute gastroparesis, as imaging studies are not routinely done.
- Acute gastroparesis can be diagnosed clinically along with abdominal CT or endoscopy to rule out gastric outlet obstruction.
- Acute gastroparesis caused by diabetic ketoacidosis can resolve promptly with tight control of plasma glucose levels, anion gap closing, and nasogastric tube placement. ■

■ REFERENCES

1. Parkman HP, Hasler WL, Fisher RS; American Gastroenterological Association. American Gastroenterological Association technical review on the diagnosis and treatment of gastroparesis. *Gastroenterology* 2004; 127(5):1592–1622. PMID:15521026
2. Dudekula A, O'Connell M, Bielefeldt K. Hospitalizations and testing in gastroparesis. *J Gastroenterol Hepatol* 2011; 26(8):1275–1282. doi:10.1111/j.1440-1746.2011.06735.x
3. Fraser RJ, Horowitz M, Maddox AF, Harding PE, Chatter-

ton BE, Dent J. Hyperglycaemia slows gastric emptying in type 1 (insulin-dependent) diabetes mellitus. *Diabetologia* 1990; 33(11):675–680. PMID:2076799

4. Mearin F, Malagelada JR. Gastroparesis and dyspepsia in patients with diabetes mellitus. *Eur J Gastroenterol Hepatol* 1995; 7(8):717–723. PMID:7496857
5. Malone ML, Gennis V, Goodwin JS. Characteristics of diabetic ketoacidosis in older versus younger adults. *J Am Geriatr Soc* 1992; 40(11):1100–1104. PMID:1401693

ADDRESS: Ahmad Muneer Sharayah, MD, Department of Internal Medicine, Monmouth Medical Center, 300 2nd Avenue, Long Branch, NJ 07740; drsharayah@gmail.com