

CHESTER V. ODDIS, MD

Director, Myositis Center, Department of Medicine;
Professor of Medicine, University of Pittsburgh,
Pittsburgh, PA

Myopathy for the general internist: Statins and much more

ABSTRACT

Patients with muscle diseases are often seen initially by general practitioners. This article reviews how to evaluate and manage such patients, including those taking a statin, how to interpret creatine kinase (CK) test results, and how to recognize common as well as potentially dangerous myopathies.

KEY POINTS

Inclusion body myositis affects older men more than women and is characterized by slowly progressive, asymmetric, distal and proximal weakness and atrophy.

Statin-associated muscle complaints are common, whereas necrotizing myopathy, characterized by a very high CK plus weakness, is rare but must be recognized.

Elevated CK does not necessarily indicate myositis, especially in African Americans or after heavy exercise.

Dermatomyositis is characterized by muscle weakness and raised red or purple Gottron papules over the knuckles, elbows, or knees.

Autoimmune interstitial lung disease may be caused by a variety of antibodies, the most common being anti-Jo-1 (directed against histidyl tRNA synthetase).

The rarer non-Jo-1 antisynthetase autoantibodies may be associated with rapidly progressive interstitial lung disease, which is a challenge to recognize because associated rheumatologic symptoms may be minimal.

Medical Grand Rounds articles are based on edited transcripts from Medicine Grand Rounds presentations at Cleveland Clinic. They are approved by the author but are not peer-reviewed.
doi:10.3949/ccjm.86gr.19001

MYOPATHIES CAN PRESENT with a wide variety of symptoms, so patients with muscle weakness are often seen initially by a general practitioner. Nonrheumatologists should be able to evaluate a patient presenting with muscle weakness or myalgia and be aware of red flags indicating potentially dangerous syndromes that require a prompt, thorough investigation.

This article reviews selected causes of muscle weakness, such as statin-induced and autoimmune disorders, and systemic features of inflammatory myopathies beyond myositis, such as dermatologic and pulmonary manifestations.

■ FOCUSING THE EVALUATION

The evaluation of a patient presenting with muscle weakness should include several assessments:

Temporal progression. Was the onset of symptoms rapid or insidious? Patterns of onset may give clues to etiology, including the possibility of an associated autoimmune condition.

Location of muscle weakness. Are symptoms global or localized? And if localized, are they proximal or distal? Proximal weakness can be manifested by difficulty rising from a chair (hip muscles) or combing one's hair (shoulder muscles), whereas distal weakness can involve difficulty standing on toes (gastrocnemius and soleus muscles) or performing fine motor activities (intrinsic hand muscles).

Symmetry. A focal or asymmetric pattern often has a neurologic etiology, but this could also be consistent with inclusion body myositis.

Other symptoms. Arthritis, rash, and swallowing problems point to a possible underlying rheumatologic disease. Weight gain or loss may indicate a thyroid disorder.

Family history. Some patients report that others in their family have this pattern of weakness, indicating a likely genetic myopathy. If the patient reports a relative with multiple sclerosis, lupus erythematosus, rheumatoid arthritis, or another autoimmune disease, then an immune-mediated myopathy should be considered.

Medications should be reviewed, particularly statins.

■ CASE 1: SLOWLY PROGRESSIVE WEAKNESS

A 65-year-old man presented with the insidious onset of muscle weakness and episodes of falling. On review of his medical record, his serum creatine kinase (CK) levels were elevated at various periods at 2 to 4 times the upper limit of normal. Electromyography (EMG) previously showed a myopathic pattern, and a muscle biopsy was abnormal, consistent with endomysial inflammation (term is consistent with “polymyositis”). He was treated for polymyositis for several years with prednisone alone, with steroids plus methotrexate, and with combined immunosuppression including methotrexate and azathioprine, but with no improvement. Eventually, another muscle biopsy revealed inclusion bodies with rimmed vacuoles, consistent with inclusion body myositis.

Inclusion body myositis

Inclusion body myositis is the most common myopathy in middle-aged to elderly people, especially men. These patients are often told “You are just getting old,” but they have a defined condition. It should also be considered in patients failing to respond to treatment or with those with “refractory” polymyositis.

The onset of muscle weakness is insidious and painless, and the weakness progresses slowly. The pattern is distal and asymmetric (eg, foot drop), and muscle atrophy typically affects the forearm flexors, quadriceps, and intrinsic muscles of the hands.¹

Magnetic resonance imaging may show marked muscle atrophy. Unfortunately, no treatment has shown efficacy, and most neuromuscular and rheumatology experts do not treat inclusion body myositis with immunosuppressive drugs.

■ CASE 2: MILD MYALGIA WITHOUT WEAKNESS

A black 52-year-old man was referred because of myalgia and a CK level of 862 U/L (reference range < 200). His physician wanted to start him on a statin but was hesitant to do so without first consulting a rheumatologist.

The patient had a long history of mild arthralgias and myalgias without muscle weakness. He had dyslipidemia and hypertension. He reported no family history of myopathy and no illicit drug use. He was formerly an athlete. Medications included a thiazide diuretic and a beta-blocker. On examination, his muscles were strong (rated 5 on a scale of 5) in the upper and lower extremities, without atrophy.

His records showed that his CK levels had risen and fallen repeatedly over the past few years, ranging from 600 to 1,100 U/L. On further questioning, he reported that when he had joined the army 30 years previously, a physician had recommended he undergo a liver biopsy in view of elevated liver function tests, but that he had refused because he felt fine.

Currently, his gamma-glutamyl transpeptidase levels were normal.

Idiopathic ‘hyperCKemia’

So-called idiopathic hyperCKemia is not a form of myositis but merely a laboratory result outside the “normal” range. Reference ranges are based predominantly on measurements in white people and on an assumption that the distribution is Gaussian (bell-shaped). A normal CK level is usually defined as less than 200 U/L. Using this standard, up to 20% of men and 5% of women have hyperCKemia.²

However, CK levels vary by sex and ethnicity, with mean levels highest in black men, followed by black women, white men, and white women. The mean level in black men is higher than the standard cutoff point for normal, and especially in this population, there is wide fluctuation around the mean, leading to hyperCKemia quite frequently in black men. Exercise and manual labor also drive up CK levels.^{3–5}

Idiopathic hyperCKemia is benign. D’Adda et al⁶ followed 55 patients for a mean of 7.5 years. CK levels normalized in 12 patients or at least decreased in 24. Most remained symptom-free or had minimal symptoms.

Family history is important when considering an autoimmune etiology

TABLE 1

Polymyositis mimics

Endocrine myopathies
Hyperthyroidism
Hypothyroidism
Drug or toxic myopathies
Metabolic myopathies
Mitochondrial myopathies
Muscular dystrophies
Infectious myositis
Neuropathies and neurologic syndromes
Paraneoplastic syndromes
Other connective tissue disorders
Miscellaneous
Amyloidosis
Sarcoidosis

Idiopathic hyperCKemia: Bottom line

Before prescribing a statin, determine the baseline CK level. If slightly elevated (ie, up to 3 to 5 times the upper limit of normal, or even higher) in the setting of normal muscle strength, there is no need for electromyography or muscle biopsy, and the patient can certainly receive a statin. Most of these patients do not need to see a rheumatologist but can simply have their CK and muscle strength monitored.

CLASSIFYING MYOSITIS

Myositis (idiopathic inflammatory myopathy) is a heterogeneous group of autoimmune syndromes of unknown cause characterized by chronic muscle weakness and inflammation of striated muscle. These syndromes likely arise as a result of genetic predisposition and an environmental or infectious “hit.”

Myositis is rare, with an incidence of 5 to 10 cases per million per year and an estimated prevalence of 50 to 90 cases per million. It has 2 incidence peaks: 1 in childhood (age 5–15) and another in adult midlife (age 30–50). Women are affected 2 to 3 times more often than men, with black women most commonly affected.

Myositis is traditionally classified as follows:

- Adult polymyositis

- Adult dermatomyositis
- Juvenile myositis (dermatomyositis much more frequent than polymyositis)
- Malignancy-associated myositis (usually dermatomyositis)
- Myositis overlapping with another autoimmune disease
- Inclusion body myositis.

However, polymyositis is less common than we originally thought, and the term necrotizing myopathy is now used in many patients, as noted in the case studies below. Further, myositis overlap syndromes are being increasingly diagnosed, likely related to the emergence of autoantibodies and clinical “syndromes” associated with these autoantibody subsets (discussed in cases below).

Dermatomyositis

Dermatomyositis is characterized by muscle weakness and a rash that can be obvious or subtle. Classic skin lesions are Gottron papules, which are raised, flat-topped red or purplish lesions over the knuckles, elbows, or knees.

Lesions may be confused with those of psoriasis. There can also be a V-neck rash over the anterior chest or upper back (“shawl sign”) or a rash over the lateral thigh (“holster sign”). A facial rash may occur, but unlike lupus, dermatomyositis does not spare the nasolabial area. However, the V-neck rash can be similar to that seen in lupus.

Dermatomyositis may cause muscle pain, perhaps related to muscle ischemia, whereas polymyositis and necrotizing myopathy are often painless. However, pain is also associated with fibromyalgia, which may be seen in many autoimmune conditions. It is important not to overtreat rheumatologic diseases with immunosuppression to try to control pain if the pain is actually caused by fibromyalgia.

Polymyositis mimics

Other conditions can mimic polymyositis (Table 1).

Hypothyroid myopathy can present as classic polymyositis. The serum CK may be elevated, and there may be myalgias, muscle hypertrophy with stiffness, weakness, cramps, and even features of a proximal myopathy, and rhabdomyolysis. The electromyogram can be normal or myopathic. Results of muscle biopsy are often normal but may show focal necrosis

Inclusion body myositis is the most common myopathy in older men

and mild inflammatory infiltrates, thus mimicking that seen with inflammatory myopathy.⁷

Drug-induced or toxic myopathies can also mimic polymyositis. Statins are among the most commonly prescribed drugs in the United States, with more than 35 million people taking them. Statins are generally well tolerated but have a broad spectrum of toxicity, ranging from myalgias to life-threatening rhabdomyolysis. Myalgias lead to about 5% to 10% of patients refusing to take a statin or stopping it on their own.

Myalgias affect up to 20% of statin users in clinical practice.^{8,9} A small cross-sectional study¹⁰ of 1,000 patients in a primary care setting found that the risk of muscle complaints in statin users was 1.5 times higher than in nonstatin users, similar to findings in other studies.

Predictors of myopathic events in statin users are concurrent medications (eg, fibrates, glucocorticoids, calcium channel blockers), older age, hypothyroidism, higher body mass index, and hepatic dysfunction.¹¹

My strategy for managing a patient with possible statin-induced myopathy is illustrated in **Figure 1**.

■ CASE 3: WEAKNESS, VERY HIGH CK ON A STATIN

In March 2010, a 67-year-old woman presented with muscle weakness. She had a history of hypertension, hyperlipidemia, and, more than 10 years previously, uterine cancer. In 2004, she was given atorvastatin for dyslipidemia. Four years later, she developed lower-extremity weakness, which her doctor attributed to normal aging. A year after that, she found it difficult to walk up steps and lift her arms overhead. In June 2009, she stopped taking the atorvastatin on her own, but the weakness did not improve.

In September 2009, she returned to her doctor, who found her CK level was 6,473 U/L but believed it to be an error, so the test was repeated, with a result of 9,375 U/L. She had no rash or joint involvement.

She was admitted to the hospital and underwent muscle biopsy, which showed myonecrosis with no inflammation or vasculitis.

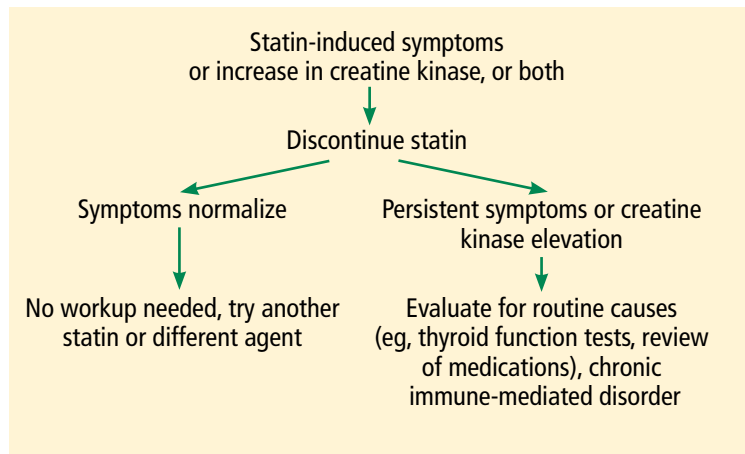


Figure 1. Strategy for evaluating statin-related myopathy.

She was treated with prednisone 60 mg/day, and her elevated CK level and weakness improved.

Immune-mediated necrotizing myopathy associated with statins

The hallmark of necrotizing myopathy is myonecrosis without significant inflammation.¹² This pattern contrasts with that of polymyositis, which is characterized by lymphocytic inflammation.

Although statins became available in the United States in 1987, immune-mediated necrotizing myopathy associated with statins was first described only in 2010. In that report, Grable-Espinoza et al¹³ described 25 patients from 2 neuromuscular centers seen between 2000 and 2008 who had elevated CK and proximal weakness during or after statin use, both of which persisted despite stopping the statin. Patients improved with immunosuppressive agents but had a relapse when steroids were stopped or tapered, a pattern typical in autoimmune disease.

Autoantibody defines subgroup of necrotizing myopathy

Also in 2010, Christopher-Stine et al¹⁴ reported an antibody associated with necrotizing myopathy. Of 38 patients with the condition, 16 were found to have an abnormal “doublet” autoantibody recognizing 200- and 100-kDa proteins. All patients had weakness and a high CK level, and 63% had statin exposure before the weakness (this percentage increased to 83% in patients older than 50). All responded to immunosuppressive therapy, and many had

HyperCKemia is not a subset of myositis but a problem with defining normal creatine kinase levels

TABLE 2

Systemic manifestations of myositis

Musculoskeletal

Weakness
Muscle pain or tenderness
Muscle atrophy
Arthralgias
Arthritis

Gastrointestinal

Dysphagia
Reflux
Dysmotility

Cutaneous

Rash
Calcification

Cardiac

Arrhythmias
Congestive failure

Pulmonary

Interstitial lung disease
Aspiration pneumonia
Interstitial fibrosis

General

Fever
Fatigue
Weight loss
Raynaud phenomenon

Idiopathic hyperCKemia is benign, and statins are not contraindicated

a relapse when it was withdrawn.

Statins lower cholesterol by inhibiting 3-hydroxy-3-methylglutaryl-Co A reductase (HMGCR), and paradoxically, they also up-regulate it. HMGCR has a molecular weight of 97 kDa. Mammen et al¹⁵ identified HMGCR as the 100-kDa target of the identified antibody and developed an enzyme-linked immunosorbent assay for it. Of 750 patients presenting to one center, only 45 (6%) had anti-HMGCR autoantibodies, but all 16 patients who had the abnormal doublet antibody tested positive for anti-HMGCR. Regenerating muscle cells express high levels of HMGCR, which may sustain the immune response after statins are discontinued.

CASE 3 continued: Intravenous immunoglobulin brings improvement

In March 2010, when the 67-year-old patient presented to our myositis center, her CK level

was 5,800 U/L, which increased as prednisone was tapered. She still felt weak. On examination, her muscle strength findings were deltoids 4+/5, neck flexors 4/5, and iliopsoas 3+/5. She was treated with methotrexate and azathioprine without benefit. She was next treated with intravenous immunoglobulin, and after 3 months, her strength normalized for the first time in years. Her CK level decreased but did not normalize. Testing showed that she was positive for anti-HMGCR autoantibody, as this test had become commercially available.

In 2015, Mammen and Tiniakou¹⁶ suggested using intravenous immunoglobulin as first-line therapy for statin-associated autoimmune necrotizing myopathy, based on experience at a single center with 3 patients who declined glucocorticoid treatment.

Necrotizing myopathy: Bottom line

Patients in whom muscle aches and pains or elevated CK persist after discontinuing statin drugs should be tested for anti-HMGCR autoantibody and be treated with intravenous immunoglobulin if anti-HMGCR autoantibodies are detected. Patients who develop necrotizing myopathy from statin exposure should never again be treated with a statin.

Myositis overlap syndromes

Heterogeneity is the rule in myositis, and it can present with a wide variety of signs and symptoms as outlined in Table 2.

■ CASE 4: FEVER, NEW 'RHEUMATOID ARTHRITIS,' AND LUNG DISEASE

A 52-year-old woman with knee osteoarthritis saw her primary care physician in November 2013 for dyspnea and low-grade fever. The next month, she presented with polyarthritis, muscle weakness, and Raynaud phenomenon.

In January 2014, she developed acrocyanosis of her fingers. Examination revealed hyperkeratotic, cracked areas of her fingers. Her oxygen saturation by pulse oximetry was low. She was admitted to the hospital. Her doctor suspected new onset of rheumatoid arthritis, but blood tests revealed a negative antinuclear antibody, so an autoimmune condition was deemed unlikely. Her CK was mildly elevated at 350 U/L.

Because of her dyspnea, an open-lung biopsy was performed. High-resolution computed tomography (CT) revealed infiltrates and ground-glass opacities, leading to the diagnosis of nonspecific interstitial pneumonia. A rheumatologist was consulted and recommended pulse methylprednisolone, followed by prednisone 60 mg/day and mycophenolate mofetil. Testing for Jo-1 antibodies was positive.

Antisynthetase syndrome

The antisynthetase syndrome is a clinically heterogeneous condition that can occur with any or all of the following:

- Fever
- Myositis
- Arthritis (often misdiagnosed as rheumatoid arthritis)
- Raynaud phenomenon
- Mechanic's hands (hyperkeratotic roughness with fissures on the lateral aspects of the fingers and finger pads)
- Interstitial lung disease.

The skin rashes and myositis may be subtle, making the presentation “lung-dominant,” and nonrheumatologists should be aware of this syndrome. Although in our patient the condition developed in a classic manner, with all of the aforementioned features of the antisynthetase syndrome, some patients will manifest one or a few of the features.

There are at least 8 known autoantibodies against tRNA synthetases (Table 3). Jo-1, directed against histidyl-tRNA synthetase, accounts for most cases (20%–30% of all myositis patients). The antibodies do not disappear with immunosuppressive therapy, so the diagnostic tests are useful even if the patient is already being treated.

Clinically, patients with the Jo-1 antisynthetase syndrome often present differently than those with non-Jo-1 antisynthetase autoantibodies. When we compared 122 patients with Jo-1 vs 80 patients with a non-Jo-1 antisynthetase autoantibody, patients with Jo-1 antibodies were more likely to have initially received a diagnosis of myositis (83%), while myositis was the original diagnosis in only 17% of those possessing non-Jo-1 antisynthetase autoantibodies. In fact, many patients (approximately 50%) were diagnosed as hav-

TABLE 3

Antiantisynthetase autoantibodies

Antibody	Antigen (tRNA synthetase)	Prevalence in idiopathic inflammatory myopathy (%)
Jo-1	Histidyl	20–30
PL-7	Threonyl	<5
PL-12	Alanyl	<5
OJ	Isoleucyl	< 5
EJ	Glycyl	< 5
KS	Asparaginyl	< 1
Try	Tyrosyl	< 1
Zo	Phenylalanyl	< 1

ing undifferentiated connective tissue disease or an overlap syndrome, and 13% had scleroderma as their first diagnosis.¹⁷

We also found that the survival rate was higher in patients with Jo-1 syndrome compared with patients with non-Jo-1 antisynthetase syndromes. We attributed the difference in survival rates to a delayed diagnosis in the non-Jo-1 group, perhaps due to their “nonclassic” presentations of the antisynthetase syndrome, delaying appropriate treatment. Patients received a diagnosis of Jo-1 antibody syndrome after a mean of 0.4 year (range 0.2–0.8), while those with a non-Jo-1 antisynthetase autoantibody had a delay in diagnosis of 1.0 year (range 0.4–5.1) ($P < .01$).¹⁷

In nearly half the cases in this cohort, pulmonary fibrosis was the cause of death, with primary pulmonary hypertension being the second leading cause (11%).

Antisynthetase syndrome: Bottom line

Antisynthetase syndrome is an often fatal disease that does not always present in a typical fashion with symptoms of myositis, as lung disease may be the predominant feature. A negative antinuclear antibody test result does not imply antibody negativity, as the autoantigen in these diseases is not located in the nucleus. Prompt diagnosis and appropriate immunosuppressive therapy are critical to improving outcomes.

Myositis is a heterogeneous group of autoimmune syndromes

■ **CASE 5: FEVER, UNDIAGNOSED LUNG DISEASE, NO MYOSITIS**

In January 2001, a 39-year-old woman was admitted to the hospital after 5 weeks of fever (temperatures 103°–104°F) and myalgias. An extensive workup was negative except for low-titer antinuclear antibody and for mild basilar fibrosis noted on chest radiography. She left the hospital against medical advice because of frustration with a lack of a specific diagnosis (“fever of unknown origin”).

Two months later, at a follow-up rheumatology consult, she reported more myalgias and arthralgias, as well as fever. Chest radiography now showed pleural effusions. Her fingers had color changes consistent with Raynaud phenomenon. At that time, I diagnosed an undifferentiated connective tissue disease and told her that I suspected an autoimmune condition that would need time to reveal itself. In the meantime, I treated her empirically with prednisone.

In April, she returned, much more short of breath and with more prominent diffuse pulmonary infiltrates. Physical examination revealed subtle Gottron changes. Testing revealed poor pulmonary function: forced vital capacity (FVC) 56%, forced expiratory volume in 1 second (FEV₁) 52%, and diffusing capacity for carbon monoxide (DLCO) 40%. Blood testing was positive for anti-PL-12 antibody, one of the non-Jo-1 antisynthetase antibodies. At this time, we treated her with glucocorticoids and tacrolimus.

More than 15 years later, this patient is doing well. Her skin rash, joint symptoms, and fever have not returned, and interestingly, she never developed myositis. Her Raynaud symptoms are mild. Her most recent pulmonary function test results (January 2018) were FVC 75%, FEV₁ 87%, and DLCO 78%. Although these results are not normal, they are much improved and allow her to be completely functional without supplemental oxygen. Echocardiography showed normal pulmonary artery systolic pressure (25 mm Hg). She was still taking tacrolimus and prednisone. When we tried to stop tacrolimus after she had done well for many years, her condition flared.

**Non-Jo-1 antisynthetase syndrome:
Bottom line**

Patients with a non-Jo-1 antisynthetase syn-

drome often present without myositis symptoms and may never manifest myositis symptoms. Likely because of this presentation, diagnosis of a specific connective tissue disorder is delayed, perhaps leading to increased mortality risk from pulmonary disease. Chronic immunosuppression is often required for these autoimmune conditions.

■ **CASE 6: DERMATOMYOSITIS, RAPIDLY PROGRESSIVE INTERSTITIAL LUNG DISEASE**

A 58-year-old woman presented in the summer of 2012 with a photosensitive rash. The following January, she returned with polyarthritides, mild muscle weakness, and a dermatomyositis-pattern rash. Her CK level was normal, and her antinuclear antibody and Sjögren syndrome antibody test results were negative. She improved on low-dose prednisone and methotrexate.

She was originally referred to me in May of that year for worsening rash and mild weakness. She denied pulmonary symptoms, but examination revealed faint basilar crackles. I increased her prednisone dosage to 20 mg/day and started mycophenolate mofetil mainly for the mild cutaneous and myositis features. I also recommended high-resolution CT of the lungs and pulmonary function tests, which she underwent in early June. High-resolution CT showed nonspecific mild infiltrates with minimal ground-glass opacities.

On July 1, she presented to her local emergency department with severe shortness of breath, requiring oxygen 12 L/min. She had a palmar rash. Repeat high-resolution CT showed dramatic worsening compared with the scan the previous month. Because of continued inadequate oxygenation, she was transferred to our center. A blood test later was positive for antimitochondrial differentiation-associated gene 5 (MDA-5) autoantibody, previously known as anticlinically amyopathic dermatomyositis (anti-CADM)-140 antibody (based on immunoprecipitation results).

She died on the third day after transfer, just 2 months after I had originally seen her, at which time she had had no pulmonary symptoms.

Dermatomyositis lesions may be confused with psoriasis, but the facial rash does not spare the nasolabial area as in lupus

Clinically amyopathic dermatomyositis

Anti-CADM-140, first reported from Asia,^{18–20} is an autoantibody-associated disease but not an antisynthetase. It is associated with dermatomyositis; patients often have a “vasculopathy” with cutaneous ulcerations and palmar papules.

MDA-5 is a cytoplasmic protein that “senses” viral RNA and induces production of type 1 interferon. It is involved in the innate immune defense against viruses.

Anti-MDA-5 positivity is associated with a poor pulmonary outcome.²¹ In our cohort from the University of Pittsburgh, many patients died within 3 years, compared with about a 40% survival rate in patients with dermatomyositis who tested negative for this antibody. That being said, many patients with anti-MDA-5 do not develop rapidly progressive interstitial lung disease.

Autoimmune interstitial lung disease: Bottom line

Autoimmune interstitial lung disease is easy to

miss, especially in the case of a non-Jo-1 syndrome, for 3 important reasons:

- The autoimmune features may initially be subtle (eg, Raynaud phenomena, mild dermatomyositis rash, undifferentiated connective tissue disease)
- Autoantibody testing is not often ordered, is not standardized, or may be unavailable
- Providers are mistakenly reassured that a patient who tests negative for antinuclear antibody does not have an autoimmune condition.

To emphasize the last point, in a cohort of 202 patients who tested positive for an anti-synthetase antibody, only half were antinuclear antibody-positive, but nearly three-quarters demonstrated anticytoplasmic staining on indirect immunofluorescence (due to the location of the autoantigen in the cytoplasm), making the latter a better screening test for an antisynthetase antibody. For scleroderma, 99% were antinuclear antibody-positive, but for myositis, this test is much less sensitive.²² ■

REFERENCES

1. Felice KJ, North WA. Inclusion body myositis in Connecticut: observations in 35 patients during an 8-year period. *Medicine (Baltimore)* 2001; 80(5):320–327. doi:10.1097/00005792-200109000-00006
2. Lev EI, Tur-Kaspa I, Ashkenazy I, et al. Distribution of serum creatine kinase activity in young healthy persons. *Clin Chim Acta* 1999; 279(1-2):107–115. doi:10.1016/s0009-8981(98)00180-6
3. Lilleng H, Abeler K, Johnsen SH, et al. Variation of serum creatine kinase (CK) levels and prevalence of persistent hyperCKemia in a Norwegian normal population. The Tromsø Study. *Neuromuscul Disord* 2011; 21(7):494–500. doi:10.1016/j.nmd.2011.04.007
4. Johnston JD, Lloyd M, Mathews JA, Hawthorne SW. Racial variation in serum creatine kinase levels. *J R Soc Med* 1996; 89(8):462–464. PMID:8795501
5. Prella A, Tancredi L, Sciacco M, et al. Retrospective study of a large population of patients with asymptomatic or minimally symptomatic raised serum creatine kinase levels. *J Neurol* 2002; 249(3):305–311. PMID:11993531
6. D’Adda E, Sciacco M, Fruguglietti ME, et al. Follow-up of a large population of asymptomatic/oligosymptomatic hyperckemic subjects. *J Neurol* 2006; 253(11):1399–1403. doi:10.1007/s00415-006-0223-y
7. Madariaga MG. Polymyositis-like syndrome in hypothyroidism: review of cases reported over the past twenty-five years. *Thyroid* 2002; 12(4):331–336. doi:10.1089/10507250252949478
8. de Sauvage Nolting PR, Buirma RJ, Hutten BA, Kastelein JJ; Dutch EXPRESS Investigator Group. Two-year efficacy and safety of simvastatin 80 mg in familial hypercholesterolemia (the Examination of Proband and Relatives in Statin Studies With Familial Hypercholesterolemia [EXPRESS FH]). *Am J Cardiol* 2002; 90(2):181–184. doi:10.1016/s0002-9149(02)02449-9
9. Bruckert E, Hayem G, Dejager S, Yau C, Bégaud B. Mild to moderate muscular symptoms with high-dosage statin therapy in hyperlipidemic patients—the PRIMO study. *Cardiovasc Drugs Ther* 2005; 19(6):403–414. doi:10.1007/s10557-005-5686-z
10. Mosshammer D, Lorenz G, Meznaric S, Schwarz J, Muche R, Mörike K. Statin use and its association with musculoskeletal symptoms—a cross-sectional study in primary care settings. *Fam Pract* 2009; 26(2):88–95. doi:10.1093/fampra/cmp006.
11. Nichols GA, Koro CE. Does statin therapy initiation increase the risk for myopathy? An observational study of 32,225 diabetic and nondiabetic patients. *Clin Ther* 2007; 29(8):1761–1770. doi:10.1016/j.clinthera.2007.08.022
12. Kassardjian CD, Lennon VA, Alfugham NB, Mahler M, Milone M. Clinical Features and Treatment Outcomes of Necrotizing Autoimmune Myopathy. *AMA Neurol* 2015; 72(9):996–1003. doi:10.1001/jamaneurol.2015.1207
13. Grable-Espósito P, Katzberg HD, Greenberg SA, Srinivasan J, Katz J, Amato AA. Immune-mediated necrotizing myopathy associated with statins. *Muscle Nerve* 2010; 41(2):185–190. doi:10.1002/mus.21486.
14. Christopher-Stine L, Casciola-Rosen LA, Hong G, Chung T, Corse AM, Mammen AL. A novel autoantibody recognizing 200-kd and 100-kd proteins is associated with an immune-mediated necrotizing myopathy. *Arthritis Rheum* 2010; 62(9):2757–2766. doi:10.1002/art.27572
15. Mammen AL, Chung T, Christopher-Stine L, et al. Autoantibodies against 3-hydroxy-3-methylglutaryl-coenzyme A reductase in patients with statin-associated autoimmune myopathy. *Arthritis Rheum* 2011; 63(3):713–721. doi:10.1002/art.30156.
16. Mammen AL, Tiniakou E. Intravenous immune globulin for statin-triggered autoimmune myopathy. *N Engl J Med* 2015; 373(17):1680–1682. doi:10.1056/NEJMc1506163
17. Aggarwal R, Cassidy E, Fertig N, et al. Patients with non-Jo-1 anti-tRNA-synthetase autoantibodies have worse survival than Jo-1 positive patients. *Ann Rheum Dis* 2014; 73(1):227–232. doi:10.1136/annrheumdis-2012-201800
18. Sato S, Hirakata M, Kuwana M, et al. Autoantibodies to a 140-kd polypeptide, CADM-140, in Japanese patients with clinically amyopathic dermatomyositis. *Arthritis Rheum* 2005; 52(5):1571–1576. doi:10.1002/art.21023
19. Sato S, Hoshino K, Satoh T, et al. RNA helicase encoded by melanoma differentiation-associated gene 5 is a major autoantigen in patients with clinically amyopathic dermatomyositis: association

with rapidly progressive interstitial lung disease. *Arthritis Rheum* 2009; 60(7):2193–2200. doi:10.1002/art.24621

20. **Chen F, Wang D, Shu X, Nakashima R, Wang G.** Anti-MDA5 antibody is associated with A/SIP and decreased T cells in peripheral blood and predicts poor prognosis of ILD in Chinese patients with dermatomyositis. *Rheumatol Int* 2012; 32(12):3909–3915. doi:10.1007/s00296-011-2323-y
21. **Moghadam-Kia S, Oddis CV, Sato S, Kuwana M, Aggarwal R.** Anti-melanoma differentiation-associated gene 5 is associated with rapidly progressive lung disease and poor survival in US patients

with amyopathic and myopathic dermatomyositis. *Arthritis Care Res (Hoboken)* 2016; 68(5):689–694. doi:10.1002/acr.22728

22. **Aggarwal R, Dhillon N, Fertig N, Koontz D, Qi Z, Oddis CV.** A negative antinuclear antibody does not indicate autoantibody negativity in myositis: role of anticytoplasmic antibody as a screening test for antisynthetase syndrome. *J Rheumatol* 2017; 44(2):223–229. doi:10.3899/jrheum.160618

ADDRESS: Chester V. Oddis, MD, Myositis Center, Department of Medicine, University of Pittsburgh, 1218 Scaife Hall, 3550 Terrace Street, Pittsburgh, PA 15261; cvo5@pitt.edu