

JOANNE SZCZYGIEL CUNHA, MD

Associate Director, Rheumatology Fellowship Program at Brown University; Division of Rheumatology, Providence VAMC; Assistant Professor in Medicine, The Warren Alpert School of Medicine, Providence, RI

ANTHONY M. REGINATO, PhD, MD

Director, Rheumatology Research and Musculoskeletal Ultrasound; Director, Rheumatology Fellowship Program at Brown University; Acting Chief, Division of Rheumatology, Providence VAMC; Associate Professor in Medicine, The Warren Alpert School of Medicine, Providence, RI

Musculoskeletal ultrasonography has arrived

A 50-YEAR-OLD WOMAN with hypertension presents with a history of polyarticular small-joint pain for the last 3 months. Her pain is worse in the morning, and it affects her metacarpal, proximal, and distal phalangeal joints. She describes intermittent swelling of her hands and morning stiffness lasting 15 to 30 minutes.

See related article, page 283

Her physical examination is unremarkable, with no evidence of active inflammation (synovitis), joint tenderness, restrictions in movement, or deformity. Her description of her symptoms raises suspicion for an inflammatory arthritis, but her physical examination does not support this diagnosis.

Beside musculoskeletal ultrasonography of her wrists reveals synovial hypertrophy, and power Doppler shows active inflammation, findings consistent with synovitis (Figure 1).

This scenario illustrates how musculoskeletal ultrasonography can prevent delayed diagnosis, thus directing the ordering of appropriate laboratory studies and allowing treatment for pain relief to be started promptly.

■ ULTRASONOGRAPHY HAS GAINED A SOLID ROLE

Ultrasonography has gained a solid role in the care of patients with musculoskeletal conditions.

Using obtained images, as well as power Doppler to assess inflammation, the clinician can visualize superficial anatomic structures, including the skin, muscles, joints, nerves, and the cortical layer of bone. Combining the dynamic assessment with the clinical

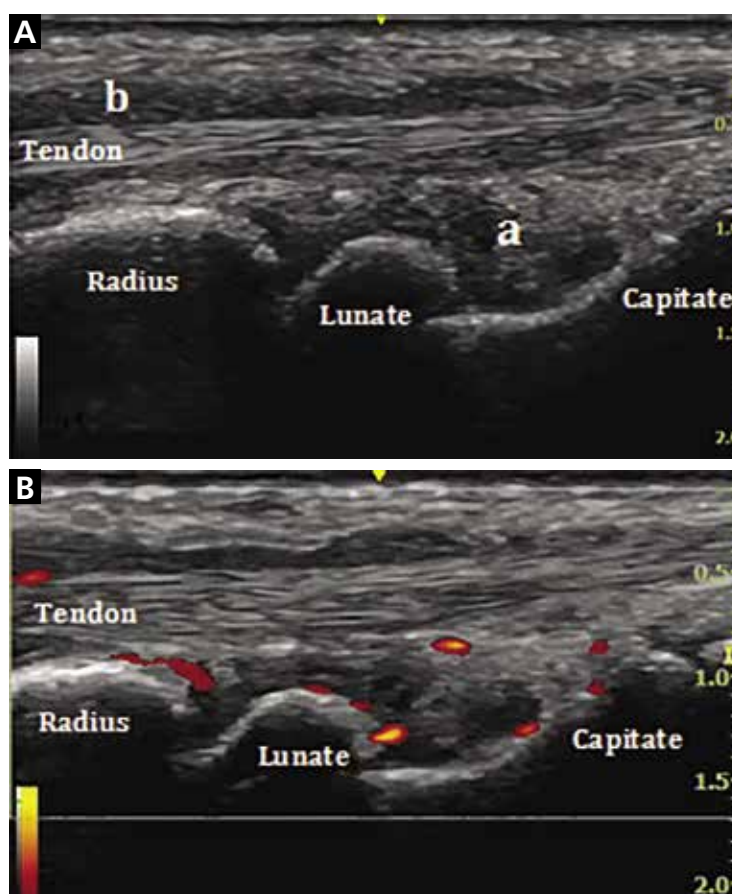


Figure 1. Musculoskeletal ultrasonography demonstrates wrist synovitis and extensor tendon tenosynovitis. In **A**, a grayscale longitudinal view of the wrist shows synovial hypertrophy (a) along with extensor tendon tenosynovitis (b). In **B**, power Doppler of the wrist shows active inflammation in the synovium (synovitis) and the extensor tendon sheath (tenosynovitis).

history and findings of the physical examination makes musculoskeletal ultrasonography a powerful tool for diagnosis and management.¹

In this issue, Forney and Delzell² review the clinical use of ultrasonography of the muscles

doi:10.3949/ccjm.85a.17127

and bones and its advantages and disadvantages compared with other imaging methods. They describe its gain in popularity over the last decade and its incorporation into clinical care in multiple medical subspecialties.

Musculoskeletal ultrasonography is performed and interpreted by specially trained sonographers. It should be viewed as a complementary procedure, not as a replacement for a thorough and systematic clinical examination.³

■ ADVANTAGES ARE MANY

A major advantage of musculoskeletal ultrasonography over other imaging techniques is its capacity to dynamically assess joint and tendon movements⁴ and to immediately interpret them in real time.

In rheumatology, where it has made the biggest impact, it can help evaluate inflammatory and noninflammatory rheumatic diseases, assess treatment response, and guide joint injections.¹ It has been demonstrated to significantly improve timely diagnosis and management,⁵ decrease dependence on other imaging modalities, and reduce healthcare costs.⁶

With its easy portability, ultrasonography has also been integrated into orthopedics, podiatry, physical medicine and rehabilitation, sports medicine, and emergency medicine. Its role is expanding to include the assessment of

the skin in systemic sclerosis, parotid and submandibular glands in Sjögren syndrome, nails in patients with psoriasis, and temporal arteries in giant cell arteritis.

■ A ROLE IN MEDICAL EDUCATION

Musculoskeletal ultrasonography has entered into medical education, with an increasing number of medical schools incorporating it into their curriculum over the last few years.⁷ It enhances student learning of anatomy, the physical examination, and pathologic findings of rheumatic diseases.^{7,8} Some internal medicine residency programs have added ultrasonography to help identify anatomic structures for invasive procedures, increasing patient safety and reducing procedural complications.⁹

It has been incorporated into the core curriculum in many rheumatology fellowship training programs.¹⁰ Rheumatologists can now also take additional courses to enhance their skills and become certified sonographers.

Musculoskeletal ultrasonography has proven to be a useful adjunct to the physical examination. With its many advantages, it has gained acceptance and is now a mainstay in many subspecialties. ■

■ REFERENCES

1. Cannella AC, Kissin EY, Torralba KD, Higgs JB, Kaeley GS. Evolution of musculoskeletal ultrasound in the United States: implementation and practice in rheumatology. *Arthritis Care Res (Hoboken)* 2014; 66(1):7–13. doi: 10.1002/acr.22183.
2. Forney MC, Delzell PB. Musculoskeletal ultrasonography basics. *Cleve Clin J Med* 2018; 85(4):283–300. doi: 10.3949/ccjm.85a.17014.
3. McAlindon T, Kissin E, Nazarian L, et al. American College of Rheumatology report on reasonable use of musculoskeletal ultrasonography in rheumatology clinical practice. *Arthritis Care Res (Hoboken)* 2012; 64(11):1625–1640. doi: 10.1002/acr.21836.
4. Backhaus M, Burmester GR, Gerber T, et al; Working Group for Musculoskeletal Ultrasound in the EULAR Standing Committee on International Clinical Studies including Therapeutic Trials. Guidelines for musculoskeletal ultrasound in rheumatology. *Ann Rheum Dis* 2001; 60(7):641–649.
5. Micu MC, Alcalde M, Saenz JJ, et al. Impact of musculoskeletal ultrasound in an outpatient rheumatology clinic. *Arthritis Care Res (Hoboken)* 2013; 65(4):615–621. doi: 10.1002/acr.21853.
6. Kay JC, Higgs JB, Battafarano DF. Utility of musculoskeletal ultrasound in a Department of Defense rheumatology practice: a four-year retrospective experience. *Arthritis Care Res (Hoboken)* 2014; 66(1):14–18. doi: 10.1002/acr.22127.
7. Dinh VA, Fu JY, Lu S, Chiem A, Fox JC, Blaivas M. Integration of ultrasound in medical education at United States medical schools. *J Ultrasound Med* 2016; 35(2):413–419. doi: 10.7863/ultra.15.05073.
8. Wright SA, Bell AL. Enhancement of undergraduate rheumatology teaching through the use of musculoskeletal ultrasound. *Rheumatology (Oxford)* 2008; 47(10):1564–1566. doi: 10.1093/rheumatology/ken324.
9. Keddiss MT, Cullen MW, Reed DA, et al. Effectiveness of an ultrasound training module for internal medicine residents. *BMC Med Educ* 2011; 11:75. doi: 0.1186/1472-6920-11-75.
10. Torralba K, Cannella AC, Kissin EY, et al. Musculoskeletal ultrasound instruction in adult rheumatology fellowship programs. *Arthritis Care Res (Hoboken)* 2017. Epub ahead of print. doi: 10.1002/acr.23336.

ADDRESS: Joanne Szczygiel Cunha, MD, The Warren Alpert School of Medicine, 375 Wampanoag Trail, Suite 302C, East Providence, RI 02915; Joanne_szczygiel@brown.edu