

THE CLINICAL PICTURE

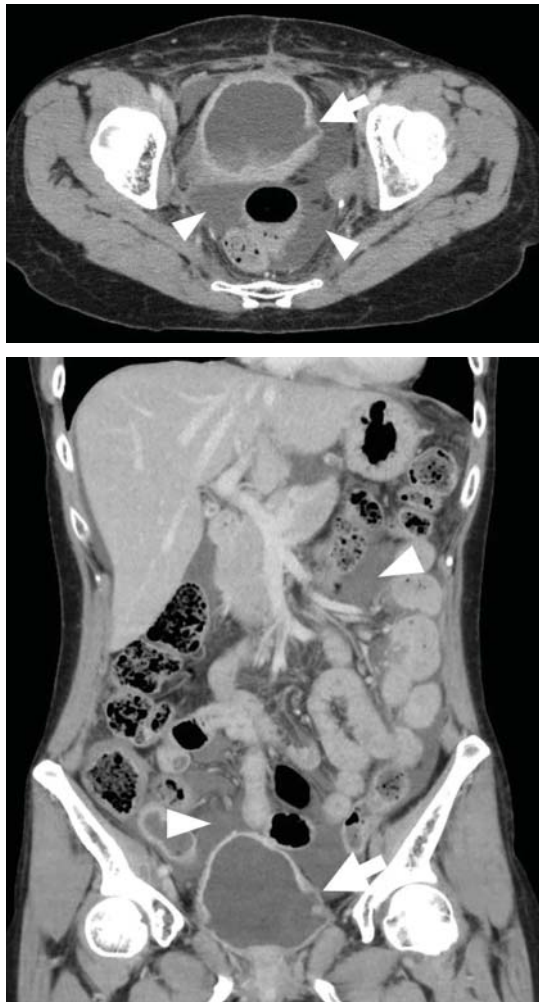
TATSUYA FUJIKAWA, MD, PhD

Department of General Internal Medicine,
Mitoyo General Hospital, Kanonji, Kagawa, Japan

YASU HARU TOKUDA, MD, PhD

Muribushi Project for Teaching Hospitals,
Okinawa, Japan

Ascites from intraperitoneal urine leakage after pelvic radiation



The effects
of radiation
therapy
on the bladder
may be seen
2 or 10 or even
40 years after
therapy
is completed

Figure 1. Contrast-enhanced computed tomography of the abdomen showed massive ascites (arrowheads) and irregularity in the bladder wall (arrow).

A 44-YEAR-OLD WOMAN was admitted to the hospital for the second time in 2 months with acute onset of severe abdominal pain. She had a history of cervical cancer treated with total hysterectomy with bilateral salpingo-oophorectomy, chemotherapy, and radiotherapy at age 38.

Abdominal examination revealed shifting dullness and tenderness without guarding. Massive ascites and irregularity in the bladder wall were detected on ultrasonography and follow-up computed tomography (Figure 1). Ascitic fluid collected during the previous admission had shown an elevated ascitic fluid-serum creatinine ratio (4.37) (reference range ≤ 1.0), highly suggestive of intraperitoneal urine leakage.¹ Thus, ascites was assumed to represent intraperitoneal urine leakage due to bladder rupture.

Cystoscopy revealed thinning of the bladder wall with a fistula, and cystography confirmed intraperitoneal leakage of contrast medium from the bladder (Figure 2). This led to the diagnosis of urinary ascites from spontaneous bladder rupture following radiation therapy for cervical cancer. She chose conservative treatment (night-time urinary catheterization without surgery), as the bladder wall was diffusely thinned, making surgery difficult. Outpatient follow-up was uneventful.

LONG-TERM EFFECTS OF RADIATION ON THE BLADDER

Urinary ascites from intraperitoneal urine leakage is a rare but clinically important sequel to bladder fistula or bladder wall rupture. Fistula or rupture can be caused by pelvic irradiation, blunt trauma, or surgical procedures, but may also be spontaneous.²

When the total radiation dose to the blad-

doi:10.3949/ccjm.85a.17028

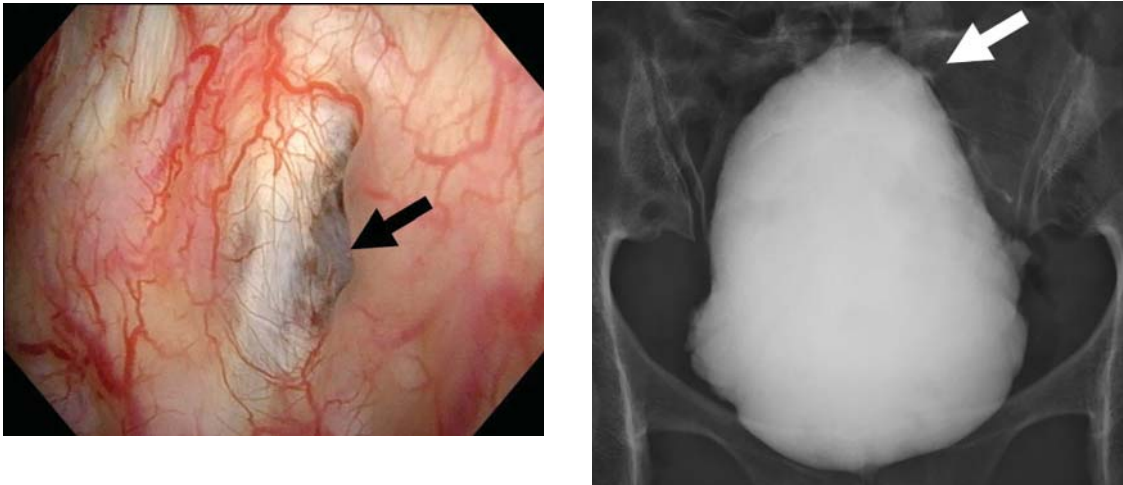


Figure 2. Left, cystoscopy showed thinning of the bladder wall with a fistula (black arrow). Right, cystography showed intraperitoneal leakage of contrast medium from the bladder (white arrow).

der exceeds 60 Gy, radiation cystitis may occur, leading to bladder fistula.³ Effects of radiation on the bladder are usually seen within 2 to 4 years³ but may occur long after the completion of radiation therapy—10 years² or even 30 to

40 years later.⁴ Therefore, ascites of unknown origin in a patient with a history of pelvic radiation therapy should lead to an evaluation for late radiation cystitis and urinary ascites from bladder rupture. ■

REFERENCES

1. Ramcharan K, Poon-King TM, Indar R. Spontaneous intraperitoneal rupture of a neurogenic bladder; the importance of ascitic fluid urea and electrolytes in diagnosis. *Postgrad Med J* 1987; 63:999–1000.
2. Matsumura M, Ando N, Kumabe A, Dhaliwal G. Pseudo-renal failure: bladder rupture with urinary ascites. *BMJ Case Rep* 2015; pii:bcr2015212671.
3. Shi F, Wang T, Wang J, et al. Peritoneal bladder fistula following radiotherapy for cervical cancer: a case report. *Oncol Lett* 2016; 12:2008–2010.
4. Hayashi W, Nishino T, Namie S, Obata Y, Furukawa M, Kohno S. Spontaneous bladder rupture diagnosis based on urinary appearance of mesothelial cells: a case report. *J Med Case Rep* 2014; 8:46.

ADDRESS: Tatsuya Fujikawa, MD, PhD, Department of General Internal Medicine, Mitoyo General Hospital, 708 Himehama Toyohama, Kanonji, Kagawa 769-1695, Japan; tfujikawa-gi@umin.ac.jp