

THE CLINICAL PICTURE

EMILY J. ELLIOTT, DO, LT MC USN
Department of Neurology, Walter Reed National
Military Medical Center, Bethesda, MD

EDWIN J. LANDAKER, MD, CDR MC USN
Department Head, Department of Neurology, Naval Medical
Center, Portsmouth, VA

Worsening migraine due to neurocysticercosis

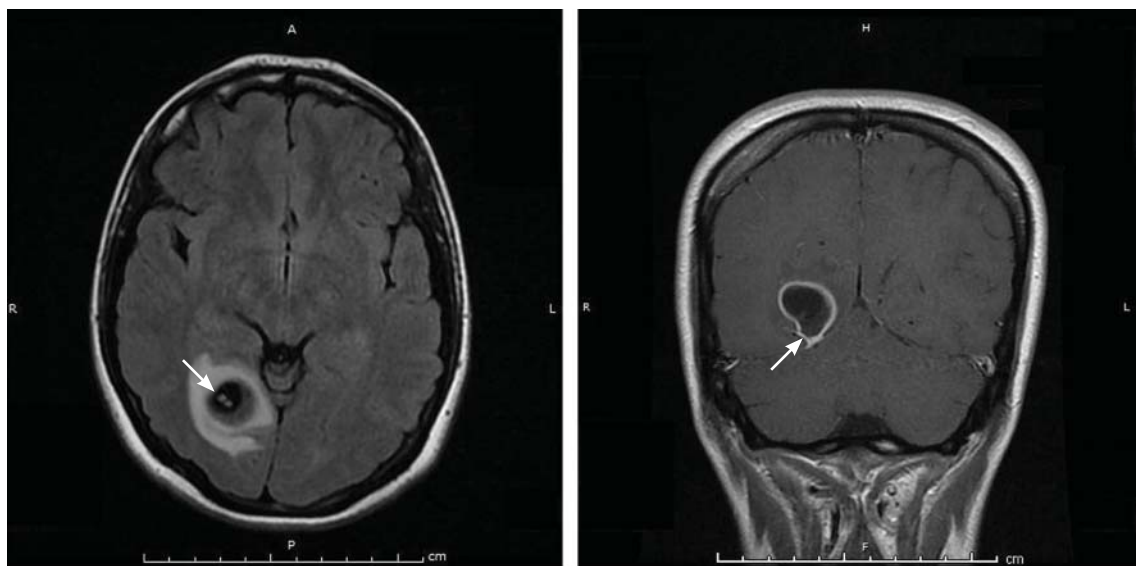


FIGURE 1. Axial fluid-attenuated inversion recovery (FLAIR) magnetic resonance imaging (left) showed a well-circumscribed spherical structure, 2 cm x 1.8 cm. A small focus of high FLAIR and T2 signal intensity was seen within the cystic structure and likely represented a scolex (arrow). A coronal T1-weighted post-contrast image (right) showed a ring-enhancing lesion and scolex at a different angle.

A 35-YEAR-OLD WOMAN with a history of migraine presented with a headache that had worsened over the past 2 weeks. The headache was occipital and was associated with blurred vision, photophobia, tingling of the hands, episodes of flashing lights and images, and difficulty concentrating. The headache was similar to her typical migraines, but with

The views expressed in this article are those of the authors and do not necessarily reflect the official policy or position of the Department of the Navy, Department of Defense, or the United States Government. The authors are military service members, and this work was prepared as part of their official duties. Title 17 U.S.C. 105 provides that "Copyright protection under this title is not available for any work of the United States Government." Title 17 U.S.C. 101 defines a United States Government work as a work prepared by a military service member or employee of the United States Government as part of that person's official duties.

doi:10.3949/ccjm.84a.16003

the addition of flashing lights and images.

Her medical history included a cystic mass in the right occipital lobe that had been found incidentally on magnetic resonance imaging (MRI) during a workup for pituitary adenoma. The mass was thought to be a congenital lesion or arachnoid cyst, and intermittent screening had been recommended.

The patient had grown up in Honduras and had lived in the jungle until age 12, when she moved to the United States.

■ EVALUATION AND MANAGEMENT

Physical examination was remarkable for partial visual field loss in the periphery of the left temporal quadrant in both eyes (partial hom-

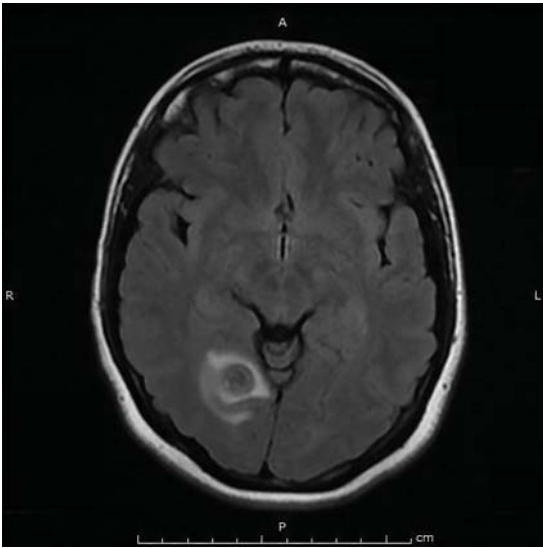


FIGURE 2. Magnetic resonance imaging 2 months later showed partial resolution of the cystic lesion within the right occipital lobe.

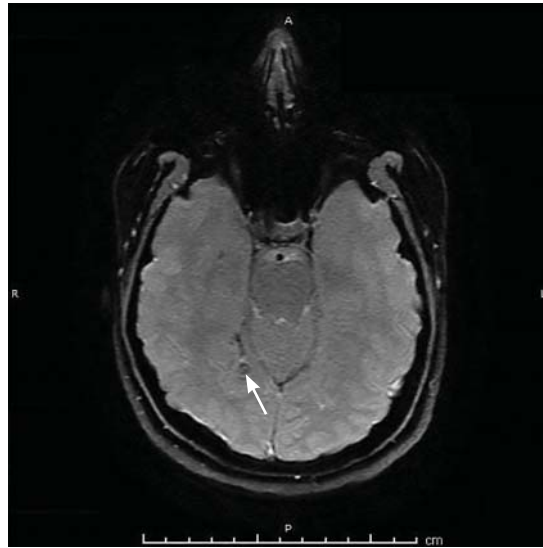


FIGURE 3. Susceptibility-weighted magnetic resonance imaging 3 years later for a flare in migraines showed a healed, indolent, right-occipital neurocysticercotic lesion and no evidence of an active process.

onymous hemianopia). Repeat MRI showed a cystic lesion with scolex (the anterior end of a tapeworm) in the right occipital lobe, with surrounding edema (**Figure 1**).

Cystic brain lesions are associated with arachnoid cyst, glioma, and malignancy, but the presence of the scolex placed neurocysticercosis as the leading diagnosis. Testing for cysticercus antibody was negative. This test was done in the hope of confirming our high suspicion; while a negative test result does not exclude this diagnosis, a positive test would have been helpful to corroborate what we suspected. However, her imaging and clinical features were sufficient to warrant treating her for neurocysticercosis.

She was treated with albendazole 400 mg twice a day for 10 days, and prednisone 1 mg/kg/day for 10 days followed by a taper. Because of the frequency with which neurocysticercosis causes seizures, an anti-epileptic drug is also recommended, at least until active lesions have subsided.¹ In this patient, levetiracetam 1,000 mg twice a day was prescribed for 6 months for seizure prophylaxis.

Repeat MRI 2 months later showed improvement (**Figure 2**). Her acute neurologic

signs and symptoms had resolved, but she continued to be followed for chronic migraines (**Figure 3**). She has had no seizures despite weaning from levetiracetam.

■ TAPEWORM AND MIGRAINE

Neurocysticercosis is caused by the cestode *Taenia solium*, acquired by eating undercooked pork contaminated with the cysts or eggs.¹ The oncospheres released by the eggs migrate through the host body and encyst in end organs.

Neuroimaging can show 4 stages of the cysts—vesicular with living larva, colloidal with larva degeneration, granulonodular with thickening of the cyst, and calcification.¹

For patients who have lived in or visited high-risk areas of the world such as Central America, South America, sub-Saharan Africa, India, and Asia, it is important to include neurocysticercosis in the differential diagnosis of migraine with focal deficits or migraine with an evolving quality. Encysted larvae can remain asymptomatic for years but can cause brain edema, often leading to seizures.

Serum testing for cysticercus antibody can indicate acute infection, chronic infection,

The presence of a scolex on MRI helped rule out arachnoid cyst, glioma, and malignancy

and possibly the immune response to treatment; however, serum testing has limited sensitivity in patients who have single or calcified lesions.² A negative test result does not exclude infection and is more likely to be a false negative in patients with a single or calcified lesion.

Current treatment guidelines recommend albendazole 400 mg twice daily along with dexamethasone or prednisolone to decrease the number of cysts and the development of lesional epilepsy.¹ Albendazole in combination with praziquantel 50 mg/kg/day kills more cysts than albendazole alone and should be considered in patients with more than 2 cysts.³ ■

REFERENCES

1. Baird RA, Wiebe S, Zunt JR, Halperin JJ, Gronseth G, Roos KL. Evidence-based guideline: treatment of parenchymal neurocysticercosis: report of the Guideline Development Subcommittee of the American Academy of Neurology. *Neurology* 2013; 80:1424–1429.
2. Garcia HH, Wittner M, Coyle CM, Tanowitz HB, White AC Jr. Cysticercosis. In: Guerrant RL, Walker DH, Weller PF, editors. *Tropical Infectious Diseases: Principles, Pathogens, and Practice*. Philadelphia, PA: Elsevier Churchill Livingstone; 2006:1289–1303.
3. Garcia HH, Gonzales I, Lescano AG, et al; Cysticercosis Working Group in Peru. Efficacy of combined antiparasitic therapy with praziquantel and albendazole for neurocysticercosis: a double blind, randomized controlled trial. *Lancet Infect Dis* 2014; 14:687–695.

ADDRESS: Emily Jernigan Elliott, DO, LT MC USN, Department of Internal Medicine, Naval Medical Center, 620 John Paul Jones Circle, Portsmouth, VA 23708; emily.e.jernigan.mil@mail.mil