

TIMMIE SHARMA, MD

Department of Dermatology,
University Hospitals Case Medical Center,
Cleveland, OH

ALOK VIJ, MD

Department of Dermatology,
Cleveland Clinic

APRA SOOD, MD

Head, Section of Industrial Dermatology,
Department of Dermatology,
Cleveland Clinic

Fungal folliculitis masquerading as acute exanthematous pustulosis

A 25-YEAR-OLD MAN being treated in the hospital for catatonia and flaccid paralysis developed fever and a lobar consolidation, prompting treatment with piperacillin-tazobactam. A dermatology consult was called 3 days later when the patient developed a rash on the forehead (**Figure 1**), cheeks, chin, and upper trunk, raising concern for a drug-related eruption.

Close examination of the rash revealed bright red plaques studded with sheets of monomorphic pustules. Possible causes other than drug therapy were considered, including folliculitis, acneiform eruption, and pustular psoriasis. Bacterial culture of a pustule was negative, but punch biopsy of a pustule revealed an abundance of round and oval budding yeast forms consistent with *Malassezia* (formerly called *Pityrosporum*) “stuffing” the hair follicles and forming cleared spaces in the dermis surrounded by an exuberant lymphohistiocytic infiltrate (**Figures 2 and 3**). Special stains were negative for bacteria and mycelial forms. The clinicopathologic findings were diagnostic of *Malassezia* folliculitis with formation of dermal abscesses.

The patient was treated with intravenous itraconazole 200 mg daily for 7 days and topical benzoyl peroxide 5% gel, with ketoconazole 2% cream for maintenance therapy. The treatment brought improvement of the rash.

THE DIFFERENTIAL DIAGNOSIS

The appearance of sterile pustules after starting a new antibiotic raised suspicion for acute localized exanthematous pustulosis, a variant

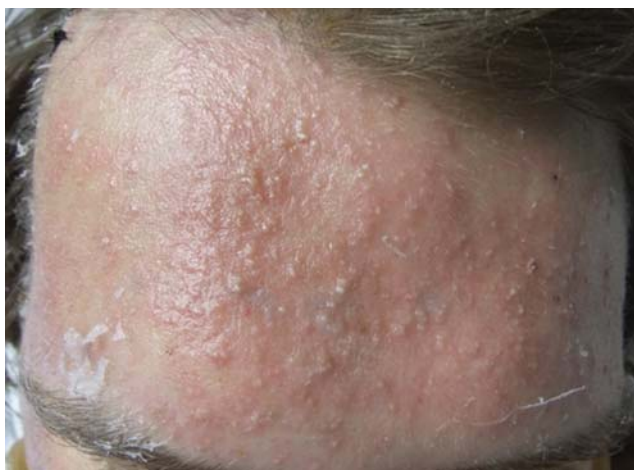

FIGURE 1. A brightly erythematous plaque on the forehead with monomorphic pustules was noted on day 3 of piperacillin-tazobactam infusion.

of acute generalized exanthematous pustulosis. It is a serious but uncommon adverse drug reaction, with a frequency of one to five cases per million per year. The eruption of erythematous plaques studded with sterile pustules classically appears 1 to 5 days after starting a drug.¹ Piperacillin-tazobactam has been infrequently reported in association with acute exanthematous pustulosis, but antibiotics in general are among the most commonly reported culprits.²⁻⁴

Clues to the correct diagnosis

Although our concern for acute localized exanthematous pustulosis was warranted, the morphology and distribution of this patient's exanthem also raised suspicion of fungal folliculitis, which is more common.

Malassezia folliculitis appears as a monomorphic papular and pustular eruption on the chest, back, and face,⁵ as in our patient. Differ-

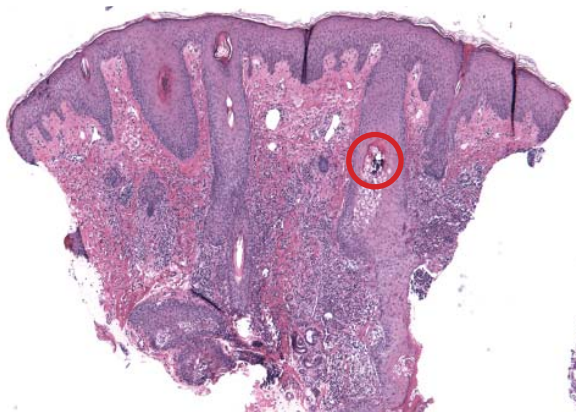


FIGURE 2. Histologic sections reveal *Malassezia* folliculitis and abscess formation within the dermis. The red circle highlights yeast forms within the follicular epithelium (hematoxylin and eosin, $\times 4$).

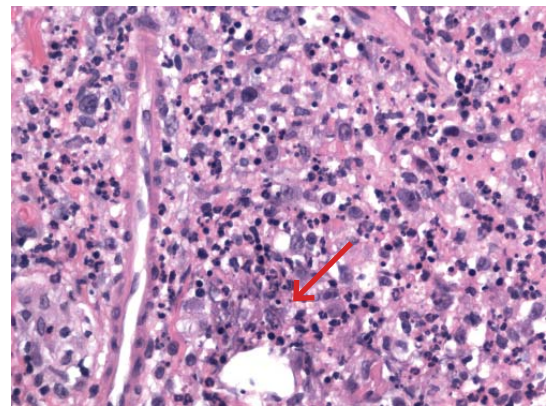


FIGURE 3. Histologic sections of a perifollicular dermal abscess show mixed inflammatory infiltrate including neutrophils and histiocytes centered on cleared-out spaces with small, grey-blue yeast forms (red arrow) (hematoxylin and eosin, $\times 100$).

entiating fungal folliculitis from pustulosis is important, as each condition is treated differently: *Malassezia* folliculitis is treated with antifungals,⁵ and acute localized exanthematous pustulosis is managed with cessation of the offending drug, supportive care, and systemic or topical steroids.⁴

Take-home point

Our experience with this patient was a reminder to consider fungal folliculitis in the differential diagnosis of a pustular eruption, so as to allow appropriate management and to avert discontinuation of potentially life-saving medications. ■

A rash that developed 3 days after starting piperacillin-tazobactam prompted concern for exanthematous pustulosis

REFERENCES

1. Fernando SL. Acute generalised exanthematous pustulosis. *Australas J Dermatol* 2012; 53:87–92.
2. Talati S, Lala M, Kapupara H, Thet Z. Acute generalized exanthematous pustulosis: a rare clinical entity with use of piperacillin/tazobactam. *Am J Ther* 2009; 16:591–592.
3. Sidoroff A, Dunant A, Viboud C, et al. Risk factors for acute generalized exanthematous pustulosis (AGEP)—results of a multinational case-control study (EuroSCAR). *Br J Dermatol* 2007; 157:989–996.
4. Huilaja L, Kallioinen M, Soronen M, Riekk R, Tasanen K. Acute localized exanthematous pustulosis on inguinal area secondary to piperacillin/tazobactam. *Acta Derm Venereol* 2014; 94:106–107.
5. Rubenstein RM, Malerich SA. *Malassezia* (pityrosporum) folliculitis. *J Clin Aesthet Dermatol* 2014; 73:37–41.

ADDRESS: Alok Vij, MD, Department of Dermatology, A61, Cleveland Clinic, 9500 Euclid Avenue, Cleveland, OH 44195; e-mail: vija@ccf.org