

Concurrent uvulitis and epiglottitis

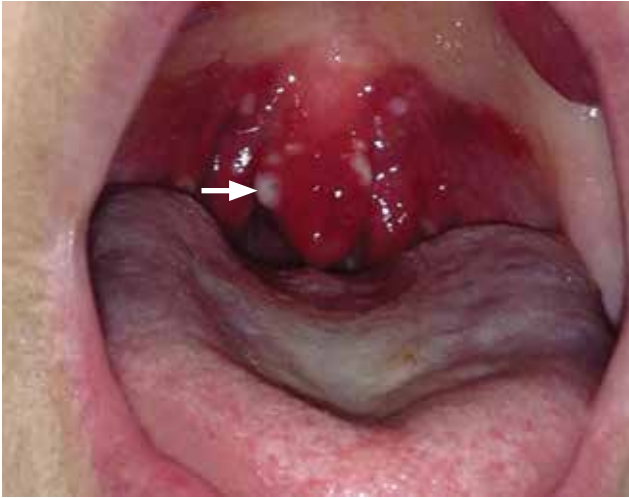

FIGURE 1. The uvula was swollen and red, with exudate (arrow).

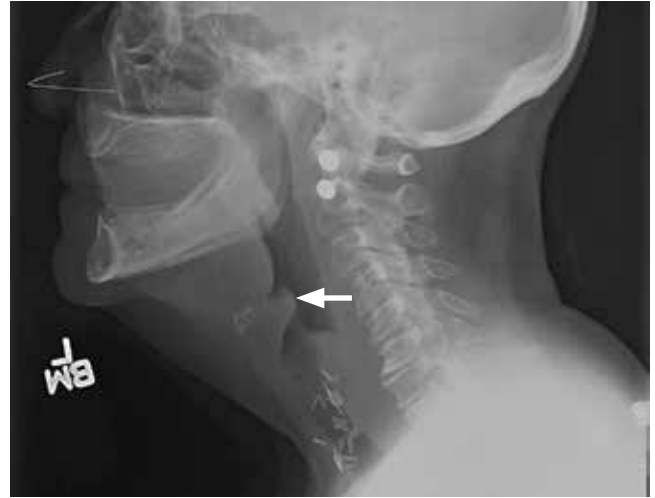


FIGURE 2. The lateral radiograph showed minimal thickening of the epiglottis (arrow).

Lateral neck radiography to look for an enlarged epiglottis is recommended, given the risk of respiratory obstruction if epiglottitis is missed

A 66-YEAR-OLD WOMAN presented with fever, cough, odynophagia, and anterior neck pain.

Examination of the oral cavity showed a swollen, erythematous uvula with exudate consistent with uvulitis (**Figure 1**). A lateral radiograph of the neck showed minimal thickening of the epiglottis (**Figure 2**). Fiberoptic laryngoscopy showed ulcerations along the base of the tongue, epiglottis, and aryepiglottic folds.

Intravenous antibiotics (ceftriaxone and vancomycin), intravenous corticosteroids, and acyclovir were started empirically, and the patient was admitted to the intensive care unit for observation of her respiratory status.

Results of rapid testing for group A streptococci were negative. Routine throat cultures were positive for group G beta-hemolytic streptococci. Viral throat cultures were negative for herpes simplex virus and cytomegalovirus. Multiplex polymerase chain reaction testing of

a nasopharyngeal specimen was negative for a variety of respiratory viral pathogens. No organisms were identified on blood cultures.

Her fever and symptoms resolved. She was discharged home on an oral course of amoxicillin-clavulanic acid and acyclovir. Acyclovir was given based on the ulcerative lesions suggestive of herpetic infection. No recurrence was reported.

■ KEY FEATURES AND MANAGEMENT

Uvulitis is an uncommon infection, usually caused by *Streptococcus pyogenes*, *S pneumoniae*, or *Haemophilus influenzae*.¹⁻³ It can be an isolated finding or associated with concurrent pharyngitis and epiglottitis.¹⁻³

Uvulitis and epiglottitis can have similar presenting symptoms such as fever, sore throat, and odynophagia. Lateral neck radiography looking for an enlarged epiglottis (“thumb” sign) is recommended, given the similarities in presentation to uvulitis and the seriousness of epiglottitis if missed. If there are signs

doi:10.3949/ccjm.83a.15078

of airway obstruction, laryngoscopy should be performed in a controlled setting such as the intensive care unit, as it may precipitate sudden airway obstruction.

Close observation in the intensive care unit is recommended in adults presenting with epiglottitis because of the risk of rapid dete-

rioration and the need to secure the airway. Empirical therapy with intravenous antibiotics (eg, a third-generation cephalosporin or a beta-lactamase inhibitor combination) to cover the common pathogens mentioned above is recommended and should then be tailored according to the results of blood culture testing. ■

■ REFERENCES

1. **Kotloff KL, Wald ER.** Uvulitis in children. *Pediatr Infect Dis* 1983; 2:392–393.
2. **Westerman EL, Hutton JP.** Acute uvulitis associated with epiglottitis. *Arch Otolaryngol Head Neck Surg* 1986; 112:448–449.

3. **Rapkin RH.** Simultaneous uvulitis and epiglottitis. *JAMA* 1980; 243:1843.

ADDRESS: William Shomali, MD, Medicine Institute, NA10, Cleveland Clinic, 9500 Euclid Avenue, Cleveland, OH 44195; willshomali@gmail.com