

OMER IBRAHIM, MD
Department of Dermatology,
Cleveland Clinic

LINDA AMAH, MD
Department of Internal Medicine,
Cleveland Clinic

SHARON E. MACE, MD, FACEP, FAAP
Professor of Medicine, Cleveland Clinic Lerner College
of Medicine of Case Western University, Cleveland, OH;
Director of Research and Director of Observation Unit,
Emergency Services Institute, Cleveland Clinic; Faculty,
Emergency Medicine Residency Program, MetroHealth
Medical Center/Cleveland Clinic, Cleveland, OH

Corneal opacities in a man with chronic kidney disease

A 40-YEAR-OLD MAN with end-stage renal disease on intermittent hemodialysis presented to the emergency department with a 1-week history of pain affecting his left lower back, left flank, and left lower abdomen, diagnosed as zoster prodrome.

Of note, both corneas were cloudy, most severely in the limbus (**FIGURE 1**). His visual acuity and findings on fundusoscopic examination were normal.

CORNEAL OPACITY

The finding of corneal opacity should prompt an immediate ophthalmologic evaluation by the internist as well as an ophthalmologist. The initial examination should include visual acuity testing; gross examination with the naked eye; penlight examination of the pupil, conjunctiva, and anterior chamber; fundusoscopic examination to at least confirm a red reflex; and fluorescein examination of the cornea. Fluorescein testing is done last, as the dye may interfere with the other initial tests.¹

A number of causes of opacity

A number of conditions can cause corneal opacity. Several genetic conditions can cause developmental anomalies of the cornea, leading to corneal defects present at birth.² Causes of secondary corneal opacity in early infancy include infections such as herpes, iatrogenic injury during amniocentesis or forceps delivery, and infantile congenital glaucoma.²

Later in life, causes of corneal opacity include cataract, glaucoma, chemical exposure, foreign body injury, irradiation, infection (eg, syphilis, herpes, chlamydia), endophthalmitis, and metabolic genetic disorders such as Fabry disease, trisomy 18 syndrome, and lecithin-cholesterol acyltransferase (LCAT) deficiency.³

LCAT DEFICIENCY

LCAT is a key protein in reverse transport of cholesterol from the systemic circulation to the liver for ex-

doi:10.3949/ccjm.82a.14080

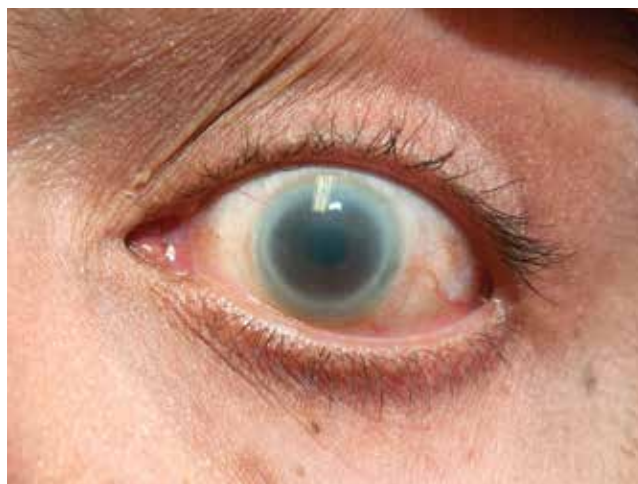


FIGURE 1. Marked corneal opacification, noted in both eyes, was most severe in the limbus.

cretion into the bile. Its deficiency results in low serum concentrations of high-density lipoprotein cholesterol (HDL-C).⁴ About 80 different mutations in the *LCAT* gene have been linked to LCAT deficiency.⁵

LCAT deficiency varies in severity. Patients with complete deficiency can have nearly undetectable levels of HDL-C, eruptive xanthoma, hepatosplenomegaly, and premature coronary artery disease (ie, by age 40).^{5,6} Features of coronary atherosclerosis can be lacking in patients with partial deficiency.

Regardless of the degree of LCAT deficiency, most patients have corneal opacification that is most severe near the limbus (thus, the term “fish eye syndrome”) and anemia.⁷ Although corneal opacification presents early in life and persists, it does not seem to affect vision.⁵ The anemia is associated with enhanced fractional clearance of red blood cells secondary to hypersplenism.⁸

LCAT deficiency and the kidneys

LCAT deficiency has its most devastating effect on the kidney. Renal disease begins early in life with mild

proteinuria and microscopic hematuria. With increasing age, renal function deteriorates and proteinuria and hematuria worsen.⁹

Renal biopsy study may reveal foam cells in the glomerular tufts, arterioles with thickened intima and narrowed lumens, and subendothelial deposits of lipids in the renal arteries and arterioles.¹⁰ Some studies have suggested that kidney disease is most likely initiated by lipid deposition or cellular uptake of lipoproteins in the glomerular basement membrane, mesangium, and capillary subendothelium.

Treatment

There are few treatment options for patients with LCAT deficiency. Control of hypertension, if present, may halt or slow renal deterioration.⁵ Many patients eventually require dialysis, and some undergo renal transplantation, but the renal disease can recur.

REFERENCES

1. Knox KA, McIntee J. Nurse management of corneal abrasion. *Br J Nurs* 1995; 4:440–460.
2. Nischal KK. Congenital corneal opacities—a surgical approach to nomenclature and classification. *Eye (Lond)* 2007; 21:1326–1337.
3. Chiapella AP, Rosenthal AR. One year in an eye casualty clinic. *Br J Ophthalmol* 1985; 69:865–870.
4. Rosenson RS, Brewer HB Jr, Davidson WS, et al. Cholesterol efflux and atheroprotection: advancing the concept of reverse cholesterol transport. *Circulation* 2012; 125:1905–1919.
5. Roshan B, Ganda OP, Desilva R, et al. Homozygous lecithin:cholesterol acyltransferase (LCAT) deficiency due to a new loss of function mutation and review of the literature. *J Clin Lipidol* 2011; 5:493–499.
6. Kuivenhoven JA, van Voorst tot Voorst EJ, Wiebusch H, et al. A unique genetic and biochemical presentation of

OUR PATIENT

Our patient had a known diagnosis of LCAT deficiency. Five years before this presentation at our emergency department, he developed malignant hypertension, followed shortly by renal disease. Over the next 4 years, his kidney function deteriorated, culminating in the need for dialysis; his corneal opacities manifested and gradually worsened; and after extensive studies including kidney biopsies, he was finally diagnosed with LCAT deficiency.

He also exhibited a chronically low level of HDL-C (2 to 5 mg/dL) and significant coronary artery disease. Although unrelated, his zoster pain was treated with renally dosed acyclovir and gabapentin. He never demonstrated the characteristic rash, and his pain improved significantly within 5 days of treatment.

fish-eye disease. *J Clin Invest* 1995; 96:2783–2791.

7. Palmiero PM, Sbeity Z, Liebmann J, Ritch R. In vivo imaging of the cornea in a patient with lecithin-cholesterol acyltransferase deficiency. *Cornea* 2009; 28:1061–1064.
8. Norum KR, Gjone E. Familial serum-cholesterol esterification failure. A new inborn error of metabolism. *Biochim Biophys Acta* 1967; 144:698–700.
9. Gjone E, Norum KR. Familial serum cholesterol ester deficiency. Clinical study of a patient with a new syndrome. *Acta Med Scand* 1968; 183:107–112.
10. Lager DJ, Rosenberg BF, Shapiro H, Bernstein J. Lecithin cholesterol acyltransferase deficiency: ultrastructural examination of sequential renal biopsies. *Mod Pathol* 1991; 4:331–335.

ADDRESS: Omer Ibrahim, MD, Department of Dermatology, A61, Cleveland Clinic, 9500 Euclid Avenue, Cleveland, OH 44195; e-mail: ibrahio@ccf.org

Effects of
LCAT deficiency
include
low HDL-C,
renal disease,
anemia, and
corneal opacity