

THE CLINICAL PICTURE

M. CHADI ALRAIES, MD

Clinical Assistant Professor of Medicine, Cleveland Clinic Lerner College of Medicine of Case Western Reserve University, Cleveland, OH, Department of Hospital Medicine, Cleveland Clinic

WAEEL ALJAROUDI, MD

Department of Cardiovascular Medicine, Heart and Vascular Institute, Cleveland Clinic

USMAN AYUB KHAN, MBBS

Department of Hospital Medicine, Cleveland Clinic

ABDUL HAMID ALRAIYES, MD

Respiratory Institute, Cleveland Clinic

The Clinical Picture

Deep T waves and chest pain

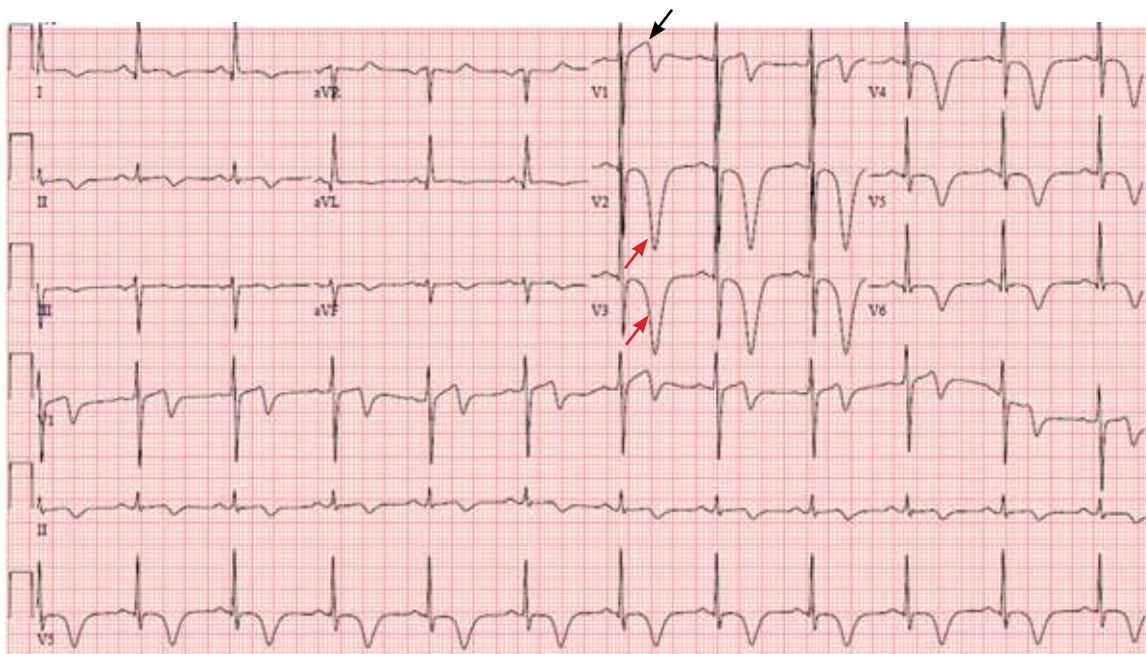


FIGURE 1. The patient's electrocardiogram on admission. Note the T-wave inversions in precordial leads V_2 and V_3 (red arrows) and ST-segment changes in V_1 (black arrow).

A 67-YEAR-OLD MAN with a history of hypertension and hyperlipidemia presented to the emergency department after 3 hours of what he described as a burning sensation in his chest that woke him from sleep. He attributed it at first to a late-night meal and treated himself with some milk and yogurt, which seemed to relieve the symptoms. However, the pain recurred and was associated with difficulty breathing. At that point, he drove himself to the emergency department.

On arrival, his temperature was 36.5°C (97.7°F), blood pressure 134/67 mm Hg, heart rate 89 bpm, respirations 18/min, and oxygen saturation 98% on room air. His cardiovascular, lung, and neurologic examina-

tions were normal. His cardiac enzyme levels (creatinine kinase, creatine kinase MB fraction, and troponin T) were within normal limits.

FIGURE 1 depicts his initial electrocardiogram. It showed deep, symmetric T-wave inversions in the precordial leads especially in V_2 and V_3 , changes known as Wellens syndrome. The ST-T changes in lead V_1 suggested a very proximal lesion in the left anterior descending artery (LAD), before the first septal perforator. Also, lateral and high lateral (V_5 and V_6) findings indicated stenoses of the branching diagonals and left circumflex myocardial territory. Furthermore, the inferior ST-T changes indicated that his LAD may have wrapped around the cardiac apex. All of these findings were prognostically significant.

doi:10.3949/ccjm.81a.12176

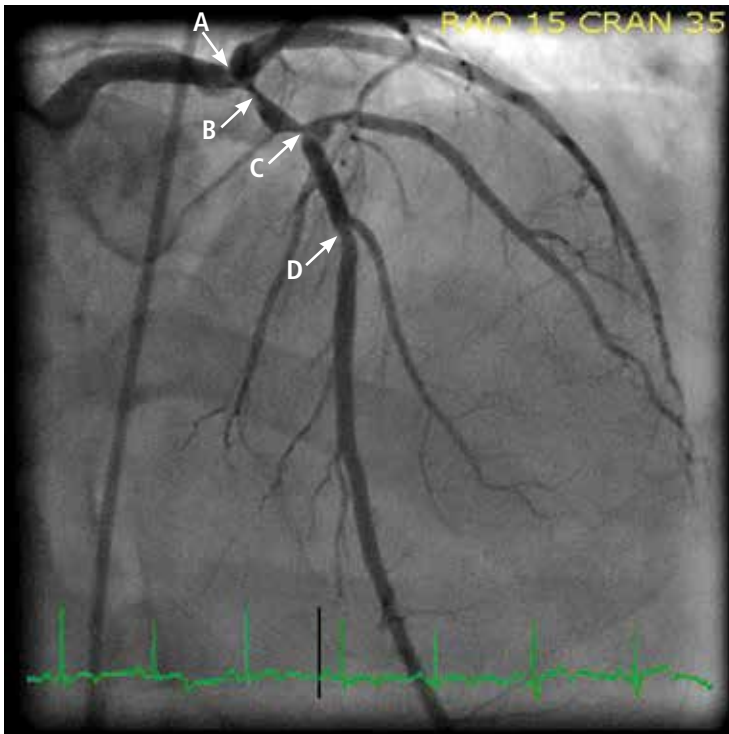


FIGURE 2. Coronary angiography showed intraluminal disease, with 50% to 60% stenosis of the left main coronary artery (A), 90% stenosis in the proximal left anterior descending artery (B), 80% stenosis in the middle segment of the left anterior descending artery (C), and 40% stenosis in a large (> 3.0-mm) second diagonal artery (D).

The patient was given aspirin and was started on intravenous unfractionated heparin and nitroglycerin. He was sent for urgent left-heart catheterization, which showed a 50% to 60% stenosis in the left main coronary artery, with involvement of the left circumflex artery proximally, in addition to a “tight” first-diagonal stenosis, a 90% stenosis in a large (> 3.0-mm) proximal segment of the LAD, an 80% stenosis in a large (> 3.0-mm) mid-LAD segment, and a 40% stenosis in a large (> 3.0-mm) second diagonal artery (FIGURE 2).

He was referred for cardiac surgery and underwent triple coronary artery bypass grafting: the left internal thoracic artery was grafted to the LAD, a reverse saphenous vein graft was performed to the diagonal artery, and a reverse

saphenous vein graft was performed to the obtuse marginal artery.

A PRECURSOR TO INFARCTION

Wellens et al described specific precordial T-wave changes in patients with unstable angina who subsequently developed anterior wall myocardial infarction.¹

The importance of Wellens syndrome is that it occurs in the pain-free interval when no other evidence of ischemia or angina may be present.¹ Cardiac enzyme levels are typically normal or only minimally elevated; only 12% of patients with this syndrome have elevated cardiac biomarker levels.²

Given the extent of myocardial injury, urgent echocardiography can show a wall-motion abnormality even if cardiac enzyme levels are normal. This gives important insight into electrocardiographic changes and should prompt consideration of revascularization.

Even with extensive medical management, Wellens syndrome progresses to acute anterior wall ischemia. About 75% of patients with Wellens syndrome who receive medical management but do not undergo revascularization (eg, coronary artery bypass grafting, percutaneous coronary intervention) develop extensive anterior wall infarction within days.^{1,3} Despite negative cardiac biomarkers, Wellens syndrome is considered an acute coronary syndrome requiring urgent cardiac intervention. ■

REFERENCES

1. Movahed MR. Wellens' syndrome or inverted U-waves? *Clin Cardiol* 2008; 31:133–134.
2. de Zwaan C, Bär FW, Janssen JH, et al. Angiographic and clinical characteristics of patients with unstable angina showing an ECG pattern indicating critical narrowing of the proximal LAD coronary artery. *Am Heart J* 1989; 117:657–665.
3. de Zwaan C, Bär FW, Wellens HJ. Characteristic electrocardiographic pattern indicating a critical stenosis high in left anterior descending coronary artery in patients admitted because of impending myocardial infarction. *Am Heart J* 1982; 103:730–736.

ADDRESS: M. Chadi Alraies, MD, Department of Hospital Medicine, A13, Cleveland Clinic, 9500 Euclid Avenue, Cleveland, OH 44195; e-mail: alraies@hotmail.com