

## THE CLINICAL PICTURE

**ERIC J. CHAN, MD**

Rogan and O'Brien Cardiovascular  
Associates, Annandale, VA

**VIJAIGANESH NAGARAJAN, MD, MRCP, FACP**

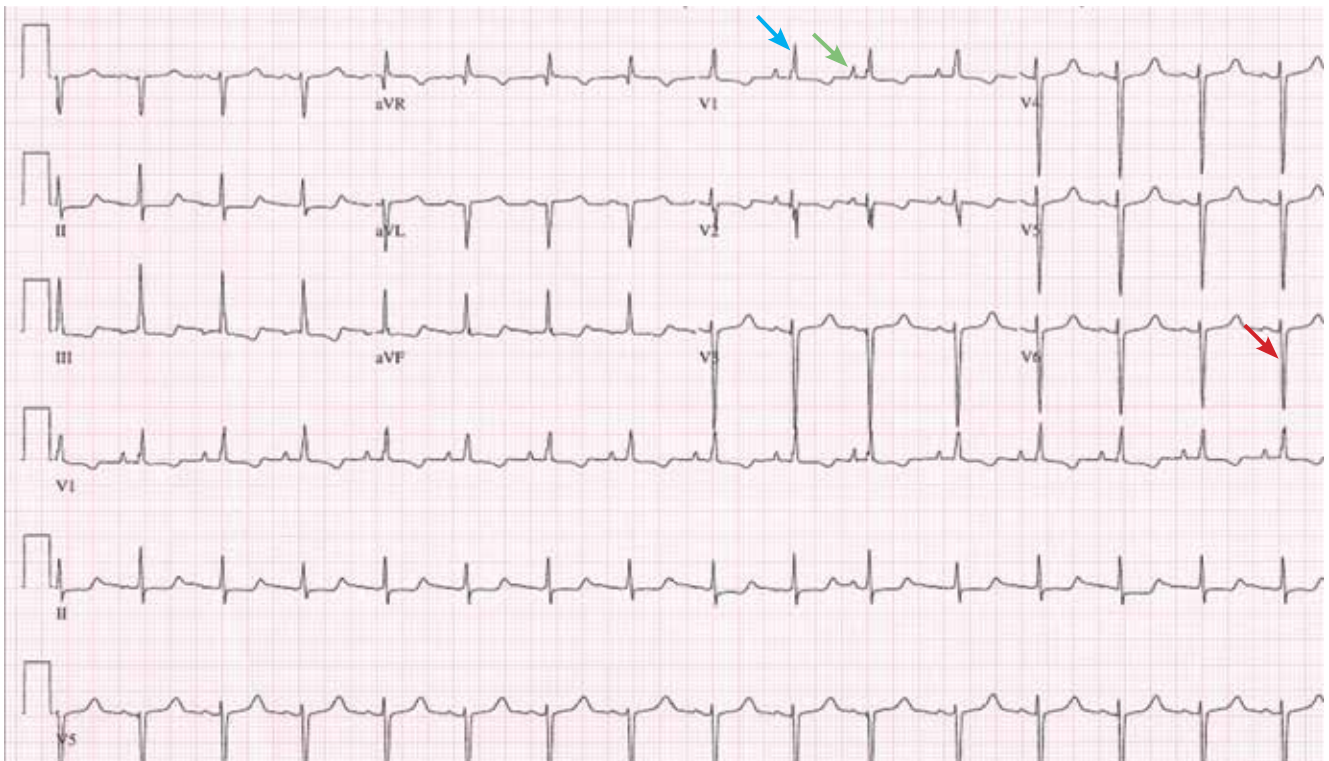
Department of Hospital Medicine, Cleveland Clinic,  
Cleveland, OH

**DONALD A. UNDERWOOD, MD**

Department of Cardiovascular Medicine,  
Cleveland Clinic, Cleveland, OH

# The Clinical Picture

## Implications of a prominent R wave in V<sub>1</sub>



**FIGURE 1.** The patient's 12-lead electrocardiogram shows sinus rhythm with a rate of 95 beats per minute. There is right axis deviation. There are prominent initial P waves in V<sub>1</sub>, suggesting a right atrial abnormality (green arrow). There are also pure R waves of amplitude > 5 mm with down-sloping ST depression and asymmetric T-wave inversion in V<sub>1</sub>, suggesting right ventricular hypertrophy and secondary T wave changes (blue arrow). The S waves in V<sub>6</sub> are greater than 15 mm in depth (red arrow).

**A** 19-YEAR-OLD WOMAN with no significant cardiac or pulmonary history presented with exertional dyspnea, which had begun a few months earlier. Auscultation revealed a loud pulmonary component of the second heart sound and a diastolic murmur heard along the upper left sternal border. Her 12-lead electrocardiogram is shown in **FIGURE 1**.

**Q:** Which of the following can cause prominent R waves in lead V<sub>1</sub>?

- ☐ Normal variant in young adults
- ☐ Wolff-Parkinson-White syndrome
- ☐ Posterior wall myocardial infarction
- ☐ Right ventricular hypertrophy
- ☐ All of the above

**A:** The correct answer is all of the above.

The patient's electrocardiogram shows a right atrial abnormality and right ventricular hypertrophy. Right atrial enlargement is evidenced by a prominent initial P wave in  $V_1$  with an amplitude of at least 1.5 mm (0.15 mV). A P wave taller than 2.5 mm (0.25 mV) in lead II may also suggest a right atrial abnormality.<sup>1</sup>

Multiple criteria exist for the diagnosis of right ventricular hypertrophy. Tall R waves in  $V_1$  with an R/S ratio greater than 1 (ie, the R wave amplitude is more than the S wave depth) is commonly used.<sup>2</sup> Deep S waves with an R/S ratio less than 1 in  $V_6$  is another criterion. Tall R waves of amplitude greater than 7 mm in  $V_1$  by themselves may represent right ventricular hypertrophy. Most of the electrocardiographic criteria are specific but not sensitive for this diagnosis.<sup>3</sup>

Other causes of tall R waves in  $V_1$  are given in TABLE 1.

**Q:** Which of the following diseases can present with an electrocardiographic pattern of right ventricular hypertrophy in young patients?

- ☐ Pulmonary hypertension
- ☐ Atrial septal defect
- ☐ Tetralogy of Fallot
- ☐ Pulmonary stenosis
- ☐ All of the above

**A:** The correct answer is all of the above.<sup>4</sup>

Our patient underwent multiple investigations. On echocardiography, her estimated right ventricular pressure was 80 mm Hg, and on cardiac catheterization her mean pulmonary arterial pressure was 55 mm Hg and her pulmonary capillary wedge pressure was 6 mm Hg. She was diagnosed with pulmonary arterial hypertension, which was the cause of her right ventricular hypertrophy. She eventually underwent bilateral lung transplantation. ■

TABLE 1

### Differential diagnosis of tall R waves in lead $V_1$

Normal variant in children and young adults  
Right bundle branch block  
Posterior myocardial infarction  
Dextrocardia  
Type A Wolff-Parkinson-White syndrome  
Hypertrophic cardiomyopathy  
Duchenne muscular dystrophy  
Right ventricular hypertrophy

ADAPTED FROM MATTU A, BRADY WJ, PERRSON AD, ROBINSON DA. PROMINENT R WAVE IN LEAD  $V_1$ : ELECTROCARDIOGRAPHIC DIFFERENTIAL DIAGNOSIS. AM J EMERG MED 2001; 19:504-513, COPYRIGHT 2001, WITH PERMISSION FROM ELSEVIER, WWW.SCIENCEDIRECT.COM/SCIENCE/JOURNAL/ 07356757.

### REFERENCES

1. Hancock EW, Deal BJ, Mirvis DM, et al; American Heart Association Electrocardiography and Arrhythmias Committee, Council on Clinical Cardiology; American College of Cardiology Foundation; Heart Rhythm Society. AHA/ACCF/HRS recommendations for the standardization and interpretation of the electrocardiogram: part V: electrocardiogram changes associated with cardiac chamber hypertrophy: a scientific statement from the American Heart Association Electrocardiography and Arrhythmias Committee, Council on Clinical Cardiology; the American College of Cardiology Foundation; and the Heart Rhythm Society: endorsed by the International Society for Computerized Electrocardiology. *Circulation* 2009; 119:e251-e261.
2. Milnor WR. Electrocardiogram and vectorcardiogram in right ventricular hypertrophy and right bundle-branch block. *Circulation* 1957; 16:348-367.
3. Lehtonen J, Sutinen S, Ikäheimo M, Pääkkö P. Electrocardiographic criteria for the diagnosis of right ventricular hypertrophy verified at autopsy. *Chest* 1988; 93:839-842.
4. Webb G, Gatzoulis MA. Atrial septal defects in the adult: recent progress and overview. *Circulation* 2006; 114:1645-1653.

**ADDRESS:** Vijaiganesh Nagarajan, MD, MRCP, Department of Hospital Medicine, M2 Annex, Cleveland Clinic, 9500 Euclid Avenue, Cleveland, OH 44195; e-mail: doctorvija@yahoo.co.uk.