

The Clinical Picture

It's all in the P wave

A 49-YEAR-OLD MAN with rheumatic mitral valve stenosis, which had been diagnosed 3 years previously, presented to the outpatient department with worsening exertional dyspnea, fatigue, and cough.

At rest, he appeared comfortable; his pulse rate was 94 bpm and his blood pressure was 117/82 mm Hg. Cardiac auscultation revealed a loud first heart sound, a mid-diastolic murmur with presystolic accentuation at the cardiac apex, and a pansystolic murmur at the left lower sternal border that increased in intensity with inspiration. A prominent left parasternal heave was present.

His 12-lead electrocardiogram is shown in **FIGURE 1**.

Transthoracic echocardiography confirmed severe mitral stenosis with an estimated mitral valve area of 0.7 cm² without significant mitral regurgitation. In addition, right ventricular dilatation with moderately severe systolic dysfunction and 4+ (severe) tricuspid regurgitation were present. On the basis of the peak tricuspid regurgitant velocity, the right ventricular systolic pressure was calculated to be 80 mm Hg, consistent with severe pulmonary hypertension. The left ventricular end-diastolic volume was reduced and the ejection fraction was normal.

On right heart catheterization, the pulmonary artery pressure was 92/51 mm Hg.

Q: Electrocardiographic findings that support a diagnosis of pulmonary hypertension include which of the following?

- ☐ QRS complex axis of +110°
- ☐ R/S (QRS complex) ratio greater than 1 in lead V₁
- ☐ Sum of the amplitudes of the R wave in lead V₁ and the S wave in lead V₆ greater than 1.0 mV
- ☐ All of the above

A: The correct answer is all of the above. Regardless of the cause, patients with long-standing pulmonary hypertension possess varying degrees of right ventricular hypertrophy that may be accompanied by right ventricular enlargement and systolic dysfunction. A QRS complex axis of 110° or more, an R/S (QRS complex) ratio greater than 1 in lead V₁, and the sum of the amplitudes of the R wave in lead V₁ and the S wave in lead V₆ greater than 1.0 mV all support right ventricular hypertrophy.¹

As noted in this electrocardiogram, T-wave inversion in leads V₁ and V₂ supports a right ventricular repolarization abnormality secondary to the hypertrophy.²

Q: Important electrocardiographic findings in this patient that support secondary pulmonary hypertension due to mitral stenosis include which of the following?

- ☐ Tall peaked P waves in lead II of at least 0.25 mV and positive P waves in V₁ greater than 0.15 mV
- ☐ Prolonged P waves of at least 120 ms in lead II and terminal negative P waves in V₁ greater than 40 ms
- ☐ Right ventricular hypertrophy
- ☐ All of the above

A: The correct answer is prolonged P waves of at least 120 ms in lead II and terminal negative P waves in V₁ greater than 40 ms.

Abnormal surface electrocardiographic findings reflecting atrial enlargement or slowed atrial conduction are difficult to differentiate and are best characterized as “atrial abnormalities.” On surface electrocardiography, an atrial abnormality is represented by a P wave morphology that is best studied in leads II and V₁. In lead II, a tall peaked P wave of at least 0.25 mV supports right atrial abnormality, and a prolonged P wave (≥ 120 ms) supports left atrial abnormality. In lead V₁, right

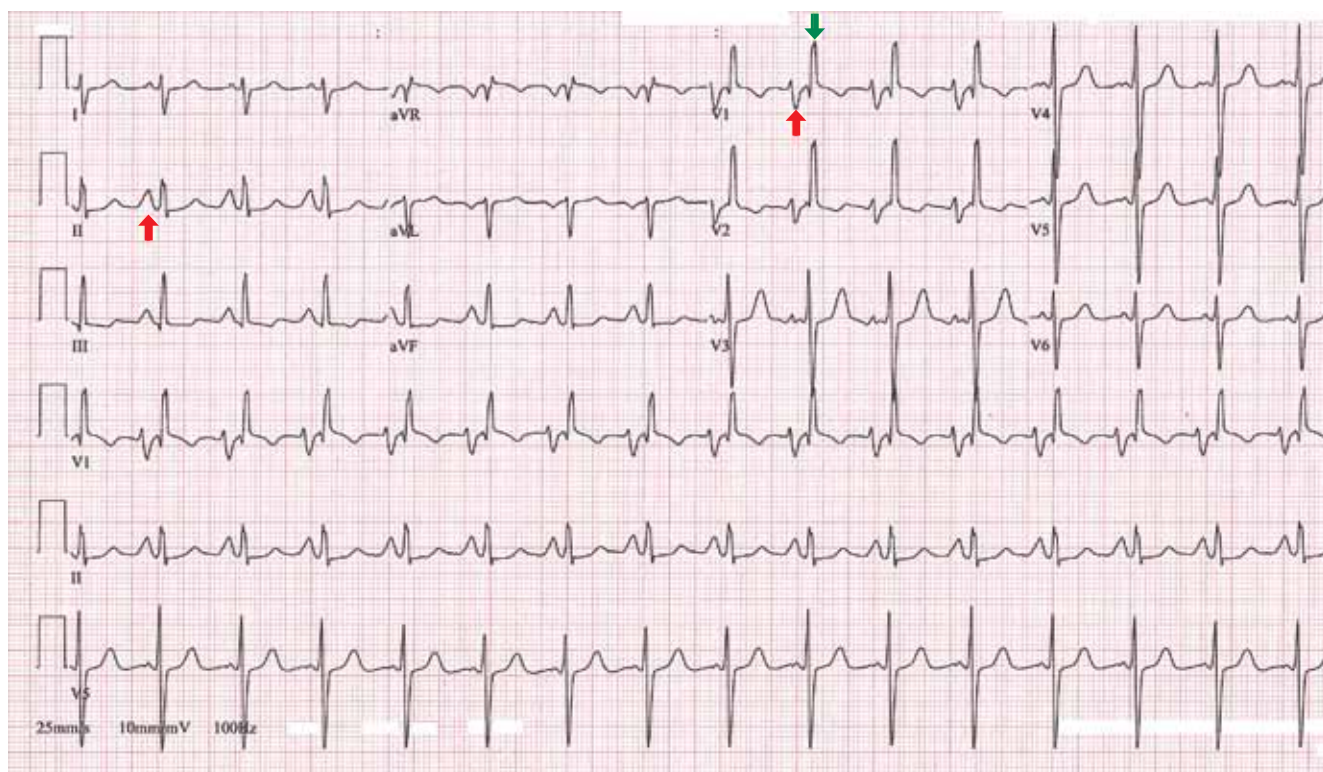


FIGURE 1. This 12-lead electrocardiogram demonstrates bi-atrial abnormality and right ventricular hypertrophy compatible with severe pulmonary hypertension in the setting of mitral stenosis. Specific findings:

Normal sinus rhythm with heart rate 94 bpm

Bi-atrial enlargement (red arrow)

Tall, peaked, and broad-based P wave in lead II (0.3 mV, 120 ms)

Positive P in lead V₁ (0.2 mV)

Negative terminal component of P in lead V₁ (0.4 mV, 60 ms)

Right ventricular hypertrophy

R/S (QRS complex) ratio >1 in lead V₁ (green arrow) with T-wave inversion in leads V₁ and V₂

Right axis QRS complex deviation (+110°)

Delayed R wave progression in leads V₁–V₆

R in lead V₁ plus S in lead V₆ = 1.9 mV

Right ventricular conduction delay

atrial abnormality is suggested by a positive P wave in V₁ greater than 0.15 mV, and a terminally negative P wave greater than 40 ms in duration and greater than 0.1 mV deep supports left atrial abnormality.³

It is well recognized that the pathophysiology of pulmonary hypertension involves both the right ventricle and the right atrium.^{4,5} Therefore, irrespective of the cause of pulmonary hypertension, electrocardiography may additionally reveal right atrial abnormality.⁶

When the findings suggest pulmonary hypertension (ie, right ventricular hypertrophy with or without right atrial abnormality), it is also important to evaluate for concurrent left atrial abnormality. If present, concomitant left atrial abnormality is a valuable, more specific clue that may help characterize secondary pulmonary hypertension from left-sided heart disease, as illustrated in this example with long-standing severe mitral stenosis.²

REFERENCES

1. **Hancock EW, Deal BJ, Mirvis DM, et al; American Heart Association Electrocardiography and Arrhythmias Committee, Council on Clinical Cardiology; American College of Cardiology Foundation; Heart Rhythm Society.** AHA/ACCF/HRS recommendations for the standardization and interpretation of the electrocardiogram: part V: electrocardiogram changes associated with cardiac chamber hypertrophy: a scientific statement from the American Heart Association Electrocardiography and Arrhythmias Committee, Council on Clinical Cardiology; the American College of Cardiology Foundation; and the Heart Rhythm Society. Endorsed by the International Society for Computerized Electrocardiology. *J Am Coll Cardiol* 2009; 53:992–1002.
2. **Goldberger AL.** Atrial and ventricular enlargement. In: *Clinical Electrocardiography: A Simplified Approach*. 7th ed. Philadelphia, PA: Mosby Elsevier; 2006:59–71.
3. **Bayés-de-Luna A, Goldwasser D, Fiol M, Bayés-Genis A.** Surface electrocardiography. In: *Hurst's The Heart*. 13th ed. New York, NY: McGraw-Hill Medical; 2011.
4. **Cioffi G, de Simone G, Mureddu G, Tarantini L, Stefanelli C.** Right atrial size and function in patients with pulmonary hypertension associated with disorders of respiratory system or hypoxemia. *Eur J Echocardiogr* 2007; 8:322–331.
5. **Raymond RJ, Hinderliter AL, Willis PW, et al.** Echocardiographic predictors of adverse outcomes in primary pulmonary hypertension. *J Am Coll Cardiol* 2002; 39:1214–1219.
6. **Al-Naamani K, Hijal T, Nguyen V, Andrew S, Nguyen T, Huynh T.** Predictive values of the electrocardiogram in diagnosing pulmonary hypertension. *Int J Cardiol* 2008; 127:214–218.

ADDRESS: Curtis Rimmerman, MD, MBA, FACC, Gus P. Karos Chair in Clinical Cardiovascular Medicine, Department of Cardiovascular Medicine, J2-4, Cleveland Clinic, 9500 Euclid Avenue, Cleveland, OH 44195; e-mail address rimmerc@ccf.org.