



**EDUCATIONAL OBJECTIVE:** Readers will be aware of an effective yet little-used treatment for recurrent *Clostridium difficile* infection

**MARKUS D. AGITO, MD**

Department of Medicine,  
Akron General Medical Center,  
Akron, OH

**ASHISH ATREJA, MD, MPH, FACP**

Director, Informatics for Research,  
Outcomes and Quality, Assistant Professor,  
Division of Gastroenterology,  
Mount Sinai School of Medicine,  
New York, NY

**MAGED K. RIZK, MD**

Quality Improvement Officer, Digestive Disease  
Institute, Cleveland Clinic; Assistant Professor,  
Cleveland Clinic Lerner College of Medicine of  
Case Western Reserve University,  
Cleveland, OH

# Fecal microbiota transplantation for recurrent *C difficile* infection: Ready for prime time?

## ABSTRACT

Recurrent *Clostridium difficile* infection has been a major challenge for patients and clinicians. Recurrence of infection after treatment with standard antibiotics is becoming more common with the emergence of more-resistant strains of *C difficile*. Fecal microbiota transplantation is an alternative treatment for recurrent *C difficile* infection, but it is not yet widely used.

## KEY POINTS

Fecal microbiota transplantation involves instilling gut microbiota from a healthy donor into the diseased gut of a patient who has recurrent or recalcitrant episodes of diarrhea despite antibiotic treatment for *C difficile* infection. The instillation can be done via nasogastric tube, endoscope, or enema.

Donor screening is necessary to prevent transmission of communicable diseases to the recipient.

Recently published studies indicate that this procedure is effective for treating recurrent *C difficile* infection. Randomized clinical trials to assess its efficacy and safety are underway.

The field of microbiota therapy is rapidly progressing. More physicians are learning to embrace the concept of fecal microbiota transplantation, and patients are beginning to overcome the “yuck factor” and accept its benefits.

**I**F YOU HAD A SERIOUS DISEASE, would you agree to an alternative treatment that was cheap, safe, and effective—but seemed disgusting? Would you recommend it to patients?

Such a disease is recurrent *Clostridium difficile* infection, and such a treatment is fecal microbiota transplantation—instillation of blenderized feces from a healthy donor (ideally, the patient’s spouse or “significant other”) into the patient’s colon to restore a healthy population of bacteria.<sup>1,2</sup> The rationale behind this procedure is simple: antibiotics and other factors disrupt the normal balance of the colonic flora, allowing *C difficile* to proliferate, but the imbalance can be corrected by reintroducing the normal flora.<sup>1</sup>

In this article, we will review how recurrent *C difficile* infection occurs and the importance of the gut microbiota in resisting colonization with this pathogen. We will also describe the protocol used for fecal microbiota transplantation.

## C DIFFICILE INFECTION OFTEN RECURS

*C difficile* is the most common cause of hospital-acquired diarrhea and an important cause of morbidity and death in hospitalized patients.<sup>3,4</sup> The cost of this infection is estimated to be more than \$1.1 billion per year and its incidence is rising, partly because of the emergence of more-virulent strains that make treatment of recurrent infection more difficult.<sup>5,6</sup>

*C difficile* infection is characterized by diarrhea associated with findings suggestive of pseudomembranous colitis or, in fulminant cases, ileus or megacolon.<sup>7</sup> Recurrent *C difficile*

TABLE 1

## CDC practice guidelines for treating *Clostridium difficile* infection

CLINICAL DEFINITION	SUPPORTIVE CLINICAL DATA	RECOMMENDED TREATMENT
<b>Initial episode, mild or moderate</b>	White blood cell (WBC) count $\leq 15,000$ cells/mL	Metronidazole 500 mg three times per day by mouth for 10–14 days
<b>Initial episode, severe</b>	WBC count $\geq 15,000$ cells/mL Serum creatinine $\geq 1.5$ times baseline	Vancomycin 125 mg four times per day by mouth for 10–14 days
<b>Initial episode, severe, complicated, or fulminant</b>	Severe <i>C difficile</i> infection complicated with hypotension, shock, ileus, or megacolon	Vancomycin 500 mg four times per day by mouth or nasogastric tube, <b>plus</b> metronidazole 500 mg every 8 hours intravenously If complete ileus, consider adding rectal instillation of vancomycin
<b>First recurrence</b>		Same as for initial episode
<b>Second recurrence</b>		Vancomycin in a tapered and/or pulsed regimen

ADAPTED FROM COHEN SH, GERDING DN, JOHNSON S, ET AL; SOCIETY FOR HEALTHCARE EPIDEMIOLOGY OF AMERICA; INFECTIOUS DISEASES SOCIETY OF AMERICA. CLINICAL PRACTICE GUIDELINES FOR *CLOSTRIDIUM DIFFICILE* INFECTION IN ADULTS: 2010 UPDATE BY THE SOCIETY FOR HEALTHCARE EPIDEMIOLOGY OF AMERICA (SHEA) AND THE INFECTIOUS DISEASES SOCIETY OF AMERICA (IDSA). INFECT CONTROL HOSP EPIDEMIOL 2010; 31:431–455. COPYRIGHT 2010, UNIVERSITY OF CHICAGO PRESS.

*C difficile* is the most common cause of hospital-acquired diarrhea and an important cause of morbidity and death

infection is defined as the return of symptoms within 8 weeks after successful treatment.<sup>7</sup>

*C difficile* produces two types of toxins. Toxin A is an enterotoxin, causing increased intestinal permeability and fluid secretion, while toxin B is a cytotoxin, causing intense colonic inflammation. People who have a poor host immune response to these toxins tend to develop more diarrhea and colonic inflammation.<sup>8</sup>

A more virulent strain of *C difficile* has emerged. Known as BI/NAP1/027, this strain is resistant to quinolones, and it also produces a binary toxin that has a partial gene deletion that allows for increased production of toxins A and B in vitro.<sup>9,10</sup> More cases of severe and recurrent *C difficile* infection have been associated with the increasing number of people infected with this hypervirulent strain.<sup>9,10</sup>

*C difficile* infection recurs in about 20% to 30% of cases after antibiotic treatment for it, usually within 30 days, and the risk of a subsequent episode doubles after two or more occurrences.<sup>10,11</sup> Metronidazole (Flagyl) and vancomycin are the primary treatments; alternative treatments include fidaxomicin (Dificid),<sup>10</sup> rifaximin (Xifaxan),<sup>12</sup> nitazoxanide,<sup>13</sup>

and tolevamer (a novel polymer that binds *C difficile* toxins).<sup>14</sup>

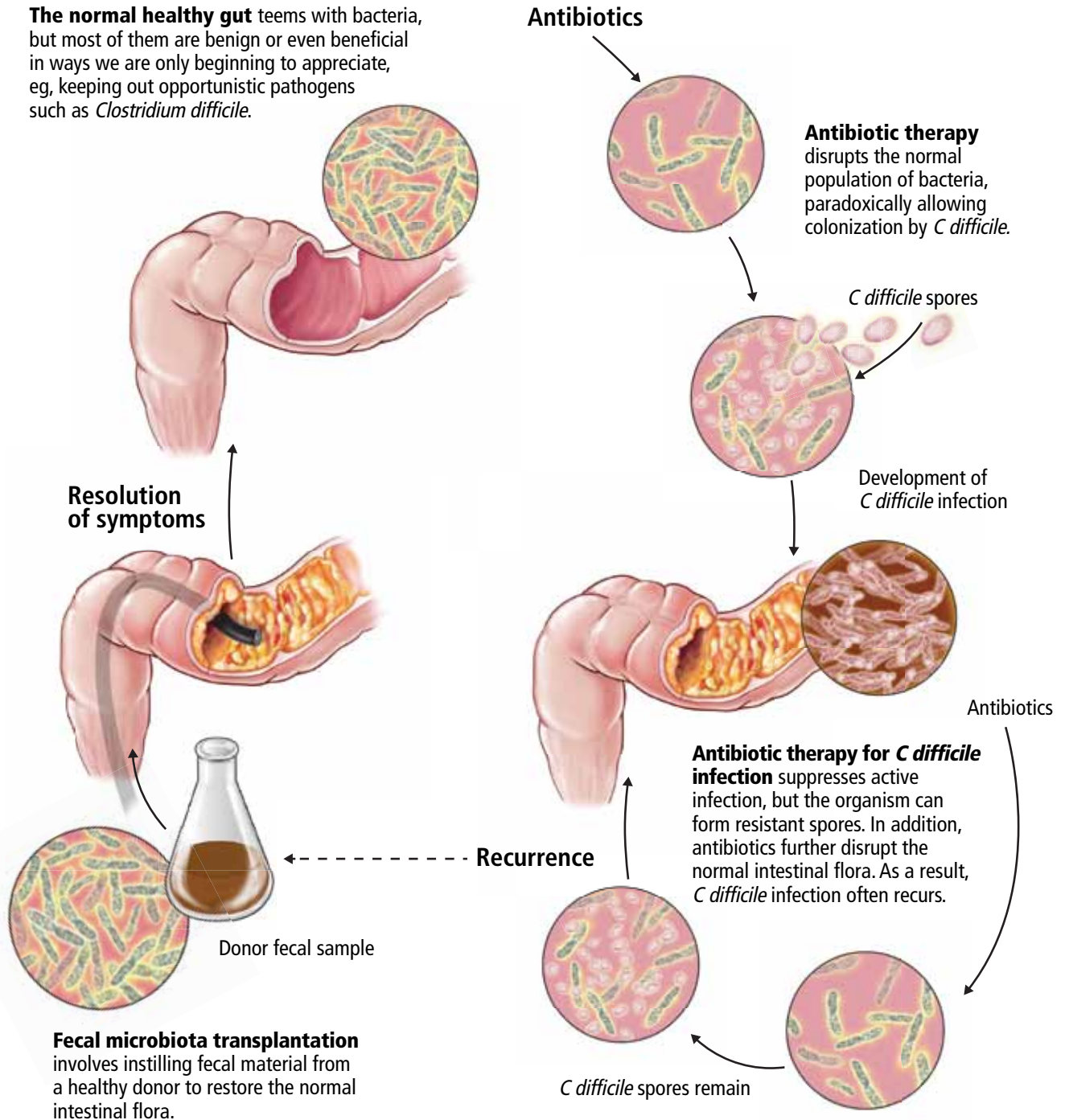
TABLE 1 summarizes the treatment regimen for *C difficile* infection in adults, based on clinical practice guidelines from the US Centers for Disease Control and Prevention (CDC).<sup>7</sup>

## THE NORMAL GUT MICROBIOTA KEEPS PATHOGENS OUT

Immediately after birth, the sterile human gut becomes colonized by a diverse community of microorganisms.<sup>15</sup> This gut microbiota performs various functions, such as synthesizing vitamin K and vitamin B complex, helping digest food, maintaining the mucosal integrity of the gut, and priming the mucosal immune response to maintain homeostasis of commensal microbiota.<sup>16</sup>

However, the most important role of the gut microbiota is “colonization resistance” or preventing exogenous or potentially pathogenic organisms from establishing a colony within the gut.<sup>17</sup> It involves competition for nutrients and occupation of binding sites on the gut epithelium by indigenous flora.<sup>16</sup> Other factors such as the mucosal barrier, salivation,

# Treating recurrent *Clostridium difficile* infection by restoring healthy intestinal flora



CCF  
Medical Illustrator: Beth Halasz ©2013

FIGURE 1

swallowing, gastric acidity, desquamation of mucosal membrane cells, intestinal motility, and secretion of antibodies also play major roles in colonization resistance.<sup>17</sup>

### ■ ANTIBIOTICS DISRUPT THE GUT FLORA

Physical or chemical injuries (the latter by antimicrobial or antineoplastic agents, eg) may disrupt the gut microbiota. In this situation, opportunistic pathogens such as *C difficile* colonize the gut mucosa, stimulate an immune reaction, and release toxins that cause diarrhea and inflammation.<sup>18</sup> *C difficile* will try to compete for nutrients and adhesion sites until it dominates the intestinal tract.

When *C difficile* spores are ingested, they replicate in the gut and eventually release toxins. Antibiotic therapy may eliminate *C difficile* bacteria but not the spores; hence, *C difficile* infection can recur after the antibiotic is discontinued unless the indigenous bacteria can restrain *C difficile* from spreading.<sup>19</sup>

### ■ HOW DOES FECAL MICROBIOTA TRANSPLANTATION WORK?

Fecal microbiota transplantation involves instilling processed stool that contains essential intestinal bacteria (eg, *Bacteroides* species) from a healthy screened donor into the diseased gastrointestinal tract of a suitable recipient (FIGURE 1).<sup>1</sup>

The aim of this procedure is to reestablish the normal composition of the gut flora, restore balance in metabolism, and stimulate both the acquired and the humoral immune responses in the intestinal mucosa after disruption of the normal flora.<sup>20–23</sup> One study showed that patients who have recurrent *C difficile* infections have fewer protective microorganisms (ie, *Firmicutes* and *Bacteroidetes*) in their gut, but after fecal microbiota transplantation their microbiota was found to be similar to that of the donor, and their symptoms promptly resolved.<sup>18</sup>

### ■ STUDIES UP TO NOW

The principle of transplanting donor stool to treat various gastrointestinal diseases has been practiced in veterinary medicine for decades

in a process known as transfaunation.<sup>24</sup> Fecal microbiota transplantation was first performed in humans in the late 1950s in patients with fulminant pseudomembranous colitis that did not respond to standard antibiotic therapy for *C difficile* infection.<sup>25</sup> Since then, a number of case reports and case series have described instillation of donor stool via nasogastric tube,<sup>26</sup> via colonoscopy,<sup>27–31</sup> and via enema.<sup>32</sup> Regardless of the protocols used, disease resolution has been shown in 92% of cases and few adverse effects have been reported, even though transmission of infectious pathogens is theoretically possible.<sup>33</sup>

A recent multicenter long-term follow-up study<sup>34</sup> showed that diarrhea resolved within 90 days after fecal microbiota transplantation in 70 (91%) of 77 patients, while resolution of *C difficile* infection after a further course of antibiotics with or without repeating fecal microbiota transplantation was seen in 76 (98%) of 77 patients.<sup>34</sup> Some patients were reported to have improvement of preexisting allergies, and a few patients developed peripheral neuropathy and autoimmune diseases such as Sjögren syndrome, idiopathic thrombocytopenic purpura, and rheumatoid arthritis.<sup>33</sup>

As the important role of the gut microbiota in resisting colonization by *C difficile* is becoming more recognized, scientists are beginning to understand and explore the additional potential benefits of fecal microbiota transplantation on other microbiota-related dysfunctions.<sup>2</sup> The Human Microbiome Project is focusing on characterizing and understanding the role of the microbial components of the human genetic and metabolic landscape in relation to human health and disease.<sup>35</sup> Earlier observational studies showed fecal microbiota transplantation to be beneficial in inflammatory bowel disease,<sup>36,37</sup> irritable bowel syndrome,<sup>38,39</sup> multiple sclerosis,<sup>40</sup> rheumatologic<sup>40</sup> and autoimmune diseases,<sup>41</sup> and metabolic syndrome,<sup>42</sup> likely owing to the role of the microbiota in immunity and energy metabolism. Although these reports may provide insight into the unexplored possibilities of fecal microbiota transplantation, further clinical investigations with randomized controlled trials are still necessary.

**Antibiotic therapy may eliminate *C difficile* bacteria but not its spores**



## THE CURRENT PROTOCOL FOR FECAL MICROBIOTA TRANSPLANTATION

As yet, there is no standardized protocol for fecal microbiota transplantation, since no completed randomized trial supporting its efficacy and safety has been published. However, a group of experts in infectious disease and gastroenterology have published a formal standard practice guideline,<sup>19</sup> as summarized below.

### Primary indications for fecal microbiota transplantation

- Recurrent *C difficile* infection—at least three episodes of mild to moderate *C difficile* infection and failure of a 6- to 8-week taper with vancomycin with or without an alternative antibiotic such as rifaximin or nitazoxanide, **or** at least two episodes of severe *C difficile* infection resulting in hospitalization and associated with significant morbidity
- Mild to moderate *C difficile* infection not responding to standard therapy for at least 1 week
- Severe or fulminant *C difficile* colitis that has not responded to standard therapy after 48 hours.

### Who is a likely donor?

The gut microbiota is continuously replenished with bacteria from the environment in which we live, and we constantly acquire organisms from people who live in that same environment. Hence, the preferred donor is someone who has intimate physical contact with the recipient.<sup>33,43,44</sup> The preferred stool donor (in order of preference) is a spouse or significant partner, a family household member, or any other healthy donor.<sup>26,36</sup>

### Who should not be a donor?

It is the responsibility of the physician performing the fecal microbiota transplantation to make sure that the possibility of transmitting disease to the recipient is minimized. Extensive history-taking and physical examination must never be omitted, since not all diseases or conditions can be detected by laboratory screening alone, especially if testing was done during the early stage or window period of a given disease.<sup>19</sup> Nevertheless, the

TABLE 2

### Exclusion criteria for donors

#### ABSOLUTE

##### Risk of infectious agent

- Known human immunodeficiency virus (HIV), hepatitis B, or hepatitis C infection
- Known exposure to HIV or viral hepatitis within the previous 12 months
- High-risk sexual behaviors
- Use of illicit drugs
- Tattoo or body piercing within 6 months
- Incarceration or history of incarceration
- Known current communicable disease (eg, upper respiratory tract infection)
- Risk factors for variant Creutzfeldt–Jakob disease
- Travel within the last 6 months to areas where diarrheal illnesses are endemic

##### Gastrointestinal comorbidities

- History of inflammatory bowel disease
- History of irritable bowel syndrome, idiopathic chronic constipation, or chronic diarrhea
- History of gastrointestinal malignancy or known polyposis

##### Factors that can or do affect the composition of the intestinal microbiota

- Antibiotics within the preceding 3 months
- Major immunosuppressive medications
- Systemic antineoplastic agents

##### Additional recipient-specific considerations

- Recent ingestion of a substance (eg, nuts) to which the recipient is allergic

#### RELATIVE

- History of major gastrointestinal surgery (eg, gastric bypass)
- Metabolic syndrome
- Systemic autoimmunity, eg, multiple sclerosis, connective tissue disease
- Atopic diseases including asthma and eczema, eosinophilic disorders of the gastrointestinal tract
- Chronic pain syndromes, eg, chronic fatigue syndrome, fibromyalgia

ADAPTED FROM INFORMATION IN BAKKEN J, BORODY T, BRANDT L, ET AL. TREATING CLOSTRIDIUM DIFFICILE INFECTION WITH FECAL MICROBIOTA TRANSPLANTATION. CLIN GASTROENTEROL HEPATOL 2011; 9:1044–1049.

donor's blood and stool should be screened for transmissible diseases such as human immunodeficiency virus (HIV), hepatitis, syphilis, enteric bacteria, parasites, and *C difficile*.

The recipient has the option to be tested for transmissible diseases such as HIV and hepatitis in order to avoid future questions about transmission after fecal microbiota transplantation. A positive screening test must always

TABLE 3

## Instructions for fecal microbiota transplantation

### Donor

Avoid intake of substances that may cause allergies to recipient  
Report any signs and symptoms of infection  
Take an osmotic laxative (milk of magnesia, lactulose) the night before transplantation

### Recipient

Stop oral vancomycin and metronidazole 3 days before transplantation  
Use bowel preparation with polyethylene glycol the night before transplantation  
Take omeprazole 20 mg on the evening before and the morning of transplantation (if by the upper-gastrointestinal route)  
Take loperamide on day of transplantation (if by the lower-gastrointestinal route)

### Stool preparation

Universal precautions (gown, gloves, mask, eye shield)  
Collection of fresh stool sample (within 6 hours)  
Homogenize sample with normal saline or 4% milk in a household blender  
Filter with gauze pads, coffee filters, or urine stone strainers  
Prepare 25–50 mL of stool suspension (upper-gastrointestinal route) or 250–500 mL (lower-gastrointestinal route)

ADAPTED FROM INFORMATION IN BAKKEN J, BORODY T, BRANDT LJ, ET AL. TREATING CLOSTRIDIUM DIFFICILE INFECTION WITH FECAL MICROBIOTA TRANSPLANTATION. CLIN GASTROENTEROL HEPATOL 2011; 9:1044–1049.

be verified with confirmatory testing.<sup>19</sup>

TABLE 2 summarizes the exclusion criteria and screening tests performed for donors according to the practice guidelines for fecal microbiota transplantation formulated by Bakken et al.<sup>19</sup>

### Preprocedure instructions and stool preparation

The physician should orient both the donor and recipient regarding “do’s and don’ts” before fecal microbiota transplantation. TABLE 3 summarizes the preprocedure instructions and steps for stool preparation.

### Route of administration

The route of administration may vary depending on the clinical situation. Upper-gastrointestinal administration is performed via nasogastric or nasojejunal tube or gastroscopy. Lower-gastrointestinal administration is performed via colonoscopy (the route of choice) or retention enema.

The upper-gastrointestinal route (nasogastric tube, jejunal catheter, or gastroscopy). The nasogastric or nasojejunal tube or gastroscopy is inserted into the upper-gastrointestinal tract, and positioning is confirmed by radiography. From 25 to 50 mL of stool suspension is drawn up in a syringe and instilled into the tubing followed by flushing with 25 mL of normal saline.<sup>26</sup> Immediately after instillation, the tube is removed and the patient is allowed to go home and continue with his or her usual diet.

This approach is easier to perform, costs less, and poses lower risk of intestinal perforation than the colonoscopic approach. Disadvantages include the possibility that stool suspension may not reach distal areas of the colon, especially in patients with ileus and small-bowel obstruction. There is also a higher risk of bacterial overgrowth in elderly patients who have lower gastric acid levels.<sup>33</sup>

The lower-gastrointestinal route (colonoscopy, retention enema). Colonoscopy is currently considered the first-line approach for fecal microbiota transplantation.<sup>45</sup> After giving informed consent, the patient undergoes standard colonoscopy under sedation. An initial colonoscopic examination is performed, and biopsy specimens are obtained if necessary. Approximately 20 mL of stool suspension is drawn up in a syringe and injected via the biopsy channel of the colonoscope every 5 to 10 cm as the scope is withdrawn, for a total volume of 250 to 500 mL.<sup>19,27</sup> The patient should be advised to refrain from defecating for 30 to 45 minutes after fecal microbiota transplantation.<sup>46</sup>

This approach allows direct visualization of the entire colon, allowing instillation of stool suspension in certain areas where *C difficile* may predominate or hide (eg, in diverticuli).<sup>27,47</sup> One disadvantage to this route of administration is the risk of colon perforation, especially if the patient has toxic colitis.

Instillation via retention enema may be done at home with a standard enema kit.<sup>32</sup> Disadvantages include the need for multiple instillations over 3 to 5 days,<sup>36</sup> back-leakage of stool suspension causing discomfort to patients, and stool suspension reaching only to the splenic flexure.<sup>48</sup>

## MEASUREMENT OF OUTCOME

Fecal microbiota transplantation is considered successful if symptoms resolve and there is no relapse within 8 weeks. Testing for *C difficile* in asymptomatic patients is not recommended since patients can be colonized with *C difficile* without necessarily developing disease.<sup>19</sup> There is currently no consensus on treatment recommendations for patients who do not respond to fecal microbiota transplantation, although some reports showed resolution of diarrhea after a repeat 2-week standard course of oral vancomycin<sup>26</sup> or repeated instillation of feces collected from new donors.<sup>49</sup>

## IS IT READY FOR PRIME TIME?

Fecal microbiota transplantation has been used primarily as an alternative treatment for recurrent *C difficile* infection, although other indications for its use are currently being identified and studied. This procedure is now being done in several specialized centers in the United States and abroad, and although the protocol may vary by institution, the clinical outcomes have been consistently promising.

The Fecal Therapy to Eliminate Associated Long-standing Diarrhea (FECAL) trial, currently underway, is the first randomized trial to assess the efficacy of fecal microbiota transplantation for treatment of recurrent *C difficile* infection.<sup>50</sup> Clinical trials such as this

one should satisfy our doubts about the efficacy of fecal microbiota transplantation and hopefully pave the way for its application in the near future.

An increasing number of patients are learning to overcome the “yuck factor” associated with fecal microbiota transplantation once they understand its safety and benefits.<sup>51</sup> Moreover, the Human Microbiome Project is attempting to identify specific organisms in stool that may specifically treat *C difficile* infection, hence eliminating the need for whole-stool transplantation in the near future. Although fecal microbiota transplantation is still in its infancy, its low cost, safety, and effectiveness in treating recurrent *C difficile* infection will likely lead to the procedure becoming widely adopted in mainstream clinical practice. ■

**Editor's note:** On January 16, 2013, after this article was completed, a randomized controlled trial of fecal microbiota transplantation was published in the *New England Journal of Medicine*. That trial, “Duodenal infusion of donor feces for recurrent *Clostridium difficile*,” found: “The infusion of donor feces was significantly more effective for the treatment of recurrent *C difficile* infection than the use of vancomycin.” The study is available online at <http://www.nejm.org/doi/full/10.1056/NEJMoa1205037> (subscription required).

## REFERENCES

1. Brandt L, Reddy S. Fecal microbiota transplantation for recurrent *Clostridium difficile* infection. *J Clin Gastroenterol* 2011; 45(suppl):S159–S167.
2. Borody TJ, Khoruts A. Fecal microbiota transplantation and emerging applications. *Nat Rev Gastroenterol Hepatol* 2011; 9:88–96.
3. Lipp MJ, Nero DC, Callahan MA. The impact of hospital-acquired *Clostridium difficile*. *J Gastroenterol Hepatol* 2012; 27:1733–1737.
4. Kyne L, Sougioultzis S, McFarland LV, Kelly CP. Underlying disease severity as a major risk factor for nosocomial *Clostridium difficile* diarrhea. *Infect Control Hosp Epidemiol* 2002; 23:653–659.
5. Kyne L, Hamel MB, Polavaram R, Kelly CP. Health care costs and mortality associated with nosocomial diarrhea due to *Clostridium difficile*. *Clin Infect Dis* 2002; 34:346–353.
6. Gorbach SL. Antibiotics and *Clostridium difficile*. *N Engl J Med* 1999; 341:1690–1691.
7. Cohen SH, Gerding DN, Johnson S, et al; Society for Healthcare Epidemiology of America; Infectious Diseases Society of America. Clinical practice guidelines for *Clostridium difficile* infection in adults: 2010 update by the Society for Healthcare Epidemiology of America (SHEA) and the Infectious Diseases Society of America (IDSA). *Infect Control Hosp Epidemiol* 2010; 31:431–455.
8. Beales IL. Intravenous immunoglobulin for recurrent *Clostridium difficile* diarrhoea. *Gut* 2002; 51:456.
9. O'Connor JR, Johnson S, Gerding DN. *Clostridium difficile* infection caused by the epidemic BI/NAP1/027 strain. *Gastroenterology* 2009; 136:1913–1924.
10. Louie TJ, Miller MA, Mullane KM, et al; OPT-80-003 Clinical Study Group. Fidaxomicin versus vancomycin for *Clostridium difficile* infection. *N Engl J Med* 2011; 364:422–431.
11. Kelly CP, LaMont JT. *Clostridium difficile*—more difficult than ever. *N Engl J Med* 2008; 359:1932–1940.
12. Johnson S, Schriever C, Galang M, Kelly CP, Gerding DN. Interruption of recurrent *Clostridium difficile*-associated diarrhea episodes by serial therapy with vancomycin and rifaximin. *Clin Infect Dis* 2007; 44:846–848.
13. Musher DM, Logan N, Hamill RJ et al. Nitazoxanide for the treatment of *Clostridium difficile* colitis. *Clin Infect Dis* 2006; 43:421–427.
14. Louie TJ, Peppe J, Watt CK, et al. Tolevamer, a novel nonantibiotic polymer, compared with vancomycin in the treatment of mild to moderately severe *Clostridium difficile*-associated diarrhea. *Clin Infect Dis* 2006; 43:411–420.
15. Reid G, Younes JA, Van der Mei HC, Gloor GB, Knight R, Busscher JH. Microbiota restoration: natural and supplemented recovery of human microbial communities. *Nat Rev Microbiol* 2011; 9:27–38.
16. Berg RD. The indigenous gastrointestinal microflora. *Trends Microbiol* 1996; 4:430–435.
17. Vollaard EJ, Clasener HA. Colonization resistance. *Antimicrob Agents Chemother* 1994; 38:409–414.

18. Khoruts A, Dicksved J, Jansson JK, Sadowsky MJ. Changes in the composition of the human fecal microbiome after bacteriotherapy for recurrent *Clostridium difficile*-associated diarrhea. *J Clin Gastroenterol* 2010; 44:354–360.
19. Bakken JS, Borody T, Brandt LJ, et al; Fecal Microbiota Transplantation Workgroup. Treating *Clostridium difficile* infection with fecal microbiota transplantation. *Clin Gastroenterol Hepatol* 2011; 9:1044–1049.
20. Zar FA, Bakkanagari SR, Moorthi KM, Davis MB. A comparison of vancomycin and metronidazole for the treatment of *Clostridium difficile*-associated diarrhea, stratified by disease severity. *Clin Infect Dis* 2007; 45:302–307.
21. McFarland LV, Surawicz CM, Greenberg RN, et al. A randomized placebo-controlled trial of *Saccharomyces boulardii* in combination with standard antibiotics for *Clostridium difficile* disease. *JAMA* 1994; 271:1913–1918.
22. Neish AS, Gewirtz AT, Rao AS, et al. Non-pathogenic bacteria may block epithelial responses: Attenuation of IKB ubiquitination as a novel, physiologic mode of antiinflammation. *Gastroenterology* 2000; 118:A3754.
23. Helwig U, Rizzello F, Cifone G, et al. Elevated IL-10 levels in pouch-tissue after probiotic therapy. *Immunol Lett*. 1999; 69:159.
24. Rager KD, George LW, House JK, DePeters EJ. Evaluation of rumen transfaunation after surgical correction of left-sided displacement of the abomasum in cows. *J Am Vet Med Assoc* 2004; 225:915–920.
25. Eiseman B, Silen W, Bascom GS, Kauvar AJ. Fecal enema as an adjunct in the treatment of pseudomembranous enterocolitis. *Surgery* 1958; 44:854–859.
26. Aas J, Gessert CE, Bakken JS. Recurrent *Clostridium difficile* colitis: case series involving 18 patients treated with donor stool administered via a nasogastric tube. *Clin Infect Dis* 2003; 36:580–585.
27. Yoon SS, Brandt LJ. Treatment of refractory/recurrent *C. difficile*-associated disease by donated stool transplanted via colonoscopy: a case series of 12 patients. *J Clin Gastroenterol* 2010; 44:562–566.
28. Mattila E, Uusitalo-Seppälä R, Wuorela M, et al. Fecal transplantation, through colonoscopy, is effective therapy for recurrent *Clostridium difficile* infection. *Gastroenterology* 2012; 142:490–496.
29. Garborg K, Waagsbø B, Stallema A, Matre J, Sundøy A. Results of faecal donor instillation therapy for recurrent *Clostridium difficile*-associated diarrhoea. *Scand J Infect Dis* 2010; 42:857–861.
30. Mellow MH, Kanatzar A. Colonoscopic fecal bacteriotherapy in the treatment of recurrent *Clostridium difficile* infection—results and follow-up. *J Okla State Med Assoc* 2011; 104:89–91.
31. Rohlke F, Surawicz CM, Stollman N. Fecal flora reconstitution for recurrent *Clostridium difficile* infection: results and methodology. *J Clin Gastroenterol* 2010; 44:567–570.
32. Silverman MS, Davis I, Pillai DR. Success of self-administered home fecal transplantation for chronic *Clostridium difficile* infection. *Clin Gastroenterol Hepatol* 2010; 8:471–473.
33. Gough E, Shaikh H, Manges AR. Systematic review of intestinal microbiota transplantation (fecal bacteriotherapy) for recurrent *Clostridium difficile* infection. *Clin Infect Dis* 2011; 53:994–1002.
34. Brandt LJ, Aroniadis OC, Mellow M, et al. Long-term follow-up of colonoscopic fecal microbiota transplant for recurrent *Clostridium difficile* infection. *Am J Gastroenterol* 2012; 107:1079–1087.
35. Turnbaugh PJ, Ley RE, Hamady M, Fraser-Liggett CM, Knight R, Gordon JI. The human microbiome project. *Nature* 2007; 449:804–810.
36. Borody TJ, Warren EF, Leis S, Surace R, Ashman O. Treatment of ulcerative colitis using fecal bacteriotherapy. *J Clin Gastroenterol* 2003; 37:42–47.
37. Borody TJ, Torres M, Campbell J, et al. Reversal of inflammatory bowel disease (IBD) with recurrent fecal microbiota transplants (FMT). *Am J Gastroenterol* 2011; 106:S352.
38. Andrews P, Borody TJ, Shortis NP, Thompson S. Bacteriotherapy for chronic constipation—long term follow-up. (abstract). *Gastroenterology* 1995; 108:A563.
39. Borody TJ. Bacteriotherapy for chronic fatigue syndrome: a long-term follow up study. Presented at the 1995 Chronic Fatigue Syndrome National Consensus Conference.
40. Borody TJ, Leis S, Campbell J, et al. Fecal microbiota transplantation (FMT) in multiple sclerosis (MS) (abstract). *Am J Gastroenterol* 2011; 106:S352.
41. Borody TJ, Campbell J, Torres M, et al. Reversal of idiopathic thrombocytopenic purpura (ITP) with fecal microbiota transplantation (FMT) (abstract). *Am J Gastroenterol* 2011; 106:S352.
42. Vrieze AF, Holleman MJ, Serlie MT, Ackermans GM, Dallinga-Thie GM, Groen AK. Metabolic effects of transplanting gut microbiota from lean donors to subjects with metabolic syndrome (abstract). *Diabetologia* 2010; 53:S44.
43. Bakken JS. Fecal bacteriotherapy for recurrent *Clostridium difficile* infection. *Anaerobe* 2009; 15:285–289.
44. Bjørneklett A. [To repair an ecosystem] (In Norwegian). *Tidsskr Nor Lægeforen* 1998; 118:1026.
45. Brandt LJ, Borody TJ, Campbell J. Endoscopic fecal microbiota transplantation: “first-line” treatment for severe *Clostridium difficile* infection? *J Clin Gastroenterol* 2011; 45:655–657.
46. Kelly CR, de Leon L, Jasutkar N. Fecal microbiota transplantation for relapsing *Clostridium difficile* infection in 26 patients: methodology and results. *J Clin Gastroenterol* 2012; 46:145–149.
47. Thanjan AJ, Southern W, Anand N, et al. Is *Clostridium difficile* infection (CDI) more difficult to eradicate in patients with diverticulosis? (abstract) *Am J Gastroenterol* 2008; 103:S195.
48. Persky SE, Brandt LJ. Treatment of recurrent *Clostridium difficile*-associated diarrhea by administration of donated stool directly through a colonoscope. *Am J Gastroenterol* 2000; 95:3283–3285.
49. Nieuwdorp M, van Nood E, Speelman P, et al. [Treatment of recurrent *Clostridium difficile*-associated diarrhoea with a suspension of donor faeces] (In Dutch). *Ned Tijdschr Geneesk* 2008; 152:1927–1932.
50. van Nood E, Speelman P, Kuijper EJ, Keller JJ. Struggling with recurrent *Clostridium difficile* infections: is donor faeces the solution? *Euro Surveill* 2009; 14. doi:pii:19316.
51. Kahn SA, Gorawara-Bhat R, Rubin DT. Fecal bacteriotherapy for ulcerative colitis: patients are ready, are we? *Inflamm Bowel Dis* 2012; 18:676–684.

ADDRESS: Markus D. Agito, MD, Akron General Medical Center, 400 Wabash Avenue, Akron, OH 44307; e-mail mdagito@yahoo.com.