

The Clinical Picture

Right upper-abdominal pain in a 97-year-old

A 97-YEAR-OLD MAN has had right upper-abdominal pain intermittently for 2 weeks. He has hypertension, stage IV chronic kidney disease, chronic obstructive pulmonary disease, and constipation. He has never had abdominal surgery.

He describes his pain as mild and dull. It does not radiate to the right lower quadrant or the back and is not aggravated by eating. He reports no fever or changes in appetite or bowel habits during the last 2 weeks. His body temperature is 36.8°C, blood pressure 114/68 mm Hg, heart rate 86 beats per minute, and respiratory rate 16 times per minute.

On physical examination, his abdomen is soft with no guarding and with hypoactive bowel sounds. No Murphy sign is noted. Hemography shows a normal white blood cell count of $7.8 \times 10^9/L$ (reference range 4.5–11.0). Serum biochemistry studies show an alanine transaminase level of 23 U/L (5–50) and a lipase level of 40 U/L (12–70); the C-reactive protein level is 0.5 mg/dL (0.0–1.0). A sitting chest radiograph shows a focal gas collection over the right subdiaphragmatic area (FIGURE 1).

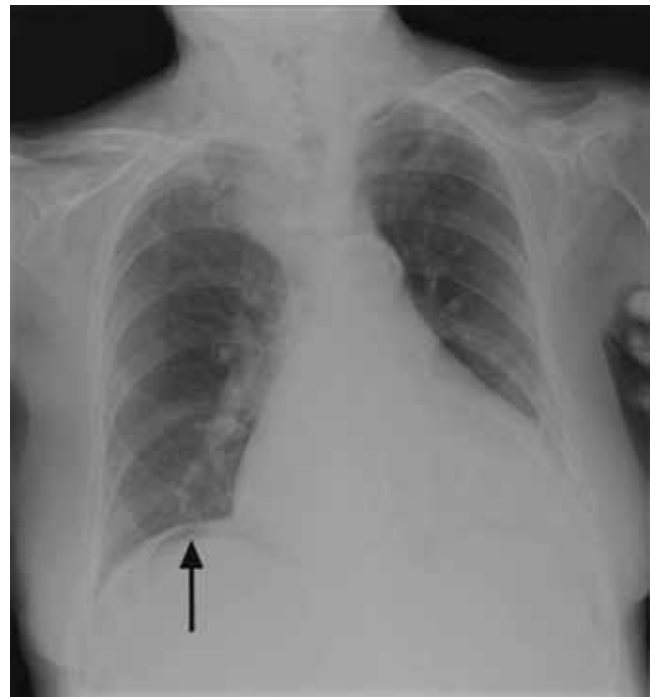


FIGURE 1

Q: Based on the information above, which is most likely the cause of this man's upper-abdominal pain?

- ☐ Perforated viscera
- ☐ Diverticulitis
- ☐ Chilaiditi syndrome
- ☐ Subdiaphragmatic abscess
- ☐ Emphysematous cholecystitis

A: The workup of this patient did not indicate active disease, so the subphrenic gas on the radiograph most likely is the Chilaiditi sign. This is a benign finding that, in a patient with gastrointestinal symptoms (nausea, vomiting, constipation, upper-abdominal pain), is labeled Chilaiditi syndrome.

■ CHILAITIDI SIGN AND SYNDROME

The Chilaiditi sign¹ describes a benign, incidental radiologic finding of subphrenic gas caused by interposition of colonic segments (or small intestine in rare cases) between the liver and the diaphragm. The radiologic finding is called the Chilaiditi sign if the patient is asymptomatic or Chilaiditi syndrome if the patient has gastrointestinal symptoms, as our patient did. The Chilaiditi sign is reportedly found in 0.02% to 0.2% of all chest and abdominal films.

Chilaiditi syndrome has a male predominance.² Predisposing factors include an atrophic liver, laxity of the hepatic or the transverse colon suspension liga-

Right upper abdominal pain has many possible causes, including benign, self-limited conditions

ment, abnormal fixation of the mesointestine, and diaphragmatic weakness. Other factors include advanced age; a history of abdominal surgery, adhesion, or intestinal obstruction³; chronic lung disease; and cirrhosis.⁴

Management is usually conservative, with a prokinetic agent or enema for constipation, and bed-rest or bowel decompression as needed, unless complications occur. Our patient's extreme age, underlying chronic pulmonary disease, and constipation predisposed him to this rare gastrointestinal disorder.

In this patient, pain in the right upper quadrant initially suggested an inflammatory disorder involving the liver, gallbladder, and transverse or ascending colon. Right upper-quadrant pain with radiologic evidence of subphrenic air collection further raises suspicion of pneumoperitoneum from diverticulitis, bowel perforation, or gas-forming abscess. However, this patient's normal transaminase level, low C-reactive protein value, and prolonged symptom course made hepatitis, cholecystitis, diverticulitis, and subdiaphragmatic abscess less likely. Nonetheless, severe intra-abdominal pathology can sometimes manifest with only minor symptoms in very elderly patients. Consequently, the main concern in this scenario was whether he had minor and undetected perforated viscera causing pneumoperitoneum with an indolent course, or rather a benign condition such as Chilaiditi syndrome causing pain and subphrenic air.

■ IS IT CHILAITIDI SYNDROME OR PNEUMOPERITONEUM?

Chilaiditi syndrome and perforated viscera both involve subphrenic air, but they differ radiologically and clinically. Radiologically, identification of haustra or plicae circulares within the gas collection or fixed subphrenic air upon postural change indicates the Chilaiditi sign and favors Chilaiditi syndrome as the origin of the symptoms. Pneumoperitoneum from perforated viscera is more likely if the abnormal gas collection changes its position upon postural change. Abdominal ultrasonography can also assist in diagnosis by showing a fixed air collection around the hepatic surface in the Chilaiditi sign. Definite

radiologic diagnosis can be reached through abdominal computed tomography. Clinically, these two disorders may manifest different severity, as perforated viscera often mandate surgical attention, whereas Chilaiditi syndrome seldom requires surgical treatment (25% of cases).²

Patients with the Chilaiditi sign also may develop abdominal pathology other than Chilaiditi syndrome per se. In our patient, the subphrenic air displayed a faint contour of bowel segments. His symptom course, benign physical examination, and the lack of laboratory evidence of other intra-abdominal pathology led us to suspect Chilaiditi syndrome as the cause of his abdominal pain. A normal leukocyte count and stable vital signs made the diagnosis of a major life-threatening condition extremely unlikely. Subsequently, abdominal sonography done at the bedside disclosed fixed colonic segments between the liver and the diaphragm. No hepatic or gallbladder lesions were detected. Chilaiditi syndrome was confirmed.

■ TAKE-HOME MESSAGE

As seen in this case, the accurate diagnosis rests on a careful physical examination and laboratory evaluation but, most importantly, on sound clinical judgment. Right upper-quadrant pain is often encountered in primary care practice and has many diagnostic possibilities, including benign, self-limited conditions such as Chilaiditi syndrome. It is vital to distinguish between benign conditions and severe life-threatening disorders such as hollow organ perforation so as not to operate on patients who can be managed conservatively. ■

■ REFERENCES

1. **Chilaiditi D.** Zur Frage der Hepatoptose und Ptose in allgemeinen in Anschluss an drei Fälle von temporärer, partieller Lebersverlagerung. *Fortschr Geb Röntgenstr Nuklearned Ergänzungsband* 1910; 16:173–208.
2. **Saber AA, Boros MJ.** Chilaiditi's syndrome: what should every surgeon know? *Am Surg* 2005; 71:261–263.
3. **Lo BM.** Radiographic look-alikes: distinguishing between pneumoperitoneum and pseudopneumoperitoneum. *J Emerg Med* 2010; 38:36–39.
4. **Fisher AA, Davis MW.** An elderly man with chest pain, shortness of breath, and constipation. *Postgrad Med J* 2003; 79:180, 183–184.

ADDRESS: Chia-Ter Chao, MD, Department of Traumatology, National Taiwan University Hospital, NO.7, Chung-Shan South Road, 100 Taipei, Taiwan, R.O.C.; e-mail ctchao@ntuh.gov.tw.