

# AURICULAR PAROXYSMAL TACHYCARDIA IN AN INFANT

## *Report of a Case*

A. CARLTON ERNSTENE, M.D.

Important disturbances of cardiac rhythm are uncommon in infancy, but one which occurs occasionally is auricular paroxysmal tachycardia. The attacks of tachycardia usually develop suddenly and are characterized by a regular rhythm at an extremely rapid rate. The paroxysms generally last for a few minutes to several hours, and the reestablishment of normal rhythm is, as a rule, abrupt. Many attacks terminate spontaneously or as the result of vomiting, while others can be brought to an end by pressure on the carotid sinus. It is only rarely that drug therapy is necessary. The present case is reported because of the long duration of the attack, its systemic effect on the patient, and the difficulties encountered in restoring normal rhythm.

### CASE REPORT

The patient, a white boy 12 months of age, was admitted to the hospital on August 11, 1940 because of refusal to eat, diarrhea, loss of weight and tachycardia. Diarrhea, refusal to eat and occasional vomiting had developed about five weeks earlier, and after these symptoms had been present for ten days or two weeks, it was noted that the heart rate was extremely rapid. The tachycardia had persisted until the present without interruption. The infant refused practically all of his feedings and whenever he did take even a small amount, a considerable part of this was promptly regurgitated. The diarrhea, however, had improved gradually although at the time of admission there were still two to five movements each day. The body weight had decreased from 25 pounds at the time of onset of the symptoms to 18 pounds at the time of entering the hospital.

The past history was irrelevant except for a short attack of probable auricular paroxysmal tachycardia coincident with a gastrointestinal disturbance at the age of 3 months.

The general physical examination revealed a poorly nourished, dehydrated, restless infant. The temperature was 99° F and the pulse rate, 200 per minute. There was no engorgement of the peripheral veins. Pressure on the carotid sinus in either side of the neck had no effect upon the heart rate. The lungs were clear on percussion and auscultation. The heart was not enlarged; its rhythm was regular, and no murmurs were heard. The liver was not enlarged or tender, and there was no peripheral edema.

The urine had a specific gravity of 1.028 and contained a faint trace of albumin but no sugar or abnormal cellular elements. The red blood cell count was 5,590,000 per cu.mm. and the hemoglobin content 68 per cent. The leukocyte count was 6,800 per cu.mm. The Wassermann reaction of the blood was negative. Roentgenologic examination of the chest showed the heart to be within the limits of normal in size, shape and position. The electrocardiogram revealed auricular paroxysmal tachycardia with a rate of 230 per minute (Fig. 1).

During the first 48 hours in the hospital, treatment consisted only of the administration of liberal amounts of physiologic solution of sodium chloride containing 3 per cent glucose. The tachycardia persisted and the symptoms remained unchanged. On the third day in the hospital, mechohyl, 5 mg., was given by subcutaneous injection. Within a few seconds the heart rhythm became irregular and the rate dropped to approximately 70 beats per minute. The reduced rate, however, per-

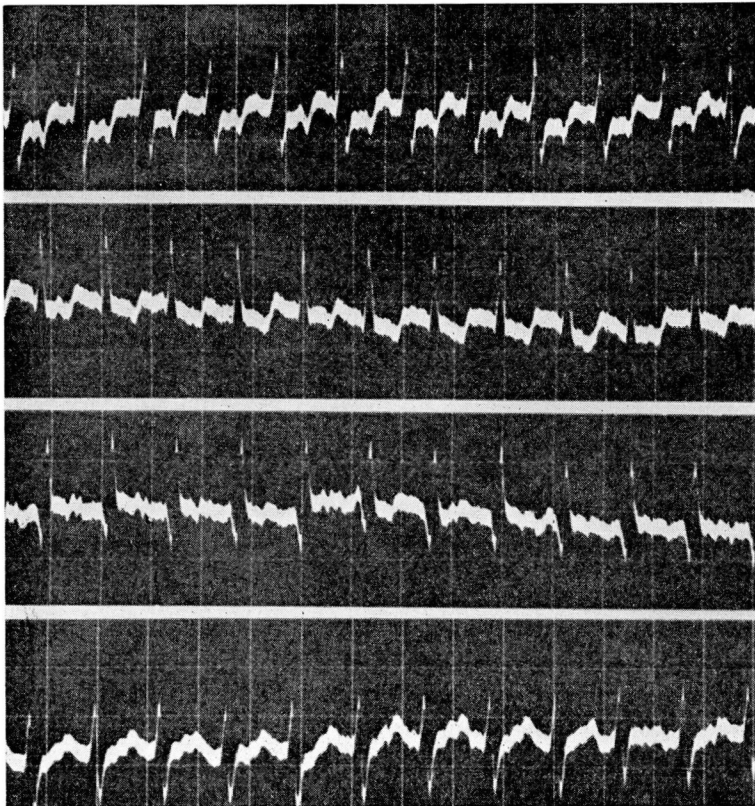


FIGURE 1: Auricular paroxysmal tachycardia. The rhythm is perfectly regular and the rate 230 per minute. The P waves distort the S-T segments and are diphasic or inverted in Lead 1, inverted in Lead 2, upright or diphasic in Lead 3, and upright in Lead 4F. The P-R interval is approximately 0.14 seconds.



## AURICULAR PAROXYSMAL TACHYCARDIA

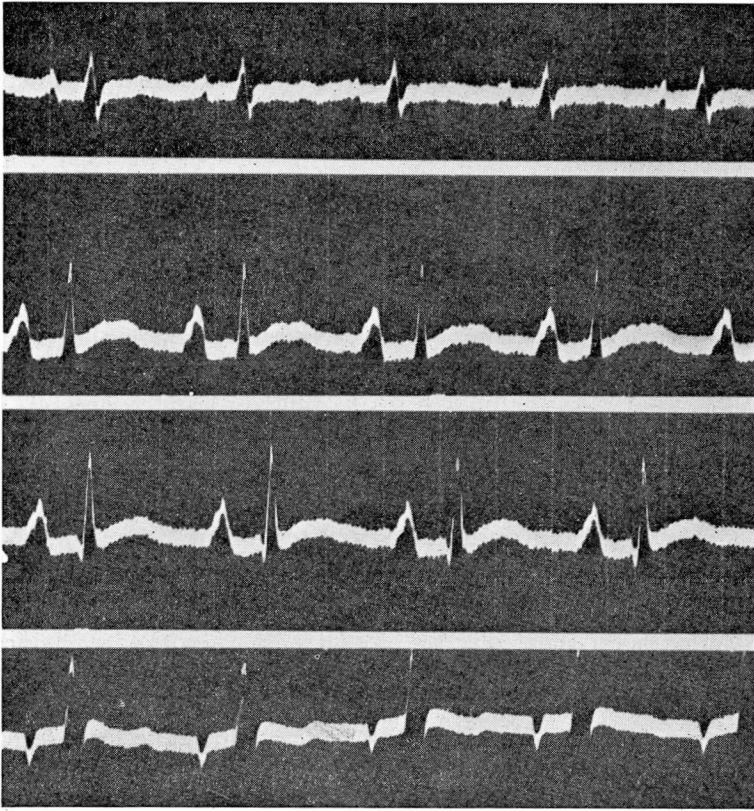


FIGURE 2: Normal rhythm. The rate is 100 per minute. The P waves are prominent and notched in Leads 2 and 3 and the P-R interval approximately 0.18 seconds. The T waves are flat in Leads 1 and 4F and are somewhat distorted by U waves in all leads. A tendency toward right axis deviation is present. The patient had received 2.75 cat units of digitalis.

sisted for not more than two minutes, and the tachycardia then returned. One and one-half hours later a second dose of mecholyl of the same size was administered, but this time neither the rhythm nor the rate of the heart was affected. On the following day, 7.5 mg. of mecholyl were given, and again the heart rate decreased to approximately 70 beats per minute and the rhythm became irregular. The tachycardia, with a rate of 240 per minute, returned within slightly more than one minute. Fifteen minutes later a second injection of the same size had the same transient effect. Several hours later quinine dihydrochloride, 60 mg., was administered by intravenous injection but without effect on the heart rate or rhythm.

On the morning of August 15 the administration of a digitalis preparation suitable for parenteral use and containing one cat unit

of digitalis bodies in 2 cc. of solution was begun by intramuscular injection. The first dose was 1 cc., and two additional doses of 0.5 cc. were given at intervals of six hours. The heart rate remained unchanged, and on each of the next two days the patient received three doses of 0.5 cc. each. During the night after the last of these injections the heart rate was noted to have dropped to 106 per minute. At eight o'clock the next morning, however, the rate was 136 per minute and two hours later it had increased to 168. One-half cubic centimeter of the digitalis preparation was given, and within the following two hours the rate dropped to 120 beats per minute. A further decrease in rate to 100 per minute occurred in the next twelve hours (Fig. 2) and the rate was maintained at approximately this level during the remainder of the stay in the hospital. No further medication was given, and the patient was discharged on August 22.

With the control of the tachycardia, the general symptoms began to improve quite promptly. The patient began to take his feedings regularly and vomited but once during the rest of the time in the hospital. The diarrhea also lessened although some looseness of the bowels remained for several days after discharge from the hospital.

A letter from the referring physician six months later states that about one week after the patient returned home there was a paroxysm of tachycardia with a rate of 200 per minute which came on during a prolonged crying spell and lasted but a few minutes. Except for this the child had been perfectly well and now weighed 31½ pounds.

#### SUMMARY

A case of auricular paroxysmal tachycardia in an infant 12 months of age has been reported. The paroxysm apparently developed as a complication of a gastrointestinal disturbance and in turn seemed to be responsible for the persistence of refusal to eat, regurgitation of the small amount of food taken and diarrhea. Although there was no detectable evidence of congestive heart failure, it is probable that the continuation of symptoms was due to passive congestion in the liver and gastrointestinal tract. The tachycardia continued without interruption for a little over four weeks, and the heart rate during this time ranged from 200 to 240 beats per minute.

Pressure on the carotid sinus in either side of the neck had no effect upon the heart rate. Mecholyl was administered by subcutaneous injection on four occasions. Three of the injections resulted in a prompt

decrease in the heart rate to approximately 70 beats per minute, and the cardiac rhythm at the same time became irregular. These effects were of transient nature, however, and the tachycardia was resumed within two minutes' time. The intravenous injection of quinine dihydrochloride on one occasion did not influence the heart rate or rhythm. The intramuscular administration of a digitalis preparation resulted in the restoration of normal rhythm after a total of 2.5 cat units of digitalis bodies had been given in divided doses in a period of 60 hours. The heart rate increased to 168 per minute within the following few hours, but after an additional 0.25 cat units of the digitalis preparation, normal rhythm was reestablished. With the control of the tachycardia the general symptoms promptly began to improve.