

KHALDOON SHAHEEN, MD

Department of Medicine, Case Western Reserve University–St. Vincent Charity Medical Center, Cleveland, OH

ABDUL HAMID ALRAIYES, MD

Department of Pulmonary, Critical Care, and Environmental Medicine, Tulane University Health Sciences Center, New Orleans, LA

MOTAZ BAIBARS, MD

Department of Medicine, Case Western Reserve University–St. Vincent Charity Medical Center, Cleveland, OH

M. CHADI ALRAIYES, MD, FACP

Clinical Assistant Professor of Medicine, Cleveland Clinic Lerner College of Medicine of Case Western Reserve University, and Staff, Department of Hospital Medicine, Cleveland Clinic

The Clinical Picture

Hyperpigmentation and hypotension

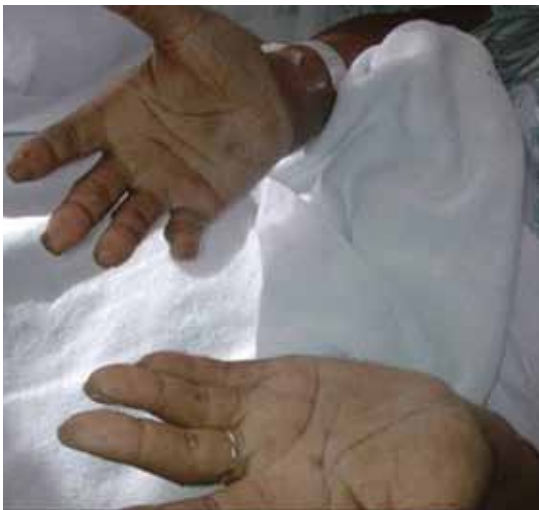

FIGURE 1. The patient has hyperpigmentation of the skin creases on the palms, as well as on the lips and the lower gum.

A 65-YEAR-OLD MAN PRESENTS with a 2-month history of generalized weakness, dizziness, and blurred vision. His symptoms began gradually and have been progressing over the last few weeks, so that they now affect his ability to perform normal daily activities.

He has lost 20 lb and has become anorec-

tic. He has no fever, night sweats, headache, cough, hemoptysis, or dyspnea. He has no history of abdominal pain, changes in bowel habits, nausea, vomiting, or urinary symptoms. He was admitted 6 weeks ago for the same symptoms; he was treated for hypotension and received intravenous (IV) fluids and electrolyte supplements for dehydration.

He has a history of hypertension, stroke, vascular dementia, and atrial fibrillation. He is taking warfarin (Coumadin), extended-release diltiazem (Cardizem), simvastatin (Zocor), and donepezil (Aricept). He underwent right hemicolectomy 5 years ago for a large tubular adenoma with high-grade dysplasia in the cecum.

At the time of presentation, he is hypotensive, with a blood pressure of 72/68 mm Hg, an irregular heart rate at 105/minute, and hyperpigmentation of the gums, lips, and skin creases in his palms (**FIGURE 1**). The rest of the examination is normal.

Initial laboratory values are as follows:

- White blood cell count $7.4 \times 10^9/L$ (reference range 4.5–11.0), with a normal differential
- Mild anemia, with a hemoglobin of 116 g/L (140–175)
- Activated partial thromboplastin time 59.9 sec (23.0–32.4)
- Serum sodium 135 mmol/L (136–142)
- Serum potassium 4.6 mmol/L (3.5–5.0)
- Aspartate aminotransferase 58 U/L (10–30)
- Alanine aminotransferase 16 U/L (10–40)
- Alkaline phosphatase 328 U/L (30–120)
- Urea, creatinine, and corrected calcium are normal.

Electrocardiography shows atrial fibrillation with low-voltage QRS complexes. Chest radiography is normal. A stool test is negative for occult blood. A workup for sepsis is negative.

doi:10.3949/ccjm.79a.10187

Echocardiography shows loculated fluids posterior to the left ventricle with no tamponade. Based on this finding, computed tomography (CT) of the chest is performed and demonstrates multiple small nodules in the lung parenchyma bilaterally, a finding consistent with metastatic disease with no visualized primary lung tumor mass. The same study also identifies multiple hypodense hepatic lesions with ascites surrounding the liver, another finding consistent with metastatic disease (FIGURE 2). Despite aggressive volume repletion, the patient remains hypotensive and symptomatic.

Q: Which is the appropriate test at this point to determine the cause of the hypotension?

- ☐ Serum parathyroid-hormone-related protein
- ☐ Baseline serum cortisol, plasma adrenocorticotrophic hormone (ACTH) levels, and an ACTH stimulation test with cosyntropin (Cortrosyn)
- ☐ Serum thyrotropin level
- ☐ Aspiration biopsy of subcutaneous fat with Congo red and immunostaining
- ☐ Late-night salivary cortisol

A: The correct next step is to measure baseline serum cortisol, to test ACTH levels, and to order an ACTH stimulation test with cosyntropin.

Primary adrenocortical insufficiency should be considered in patients with metastatic malignancy who present with peripheral vascular collapse, particularly when it is associated with cutaneous hyperpigmentation, chronic malaise, fatigue, weakness, anorexia, weight loss, hypoglycemia, and electrolyte disturbances such as hyponatremia and hyperkalemia.

Checking the baseline serum cortisol and ACTH levels and cosyntropin stimulation testing are vital steps in making an early diagnosis of primary adrenocortical insufficiency. Inappropriately low serum cortisol is highly suggestive of primary adrenal insufficiency, especially if accompanied by simultaneous elevation of the plasma ACTH level. The result of the ACTH stimulation test with cosyntropin is often confirmatory.

Measuring the serum parathyroid-hormone-related protein level is not indicated, since the patient has a normal corrected calcium. Patients with ectopic Cushing syndrome may present

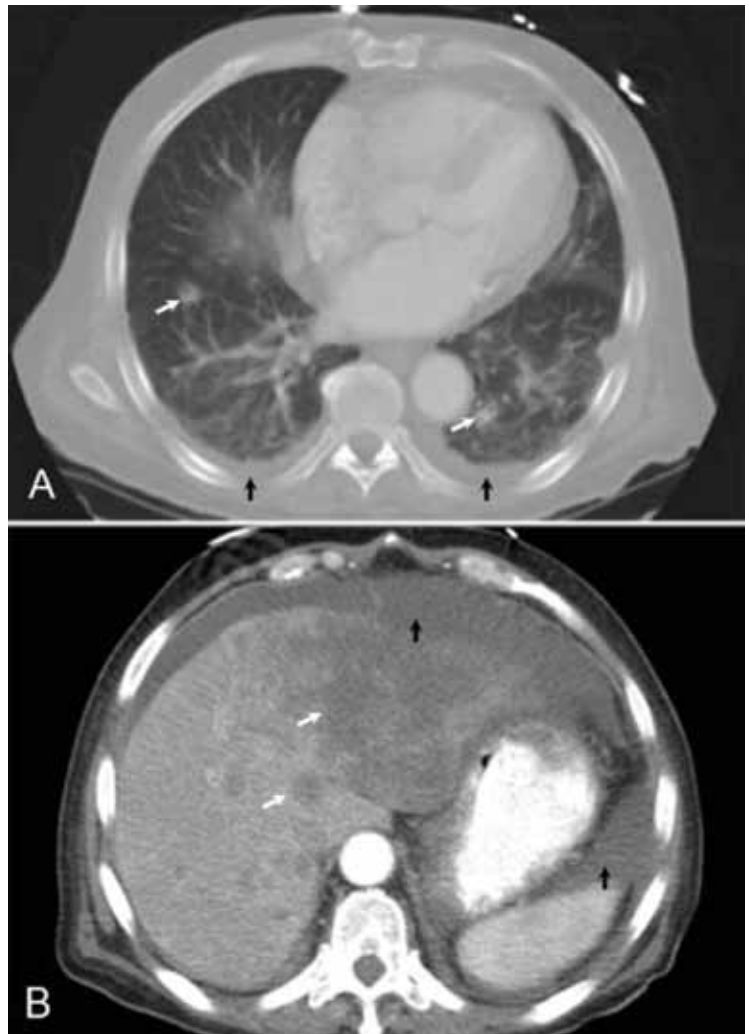


FIGURE 2. Computed tomography of the chest shows metastases in the lungs (A, white arrows) and liver (B, white arrows), bilateral pleural effusion (A, black arrows) and ascites (B, black arrows).

with weight loss due to underlying malignancy, but the presence of hypotension and a lack of hypokalemia makes such a diagnosis unlikely, and, therefore, measurement of late-night salivary cortisol is not the best answer. Amyloidosis, hypothyroidism, or hyperthyroidism are unlikely to have this patient's presentation.

RESULTS OF FURTHER EVALUATION

Our patient's ACTH serum level was elevated, and an ACTH stimulation test with cosyntropin confirmed the diagnosis of primary adrenal insufficiency.

Liver biopsy confirmed metastatic, poorly

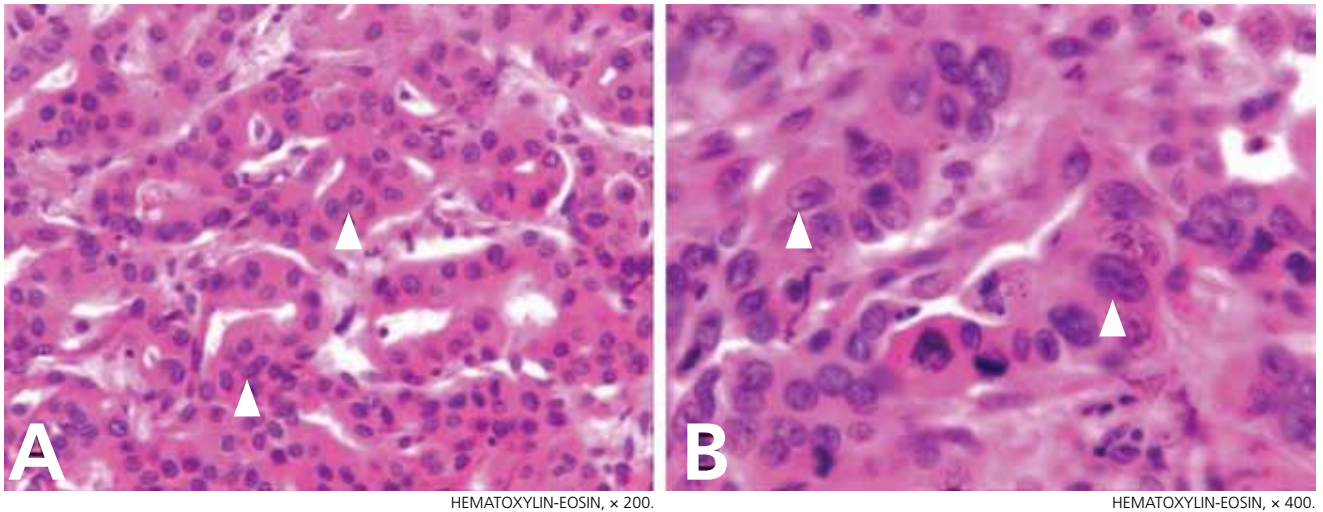


FIGURE 3. Studies of biopsy samples confirm metastatic, poorly differentiated adenocarcinoma in the liver. The neoplastic cells form ill-defined, gland-like structures (arrowheads, panel A). The cells have atypical nuclei with abundant eosinophilic cytoplasm, and abnormal mitotic figures are present (arrowheads, panel B). Further immunoperoxidase staining was as follows: cytokeratin-7-positive; cytokeratin-20-positive; hepatocyte-specific-antigen-negative; TTF1-negative. These staining patterns indicated cholangiocarcinoma or pancreatic adenocarcinoma as the possible primary tumor.

Management involves treating the underlying cause and starting hormone replacement therapy

differentiated adenocarcinoma, with cholangiocarcinoma and pancreatic adenocarcinoma possible primary tumors (FIGURE 3). The level of the tumor marker CA 19-9 was elevated at 4,628 U/mL (reference range 0–35), whereas levels of the markers CEA, CA-125, and prostate-specific antigen were normal.

CT of the abdomen failed to demonstrate primary tumors, but both adrenal glands were enlarged, likely from metastasis (FIGURE 4). His hypotension responded to treatment with hydrocortisone and fludrocortisone, and his symptoms resolved. No further testing or therapy was directed to the primary occult malignancy, as it was considered advanced. The prognosis was discussed with the patient, and he deferred any further management and was discharged to hospice care. He died a few months later.

PRIMARY ADRENOCORTICAL INSUFFICIENCY

Primary adrenocortical insufficiency is an uncommon disorder caused by destruction or dysfunction of the adrenal cortices. It is characterized by chronic deficiency of cortisol, aldosterone, and adrenal androgens. In the United States, nearly 6 million people are

considered to have undiagnosed adrenal insufficiency, which is clinically significant only during times of physiologic stress.¹

Primary adrenocortical insufficiency affects men and women equally. However, the idiopathic autoimmune form of adrenal insufficiency (Addison disease) is two to three times more common in women than in men.

If the condition is undiagnosed or ineffectively treated, the risk of significant morbidity and death is high. Symptoms and signs are nonspecific, and the onset is insidious.

Almost all patients with primary adrenal insufficiency have malaise, fatigue, anorexia, and weight loss. Vomiting, abdominal pain, and fever are more common during an adrenal crisis, when a patient with subclinical disease is subjected to major stress. Postural dizziness or syncope is a common result of volume depletion and hypotension.^{2–4} It is commonly accompanied by hyponatremia and hyperkalemia.

Hyperpigmentation is the most characteristic physical finding and is caused by an ACTH-mediated increase in melanin content in the skin.^{2,4,5} The resulting brown hyperpigmentation is most obvious in areas exposed to sunlight (face, neck, backs of hands), and in areas exposed to chronic friction or pressure, such as the elbows, knees, knuckles, waist, and

shoulders (brassiere straps).⁴ Pigmentation is also prominent in the palmar creases, areolae, axillae, perineum, surgical scars, and umbilicus. Other patterns of hyperpigmentation are patchy pigmentation on the inner surface of lips, the buccal mucosa, under the tongue, and on the hard palate.^{3,5} The hyperpigmentation begins to fade within several days and largely disappears after a few months of adequate glucocorticoid therapy.⁴

In the United States, 80% of cases of primary adrenocortical insufficiency are caused by autoimmune adrenal destruction. The remainder are caused by infectious diseases (eg, tuberculosis, fungal infection, cytomegalovirus infection, and *Mycobacterium avium-intracellulare* infection in the context of human immunodeficiency virus infection), by infiltration of the adrenal glands by metastatic cancer, by adrenal hemorrhage, or by drugs such as ketoconazole, fluconazole (Diflucan), metyrapone (Metopirone), mitotane (Lysodren), and etomidate (Amidate).^{4,6}

Adrenal metastatic disease

Infiltration of the adrenal glands by metastatic cancer is not uncommon, probably because of their rich sinusoidal blood supply, and the adrenals are the fourth most common site of metastasis. Common primary tumors are lung, breast, melanoma, gastric, esophageal, and colorectal cancers, while metastasis due to an undetermined primary tumor is the least common.⁷

Clinically evident adrenal insufficiency produced by metastatic carcinoma is uncommon because most of the adrenal cortex must be destroyed before hypofunction becomes evident.⁷⁻⁹

Malignancy rarely presents first as adrenal insufficiency caused by metastatic infiltration.¹⁰

Hormonal therapy may significantly improve symptoms and quality of life in patients with metastatic adrenal insufficiency.^{8,11}

■ DIAGNOSIS AND MANAGEMENT

Once primary adrenal insufficiency is suspected, prompt diagnosis and treatment are essential. A low plasma cortisol level ($< 3 \mu\text{g/dL}$) at 8 AM is highly suggestive of adrenal insufficiency if exposure to exogenous glucocorticoids has been excluded (including oral, inhaled, and injected),^{12,13} especially if ac-

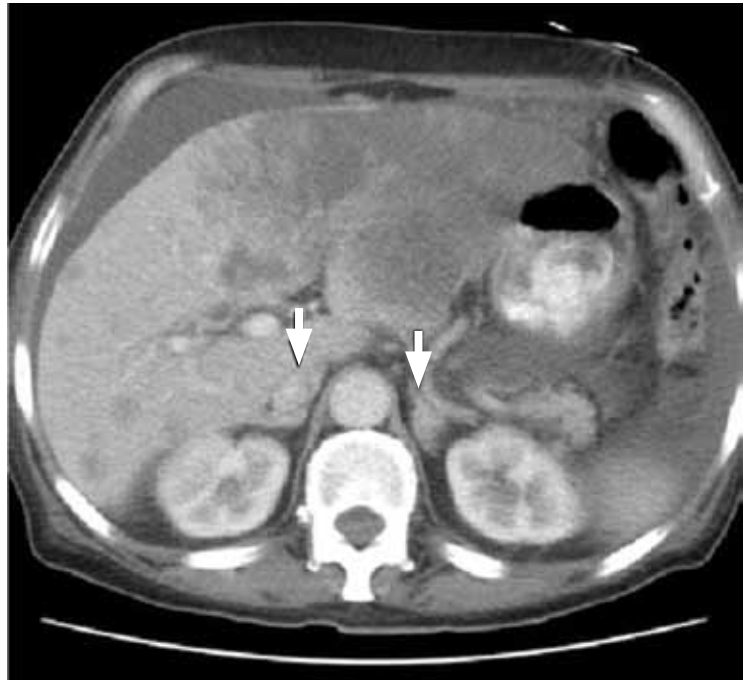

FIGURE 4. Computed tomography of the abdomen showed enlarged adrenal glands (arrows).

companied by simultaneous elevation of the plasma ACTH level (usually $> 200 \text{ pg/mL}$). An 8 AM cortisol concentration above $15 \mu\text{g/dL}$ makes adrenal insufficiency highly unlikely, but levels between 3 and $15 \mu\text{g/dL}$ are nondiagnostic and need to be further evaluated by an ACTH stimulation test with cosyntropin.^{4,7}

Imaging in primary adrenal insufficiency may be considered when the condition is not clearly autoimmune.¹⁴ Abdominal CT is the ideal imaging test for detecting abnormal adrenal glands. CT shows small, noncalcified adrenals in autoimmune Addison disease. It demonstrates enlarged adrenals in about 85% of cases caused by metastatic or granulomatous disease; and calcification is noted in cases of tuberculous adrenal disease.⁴

Management involves treating the underlying cause and starting hormone replacement therapy. Hormonal therapy consists of corticosteroids and mineralocorticoids; hydrocortisone is the drug of choice and is usually given with fludrocortisone acetate, which has a potent sodium-retaining effect. In the presence of a stressor (fever, surgery, severe illness), the dose of hydrocortisone should be doubled ($> 50 \text{ mg}$ hydrocortisone per day) for at least 3 to 5 days.^{2,4} ■

REFERENCES

1. **Erichsen MM, Løvås K, Fougner KJ, et al.** Normal overall mortality rate in Addison's disease, but young patients are at risk of premature death. *Eur J Endocrinol* 2009; 160:233–237.
2. **Oelkers W.** Adrenal insufficiency. *N Engl J Med* 1996; 335:1206–1212.
3. **Redman BG, Pazdur R, Zingas AP, Loredó R.** Prospective evaluation of adrenal insufficiency in patients with adrenal metastasis. *Cancer* 1987; 60:103–107.
4. **Berger M.** Hypofunction of the adrenal cortex in infancy. *Manit Med Rev* 1949; 29:132.
5. **Stulberg DL, Clark N, Tovey D.** Common hyperpigmentation disorders in adults: Part I. Diagnostic approach, café au lait macules, diffuse hyperpigmentation, sun exposure, and phototoxic reactions. *Am Fam Physician* 2003; 68:1955–1960.
6. **Zelissen PM, Bast EJ, Croughs RJ.** Associated autoimmunity in Addison's disease. *J Autoimmun* 1995; 8:121–130.
7. **Lutz A, Stojkovic M, Schmidt M, Arlt W, Allolio B, Reincke M.** Adrenocortical function in patients with macrometastases of the adrenal gland. *Eur J Endocrinol* 2000; 143:91–97.
8. **Kung AW, Pun KK, Lam K, Wang C, Leung CY.** Addisonian crisis as presenting feature in malignancies. *Cancer* 1990; 65:177–179.
9. **Cedermark BJ, Sjöberg HE.** The clinical significance of metastases to the adrenal glands. *Surg Gynecol Obstet* 1981; 152:607–610.
10. **Rosenthal FD, Davies MK, Burden AC.** Malignant disease presenting as Addison's disease. *Br Med J* 1978; 1:1591–1592.
11. **Seidenwurm DJ, Elmer EB, Kaplan LM, Williams EK, Morris DG, Hoffman AR.** Metastases to the adrenal glands and the development of Addison's disease. *Cancer* 1984; 54:552–557.
12. **Santiago AH, Ratzan S.** Acute adrenal crisis in an asthmatic child treated with inhaled fluticasone propionate. *Int J Pediatr Endocrinol* 2010; 2010. pii:749239.
13. **Holme J, Tomlinson JW, Stockley RA, Stewart PM, Barlow N, Sullivan AL.** Adrenal suppression in bronchiectasis and the impact of inhaled corticosteroids. *Eur Respir J* 2008; 32:1047–1052.
14. **Mohammad K, Sadikot RT.** Adrenal insufficiency as a presenting manifestation of nonsmall cell lung cancer. *South Med J* 2009; 102:665–667.

ADDRESS: Khaldoon Shaheen, MD, 4151 Westbrook Drive, Brooklyn, OH 44144; e-mail khaldoonshaheen@yahoo.com.