

Treating vasculitis with conventional immunosuppressive agents

DAVID JAYNE, MD, FRCP

Director, Vasculitis and Lupus Clinic, Addenbrooke's Hospital, Cambridge, UK

ABSTRACT

Standard therapy for granulomatosis with polyangiitis and other vasculitides is a combination of cyclophosphamide and glucocorticoids. Although most patients achieve remission, relapses and treatment-related morbidities are common. Clinical trials have yielded a wealth of data about less toxic alternatives to standard therapy, including new agents and methods of delivery. All aim to reduce long-term exposure to cyclophosphamide and glucocorticoids and so maintain safety while effectively preventing relapse. Individualized evaluation of risk and treatment selection will help maximize effectiveness and minimize toxicity.

In 1958, shortly after the first descriptions of granulomatosis with polyangiitis, or GPA (Wegener's granulomatosis), the 1-year mortality was 18%,¹ mainly due to renal failure. Physicians tried to combat the disease using various immunosuppressive drugs (nitrogen mustard and, in later years, azathioprine and methotrexate), but measurable success came only after investigators introduced cyclophosphamide (CYC) in combination with the glucocorticoid prednisone.²

A key 1992 study showed that the CYC/prednisone combination markedly improved the disease status in 91% of patients,³ with 75% achieving complete remission. The treatment came at a price, however, with almost all patients suffering serious morbidity or side effects. The results also highlighted concerns about potential malignancies caused by prolonged use of CYC and glucocorticoids. Those concerns motivated the European Vasculitis Study Group in the late 1980s and early 1990s to design and validate testing for antineutrophil cytoplasmic antibody (ANCA)-associated vasculitides (AAV) and pursue consensus regarding treatment.⁴

ALTERNATIVES TO STANDARD THERAPY

The accepted therapeutic strategy for GPA is to first induce remission using high doses of CYC and then prevent relapse with longer-term, less toxic therapeutic alternatives. These less toxic therapies include newer

agents as well as new methods of delivery, particularly for patients with nonsevere forms of disease.

Methotrexate—effective for early treatment

Methotrexate showed early promise in several non-randomized trials of patients with nonsevere disease. In one such study, de Groot et al subclassified 100 patients at diagnosis according to the extent and severity of the disease.⁵ Patients were then randomized to receive either standard oral CYC or methotrexate, each combined with prednisolone. Remission rates (90% to 94%) were comparable regardless of whether patients received CYC or methotrexate, although patients with more severe disease who were taking methotrexate took longer to achieve remission. At the same time, relapse rates were higher for methotrexate-taking patients (70%) compared with the CYC group (47%). Thus, while methotrexate could replace CYC for initial treatment of early AAV, CYC had a greater influence on subsequent relapse rates, particularly in patients with more severe forms of disease.

Pulse cyclophosphamide—a new method

Investigators tested pulse delivery of CYC compared with oral daily administration as a means of reducing the CYC dose. An analysis of 14 relatively small studies showed that pulse CYC had the same survival and renal failure rates as continuous therapy.⁶

One such trial, the CYC Daily Oral Versus Pulsed (CYCLOPS) trial, involved 149 patients with generalized disease (nephritis, GPA, and microscopic polyangiitis [MPA]) who were administered either an intravenous (IV) pulse or a daily oral CYC regimen.⁷ The pulse CYC neither shortened patients' time to remission nor increased the proportion of patients who achieved it. Patients receiving pulse CYC suffered one-third the rate of leukopenia experienced by patients who received the oral regimen. Since infection is a source of mortality in vasculitis, this finding is an important consideration when balancing the benefits of day-to-day control offered by oral administration against the safety of at-risk patients such as the elderly.

This treatment strategy may be relevant for patients

Dr. Jayne reported that he has received research grant support from Roche/Genentech and Vifor Pharma.

This article was developed from an audio transcript of Dr. Jayne's presentation at the "New Directions in Small-Vessel Vasculitis: ANCA, Target Organs, Treatment, and Beyond" symposium held at Cleveland Clinic on May 4, 2011. The

transcript was formatted and edited by Cleveland Clinic Journal of Medicine staff for clarity and conciseness, and was then reviewed, revised, and approved by Dr. Jayne.

doi:10.3949/ccjm.79.s3.10

Summary of treatment recommendations

MAINTENANCE THERAPY

A major challenge in treating vasculitides is preventing relapse while also avoiding treatment-related toxicity. The current standard is to switch patients, on remission, from cyclophosphamide (CYC) therapy to an alternative maintenance therapy. Azathioprine, methotrexate, mycophenolate mofetil (MMF), and leflunomide have advantages as well as disadvantages.

Azathioprine

In a trial of 155 patients newly diagnosed with generalized vasculitis,¹⁵ investigators found that substituting azathioprine at or after remission prevented relapse at a rate comparable to that observed with continued CYC.

Conclusion: *azathioprine is a safe alternative to standard therapy.*

Methotrexate

The Wegener's Granulomatosis-Entretien (WEGENT) trial, a prospective, open-label trial, compared methotrexate with azathioprine (**Figure**). Investigators found no difference in relapse rates or the number of adverse effects in 159 patients with granulomatosis with polyangiitis (GPA) who had entered remission.¹⁶ However, approximately 50% of all patients relapsed after 3 years.

Conclusion: *like azathioprine, methotrexate effectively prevents relapse, but the therapy still has shortcomings and should be avoided in patients with renal insufficiency.*

Mycophenolate mofetil

Because studies showed that MMF worked better than azathioprine in preventing renal transplant rejection, MMF was studied for its efficacy in preventing flare in vasculitis. In the International MMF Protocol to Reduce Outbreaks of Vasculitis (IMPROVE) trial, standard CYC was administered followed by either azathioprine or MMF.¹⁷ Results of previous studies suggested that MMF would be more effective than azathioprine, but the opposite was observed: patients receiving MMF experienced double the relapse rate compared with azathioprine.

Conclusion: *azathioprine and methotrexate are equally effective in maintaining remission, while MMF is less effective than azathioprine (**Figure**); however, MMF could be used*

as an alternative in patients with renal impairment, where it carries less risk.

Leflunomide

The German Network of Rheumatic Diseases compared leflunomide with methotrexate for remission maintenance following CYC induction.¹⁸ The trial was halted early after investigators observed an excess of relapses in the methotrexate group. At the same time, the number of severe relapses in the methotrexate group was exactly balanced by the number of severe events in the leflunomide group.

Conclusion: *leflunomide, at the high doses used in the study, is more effective than methotrexate, but patients may pay a price of higher toxicity.*

GLUCOCORTICOID

In response to concerns that the glucocorticoid portion of standard therapy is driving much of the early toxicity that patients experience, investigators recently launched the PEXIVAS trial, in which patients receive plasma exchange in addition to immunosuppressive and glucocorticoid therapy. The study is comparing two different intravenous (IV) and oral glucocorticoid regimens for patients who have either severe renal disease or lung hemorrhage. A recent meta-analysis found that longer courses of glucocorticoids are associated with lower relapse rates.¹⁹

Conclusion: *glucocorticoid withdrawal may increase relapse risk.*

CYCLOPHOSPHAMIDE

To determine how best to initiate CYC therapy, we followed up on patients who participated in two trials—one comparing short-term, 3-month CYC with 12 months of oral CYC²⁰ and one that compared IV with oral CYC.⁷ Initially, there was no difference in relapse rate, but approximately 30 months after termination of therapy, an excess of relapses was observed in the groups that received either the shorter-duration or the IV course of CYC. These patients received approximately one-half the cumulative CYC exposure compared with that received by the daily oral group.

Conclusion: *a lower cumulative CYC dosage is associated with higher relapse risk.*

with renal impairment. It was once thought that patients with renal failure after receiving CYC had more aggressive disease and therefore needed higher dosages. Investigators who studied the impact of renal insufficiency and hemodialysis on the pharmacokinetics of CYC found that clearance of CYC is impaired in patients with reduced renal function.⁸ Thus, when

renal function is suppressed, the CYC dosage should be reduced rather than increased.

Mycophenolate mofetil—efficacy not yet confirmed

Another alternative to CYC, mycophenolate mofetil (MMF), has gained much attention, although its effectiveness is not yet certain. Pilot data show that 13 of 17

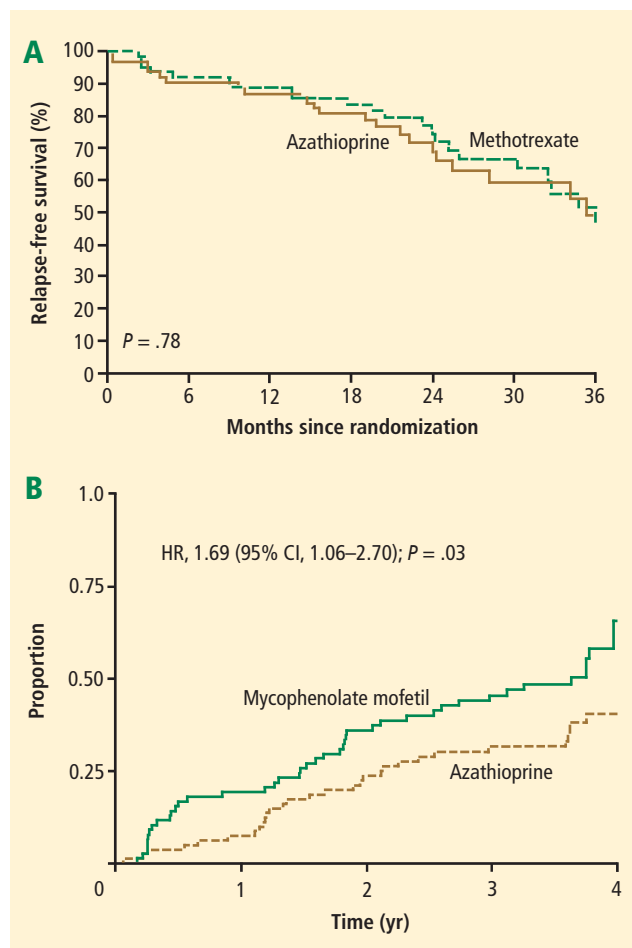


FIGURE. Azathioprine and methotrexate have comparable efficacy in maintaining remission (**A**).¹⁵ The relapse rate with mycophenolate mofetil, on the other hand, is nearly double that observed with azathioprine (**B**).¹⁶

(A) Reprinted with permission from *The New England Journal of Medicine* (Pagnoux C, et al. Azathioprine or methotrexate maintenance for ANCA-associated vasculitis. *N Engl J Med* 2008; 359:2790–2803). Copyright © 2008 Massachusetts Medical Society. All rights reserved. (B) Reprinted with permission from *JAMA* (Hiemstra TF, et al. Mycophenolate mofetil vs azathioprine for remission maintenance in antineutrophil cytoplasmic antibody-associated vasculitis. *JAMA* 2010; 304:2381–2388). Copyright © 2010 American Medical Association. All rights reserved.

patients with MPA achieved remission after 6 months of treatment with MMF.⁹ Meanwhile, the so-called MYCYC trial, in which patients with newly diagnosed AAV receive either the CYCLOPS regimen or MMF, is under way.¹⁰

Deoxyspergualin—remission not sustained

A nonstandard drug that warrants attention is deoxyspergualin (now called gusperimus), licensed in Japan for 15 years. In a prospective, open-label trial of 45 patients with relapsing or refractory GPA, investigators showed that 95% achieved partial remission and 45% full remission, although remission was not sustained when therapy was stopped.¹¹ Because the drug must be administered daily for 21 days by subcutaneous injection,

deoxyspergualin is not easy to use. It may represent an alternative, however, because it permitted prednisolone dosage reduction.

EVALUATING RISK AND CHOOSING THERAPIES

Considering all of the available data, the question arises regarding what to prescribe for patients who present in a variety of contexts. On the basis of evidence and consensus, the European League Against Rheumatism (EULAR) has published recommendations for the evaluation, investigation, treatment, and monitoring of patients with primary, small-vessel,¹² large-vessel,¹³ and ANCA-associated¹⁴ vasculitides (see “Summary of treatment recommendations,” page S47).^{15–20}

CONSIDERATIONS IN CHOOSING REMISSION THERAPY

Overall, when planning remission therapy and its duration, clinicians must balance the efficacy of CYC and glucocorticoids against their toxicity. Close monitoring and the patient’s capacity to adhere to instructions are two critical issues. Other important considerations include the risk and consequences of relapse, which vary in different circumstances, and the association of cancer with CYC therapy.

Relapse risk is variable

Certain patients are at higher risk of relapse than others. Patients with GPA or proteinase-3-ANCA-positive disease are at higher relapse risk than those who have MPA. ANCA-positive disease in remission or rising ANCA markers both increase the risk of relapse. Ear, nose, throat, and lung diseases increase the likelihood of relapse. Patients with GPA who are *Staphylococcus aureus* carriers have increased risk. Serum creatinine levels of 2.0 to 3.0 mg/dL at the end of induction therapy should arouse concern about renal relapse.

Most relapses affect the ear, nose, and throat system and do not threaten vital organs. Relapse does not increase the risk of end-stage renal disease or death.

Consider mortality and cancer data

Although the strongest predictor of early death is infection, advanced age and renal impairment also predict death. Chronic kidney disease stage at entry and glomerular filtration rate significantly predict mortality.²¹ More than 36 g CYC (equivalent to 9 to 12 months of standard oral therapy) increases the risk of bladder cancer 10-fold and myeloid leukemia 60-fold, but the cancer risk is time-dependent; malignancy requires 12 years on average to emerge.²²

CONCLUSION

Cyclophosphamide in combination with glucocorticoids remains the standard therapy for GPA and related vasculitides, despite the risk of significant treatment-related

comorbidities. Several strategies can be employed to reduce exposure, such as sequential withdrawal of CYC and IV administration. The optimization of glucocorticoid dosing will be a major research focus in the next decade. Newer agents may improve the maintenance of remission; for example, azathioprine and methotrexate show equal efficacy and safety, while MMF is less effective. When planning remission maintenance therapy, the relapse risk should be considered carefully because it varies among clinical scenarios. Other factors in the decision include the consequences for the patient, monitoring requirements, and the patient's ability to understand and adhere to instructions.

REFERENCES

- Walton EW. Giant-cell granuloma of the respiratory tract (Wegener's granulomatosis). *Br Med J* 1958; 2:265–270.
- Novack SN, Pearson CM. Cyclophosphamide therapy in Wegener's granulomatosis. *N Engl J Med* 1971; 284:938–942.
- Hoffman GS, Kerr GS, Leavitt RY, et al. Wegener granulomatosis: an analysis of 158 patients. *Ann Intern Med* 1992; 116:488–498.
- Rasmussen N, Jayne DRW, Abramowicz D, et al. European therapeutic trials in ANCA-associated systemic vasculitis: disease scoring, consensus regimens and proposed clinical trials. *Clin Exp Immunol* 1995; 101(suppl 1):29–34.
- de Groot K, Rasmussen N, Bacon PA, et al. Randomized trial of cyclophosphamide versus methotrexate for induction of remission in early systemic antineutrophil cytoplasmic antibody-associated vasculitis. *Arthritis Rheum* 2005; 52:2461–2469.
- de Groot K, Adu D, Savage COS, for EUVAS (European Vasculitis Study Group). The value of pulse cyclophosphamide in ANCA-associated vasculitis: meta-analysis and critical review. *Nephrol Dial Transplant* 2001; 16:2018–2027.
- de Groot K, Harper L, Jayne DRW, et al. Pulse versus daily oral cyclophosphamide for induction of remission in antineutrophil cytoplasmic antibody-associated vasculitis: a randomized trial. *Ann Intern Med* 2009; 150:670–680.
- Haubitz M, Bohnenstengel F, Brunkhorst R, Schwab M, Hofmann U, Busse D. Cyclophosphamide pharmacokinetics and dose requirements in patients with renal insufficiency. *Kidney Int* 2002; 61:1495–1501.
- Silva F, Specks U, Kalra S, et al. Mycophenolate mofetil for induction and maintenance of remission in microscopic polyangiitis with mild to moderate renal involvement: a prospective, open-label pilot trial [published online ahead of print January 21, 2010]. *Clin J Am Soc Nephrol* 2010; 5:445–453. doi: 10.2215/CJN.06010809
- MYCYC clinical trial protocol. The European Vasculitis Society Web site. <http://www.vasculitis.org>. Updated April 12, 2011. Accessed June 13, 2012.
- Flossmann O, Baslund B, Bruchfeld A, et al. Deoxyspergualin in relapsing and refractory Wegener's granulomatosis [published online ahead of print August 19, 2008]. *Ann Rheum Dis* 2009; 68:1125–1130. doi: 10.1136/ard.2008.092429
- Mukhtyar C, Guillevin L, Cid MC, et al; for the European Vasculitis Study Group. EULAR recommendations for the management of primary small and medium vessel vasculitis [published online ahead of print April 15, 2008]. *Ann Rheum Dis* 2009; 68:310–317. doi: 10.1136/ard.2008.088096
- Mukhtyar C, Guillevin L, Cid MC, et al; for the European Vasculitis Study Group. EULAR recommendations for the management of large vessel vasculitis [published online ahead of print April 15, 2008]. *Ann Rheum Dis* 2009; 68:318–323. doi: 10.1136/ard.2008.088351
- Hellmich B, Flossmann O, Gross WL, et al; on behalf of the European Vasculitis Study Group. EULAR recommendations for conducting clinical studies and/or clinical trials in systemic vasculitis: focus on anti-neutrophil cytoplasm antibody-associated vasculitis [published online ahead of print December 14, 2006]. *Ann Rheum Dis* 2007; 66:605–617. doi: 10.1136/ard.2006.062711
- Jayne D, Rasmussen N, Andrassy K, et al; for the European Vasculitis Study Group. A randomized trial of maintenance therapy for vasculitis associated with antineutrophil cytoplasmic autoantibodies. *N Engl J Med* 2003; 349:36–44.
- Pagnoux C, Mahr A, Hamidou MA, et al; for the French Vasculitis Study Group. Azathioprine or methotrexate maintenance for ANCA-associated vasculitis. *N Engl J Med* 2008; 359:2790–2803.
- Hiemstra TE, Walsh M, Mahr A, et al; for the European Vasculitis Study Group (EUVAS). Mycophenolate mofetil vs azathioprine for remission maintenance in antineutrophil cytoplasmic antibody-associated vasculitis: a randomized controlled trial [published online ahead of print November 8, 2010]. *JAMA* 2010; 304:2381–2388. doi: 10.1001/jama.2010.1658
- Metzler C, Miehle N, Manger K, et al; for the German Network of Rheumatic Diseases. Elevated relapse rate under oral methotrexate versus leflunomide for maintenance of remission in Wegener's granulomatosis [published online ahead of print May 22, 2007]. *Rheumatology* 2007; 46:1087–1091. doi: 10.1093/rheumatology/kem029
- Walsh M, Merkel PA, Mahr A, Jayne D. Effects of duration of glucocorticoid therapy on relapse rate in antineutrophil cytoplasmic antibody-associated vasculitis: a meta-analysis. *Arthritis Care Res (Hoboken)* 2010; 62:1166–1173.
- Vanková Z, Ríhová Z, Jancová E, Rysavá R, Merta M, Tesar V. Optimizing the therapeutic strategies in ANCA-associated vasculitis—single centre experience with international randomized trials. *Prague Med Rep* 2006; 107:199–212.
- Flossmann O, Berden A, de Groot K, et al; for the European Vasculitis Study Group. Long-term patient survival in ANCA-associated vasculitis [published online ahead of print November 24, 2010]. *Ann Rheum Dis* 2011; 70:488–494. doi: 10.1136/ard.2010.137778
- Faurschou M, Sorensen IJ, Mellekjaer L, et al. Malignancies in Wegener's granulomatosis: incidence and relation to cyclophosphamide therapy in a cohort of 293 patients [published online ahead of print October 15, 2007]. *J Rheumatol* 2008; 35:100–105.

Correspondence: David Jayne, MD, FRCP, Vasculitis and Lupus Clinic, Box 57, Cambridge University Hospitals NHS Foundation Trust, Hills Road, Cambridge CB2 0QQ; dj106@cam.ac.uk

Biologic agents in the treatment of granulomatosis with polyangiitis

ULRICH SPECKS, MD

Professor of Medicine, Division of Pulmonary and Critical Care Medicine, Mayo Clinic College of Medicine, Rochester, MN

■ ABSTRACT

Granulomatosis with polyangiitis (GPA) is a type of vasculitis that affects the respiratory tract and kidneys. Without treatment, half of patients die within 6 months. Standard therapy (a daily combination of cyclophosphamide and glucocorticoids) can induce remission, but the duration is short and treatment is plagued by serious morbidity. Advances in understanding the potential target of cyclophosphamide—B cells, that indirectly give rise to antineutrophil cytoplasmic antibodies (ANCA)—led to a new B-cell–targeted strategy. We administered rituximab, an anti-B-cell agent, to patients with severe GPA and microscopic polyangiitis. Overall, rituximab matched the efficacy of cyclophosphamide in inducing remission and was superior in patients with relapsing disease. The timing of re-treatment can be individualized based on patients' B-cell counts and ANCA levels in patients with chronically relapsing GPA.

Granulomatosis with polyangiitis (GPA [Wegener's granulomatosis]) is a vasculitis that affects the renal and respiratory systems. Remission can be induced in most patients with the combination of glucocorticoids and cyclophosphamide. Unfortunately, patients often suffer disease relapses requiring re-treatment and exposure to the cumulative toxicities of repeated cyclophosphamide use. In recent years, improved understanding of the mechanisms of action of cyclophosphamide has led to investigation of treatment strategies that target the role of B cells more specifically in the pathogenesis of the disease.

This article reviews the results of recent studies involving the use of biologic therapy in the treatment of GPA, with a brief examination of historic events that influenced the design of recent trials.

■ HISTORICAL PERSPECTIVE

The natural history of GPA was characterized in 1958¹ in a retrospective study showing that 50% of those afflicted died within 6 months, and 80% died by 18 months. Prednisone and cyclophosphamide changed this dismal

outcome. The combination markedly improved the status of 91% to 93% of patients,^{2,3} with most achieving complete remission. Treatment came with a price, however. Almost all patients suffered serious morbidity or side effects, including chronic renal insufficiency (11% requiring dialysis), recurrent infections, hearing loss, infertility, and diabetes. In addition, most patients (99 of 155 in one study) suffered relapse and a significant number (19 of 155) died because of the disease or its treatment.

Investigators' pursuit of treatment alternatives included foregoing cyclophosphamide in patients who had limited or early systemic GPA and reducing the duration of treatment for patients with severe disease.⁴ Studies conducted in the late 1990s defined what eventually became standard therapy for GPA: remission induction with glucocorticoids and methotrexate for limited GPA and with glucocorticoids and cyclophosphamide for severe disease. Following remission induction, after 3 to 6 months cyclophosphamide is replaced by azathioprine or methotrexate for remission maintenance. While helpful, these alternatives still fell short of achieving safe, long-term remission.

■ THERAPY WITH BIOLOGICS

Targeting tumor necrosis factor

The first randomized placebo-controlled trial of a biologic agent in GPA, the Wegener's Granulomatosis Etanercept Trial (WGET),⁴ evaluated whether etanercept, a soluble inhibitor of tumor necrosis factor (TNF), would be an effective adjunct to standard therapy. The results showed that etanercept did not confer any beneficial effect and, in fact, if combined with exposure to cyclophosphamide, etanercept increased the risk for solid tumors. Thus, anti-TNF therapy has a limited or no role in the management of antineutrophil cytoplasmic antibody (ANCA)-associated vasculitis (AAV).

Targeting B cells

The mechanisms of cyclophosphamide effects on disease activity were not clearly understood. In the late 1970s,

Dr. Specks reported that he has received consulting fees from Dynavax and Sanofi-Aventis.

Acknowledgment. Genentech provided drug and funding to the National Institute of Allergy and Infectious Disease for the conduct of the Rituximab in ANCA-Associated Vasculitis (RAVE) trial.

This article was developed from an audio transcript of Dr. Specks's presentation

at the "New Directions in Small-Vessel Vasculitis: ANCA, Target Organs, Treatment, and Beyond" symposium held at Cleveland Clinic on May 4, 2011. The transcript was formatted and edited by *Cleveland Clinic Journal of Medicine* staff for clarity and conciseness, and was then reviewed, revised, and approved by Dr. Specks.

doi:10.3949/ccjm.79.s3.11

however, National Institutes of Health investigators found that cyclophosphamide, at the doses administered for GPA, had a profound effect on B-cell function.⁵ Later investigations showed that disease activity of GPA was clearly related to the frequency of activated B cells detectable in the peripheral blood, while abnormally activated T cells were also detectable in patients in remission.⁶ These findings suggested that activated B cells might be responsible for disease activity, whereas persistently activated T cells might explain the chronically relapsing nature of the disease.⁶

B cells are the precursors of short-lived plasma cells, which are thought to be the primary source of autoantibodies, including ANCA. Based on clinical observations as well as in vitro and some animal model experiments, investigators have ascribed pathogenic roles to ANCA. Consequently, targeting the cells that produce these autoantibodies (short-lived plasma cells of B-cell origin) might form the basis of a novel treatment. Why not target cells of the B-cell lineage, thereby eliminating the short-lived plasma cells that would otherwise produce autoantibodies? This might be achieved with rituximab, a monoclonal antibody directed against the CD20 molecule found on pre-B and mature B cells.⁷ Our group first successfully deployed this strategy in the early 2000s, followed by an open-label pilot study.⁸⁻¹⁰

The RAVE trial

The Rituximab in ANCA-Associated Vasculitis (RAVE) trial was a multicenter, randomized, placebo-controlled trial that compared rituximab for remission induction and maintenance with standard therapy consisting of cyclophosphamide followed by azathioprine in patients with severe AAV.¹¹ The results of a pilot trial in 2006¹⁰ set the stage for the RAVE trial, which hypothesized that treatment with rituximab plus glucocorticoids would not be inferior to daily cyclophosphamide plus glucocorticoids. Both would induce remission and permit discontinuation of prednisone after 6 months.

Nine centers enrolled a total of 197 patients with severe GPA or microscopic polyangiitis (MPA), all positive for ANCA, with active disease severe enough to warrant treatment with prednisone and cyclophosphamide. All participants received 1 to 3 g of methylprednisolone intravenously followed by prednisone (1 mg/kg per day). The treatment group received rituximab (375 mg/m² once weekly for 4 weeks) and the control group received standard therapy with cyclophosphamide (2 mg/kg per day) followed by azathioprine (2 mg/kg per day) after 3 to 6 months when remission was achieved.

The primary end point was complete remission, defined as a Birmingham Vasculitis Activity Score for Wegener's Granulomatosis (BVAS/WG) of 0 and successful tapering of prednisone by 6 months. Secondary

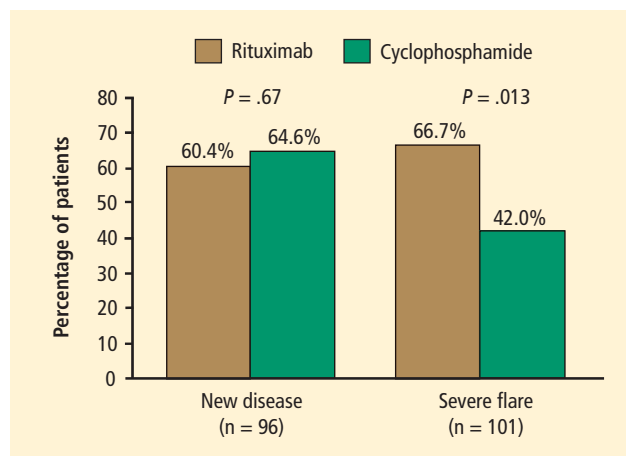


FIGURE 1. Patients who entered the Rituximab in ANCA-Associated Vasculitis (RAVE) trial with a new diagnosis showed no significant difference in their responses to rituximab compared with cyclophosphamide. Among patients who entered the trial with a severe disease flare, however, the efficacy of rituximab was superior to that of cyclophosphamide in achieving complete remission.¹¹

end points included rates of disease flares, cumulative glucocorticoid doses, rates of adverse events, and Medical Outcomes Study 36-item short-form health survey (SF-36, a measure of quality of life) scores. Among patients receiving rituximab, 64% reached the primary end point compared with 53% of patients in the control group. Rituximab was judged not inferior to standard therapy.

Results were similar for the secondary end point of disease remission while taking less than 10 mg/d of prednisone, with 71% of rituximab patients and 62% of control-group patients achieving remission. Rituximab was also as effective as cyclophosphamide in the treatment of patients with major renal disease or alveolar hemorrhage. Most strikingly, rituximab proved superior to the cyclophosphamide-based regimen for inducing remission in patients who entered the trial with relapsing disease (67% rituximab versus 42% cyclophosphamide) (**Figure 1**). Those who entered the trial with a new diagnosis did not show the same difference in efficacy.

Rituximab also proved significantly more effective than cyclophosphamide for patients who had proteinase-3 (PR3) ANCA, whereas the efficacy of both agents was equivalent among patients who had myeloperoxidase ANCA. Patients in the cyclophosphamide arm experienced more leukopenia compared with the rituximab arm, but this did not lead to more infections.

In summary, the RAVE trial showed that rituximab matched the efficacy of cyclophosphamide (standard therapy) in inducing remission in patients with severe AAV. The results held true for subsets of patients with major renal disease and those with alveolar hemorrhage. Most strikingly, among patients who entered the trial

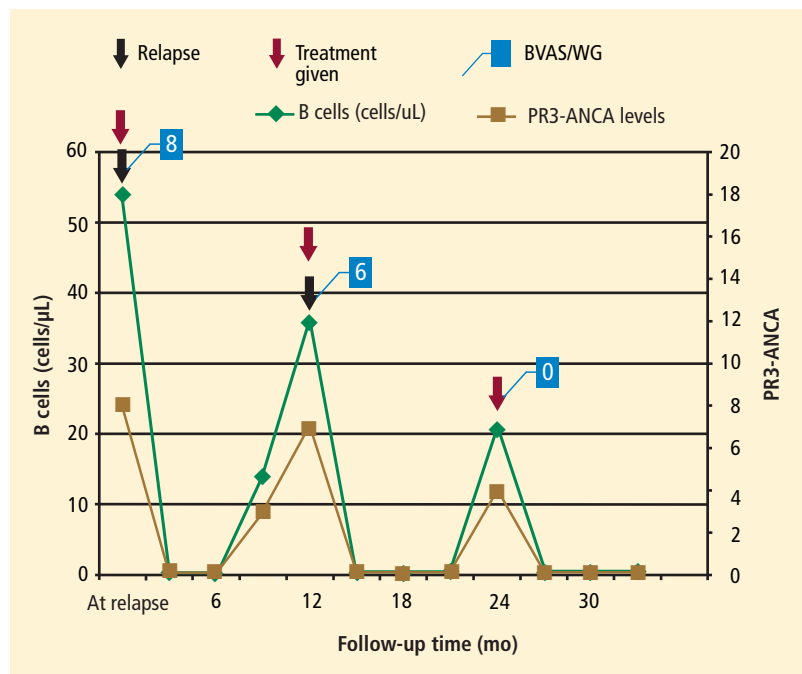


FIGURE 2. In this representative patient with relapsing granulomatosis with polyangiitis, investigators made retreatment decisions based on B-cell counts and antineutrophil cytoplasmic antibody (ANCA) levels. After treatment (red arrow), B-cell counts became depleted and ANCA levels decreased. Over time, B cells and ANCA levels again increased. Without treatment, patients experience flares, although less severe than previous flares. When treatment is reinitiated, both B cells and ANCA levels decrease and flares can be prevented. BVAS/WG = Birmingham Vasculitis Activity Score for Wegener's Granulomatosis; PR3 = proteinase-3

with a severe relapse, those who received rituximab responded better than those treated with cyclophosphamide. There were no significant differences in flare rates by 6 months and no difference in the rate of severe adverse events. However, participants receiving cyclophosphamide experienced more selected adverse events, particularly leukopenias.

Clinically speaking, rituximab represents the first proven alternative to cyclophosphamide for remission induction in this patient population. The treatment presents the preferred option for patients interested in preserving fertility or who need to be re-treated for a severe disease flare. Based on these data, the US Food and Drug Administration recently extended the labeling of rituximab for treatment of GPA and MPA.

The RITUXVAS trial

The European Vasculitis Study Group (EUVAS) launched another trial comparing the efficacy of rituximab with cyclophosphamide for remission induction.¹² The trial design differed from that of the RAVE trial in that investigators did not discontinue prednisone in all patients, followed patients for 12 months, and assessed sustained remission as the primary end point. In this trial, patients in the rituximab arm also received

two single intravenous cyclophosphamide infusions, and cyclophosphamide in the control arm was given intravenously. All 44 patients enrolled in the trial and randomized 3:1 to the rituximab versus the cyclophosphamide control arm were ANCA-positive and had active renal disease. The patient population overall was older and had more severe renal disease than the patients enrolled in the RAVE trial. Overall, one course of rituximab achieved the same results as 6 months of intravenous pulse cyclophosphamide followed by oral azathioprine in terms of rate of sustained remission at 12 months, time to relapse, improvement of renal function, and rate of adverse events.

Mayo Clinic cohort study

Our group at Mayo Clinic evaluated the safety and effectiveness of rituximab when used repeatedly in order to maintain long-term remission.¹³ The study involved 53 patients who had a long-term (10 years, on average) diagnosis of refractory AAV. The patients received, on average, four courses of rituximab. All of these patients had GPA and all but one were PR3-ANCA-positive.

In these patients, treatment with rituximab led to depletion of B cells (Figure 2).

When B-cell numbers returned to normal approximately 6 to 11 months after treatment, ANCA levels also increased. Patients in whom no treatment was initiated subsequently suffered flares. If treatment was reinitiated, both B cells and ANCA levels dropped and flares were prevented. Overall, patients tolerated the infusions well with a surprisingly low rate of infection.

In this cohort, rituximab was effective and safe for induction and maintenance of remission in patients with relapsing GPA. The study showed that B-cell depletion effectively maintains remission in these patients, supporting the notion that B cells play an important role in GPA. Because rituximab works by depleting B cells and ANCA, timing of re-treatment can be individualized based on B-cell counts and ANCA levels. Thus, rituximab represents a promising alternative to standard therapy and a means for long-term patient management, particularly for those in whom other agents have failed to achieve or maintain remission in the past.

On a cautionary note, rituximab is an immunosuppressive agent. Risk of infection during treatment seems similar to that associated with carefully monitored cyclophosphamide followed by azathioprine. To avoid complications, physicians should also maintain *Pneumocystis* prophylaxis for at least the duration of B-cell depletion.

CONCLUSION

Enhanced understanding of the mechanism of action of cyclophosphamide has led to investigation of the role of B cells in the development of AAV and, from there, to the potential for treatment with biologics such as rituximab. Rituximab is equivalent in efficacy to cyclophosphamide for remission induction in AAV. It effectively restores remission and prevents relapse, and it is a better option than cyclophosphamide for PR3-ANCA-associated relapsing vasculitis. Future investigations should further address how to best prevent relapses after B-cell reconstitution.

REFERENCES

1. Walton EW. Giant-cell granuloma of the respiratory tract (Wegener's granulomatosis). *Br Med J* 1958; 2:265–270.
2. Hoffman GS, Kerr GS, Leavitt RY, et al. Wegener granulomatosis: an analysis of 158 patients. *Ann Intern Med* 1992; 116:488–498.
3. Reinhold-Keller E, Beuge N, Latza U, et al. An interdisciplinary approach to the care of patients with Wegener's granulomatosis: long-term outcome in 155 patients. *Arthritis Rheum* 2000; 43:1021–1032.
4. Jayne D, Rasmussen N, Andrassy K, et al. A randomized trial of maintenance therapy for vasculitis associated with antineutrophil cytoplasmic autoantibodies. *N Engl J Med* 2003; 349:36–44.
5. Cupps TR, Edgar LC, Fauci AS. Suppression of human B lymphocyte function by cyclophosphamide. *J Immunol* 1982; 128:2453–2457.
6. Popa ER, Stegeman CA, Bos NA, Kallenberg CG, Tervaert JW. Differential B- and T-cell activation in Wegener's granulomatosis. *J Allergy Clin Immunol* 1999; 103:885–894.
7. Salama AD, Pusey CD. Drug insight: rituximab in renal disease and transplantation. *Nat Clin Pract Nephrol* 2006; 2:221–230.
8. Specks U, Fervenza FC, McDonald TJ, Hogan MC. Response of Wegener's granulomatosis to anti-CD20 chimeric monoclonal antibody therapy. *Arthritis Rheum* 2001; 44:2836–2840.
9. Keogh KA, Wylam ME, Stone JH, Specks U. Induction of remission by B lymphocyte depletion in eleven patients with refractory antineutrophil cytoplasmic antibody-associated vasculitis. *Arthritis Rheum* 2005; 52:262–268.
10. Keogh KA, Ytterberg SR, Fervenza FC, Carlson KA, Schroeder DR, Specks U. Rituximab for refractory Wegener's granulomatosis: report of a prospective, open-label pilot trial [published online ahead of print October 13, 2005]. *Am J Respir Crit Care Med* 2006; 173:180–187. doi: 10.1164/rccm.200507-1144OC
11. Stone JH, Merkel PA, Spiera R, et al. Rituximab versus cyclophosphamide for ANCA-associated vasculitis. *N Engl J Med* 2010; 363:221–232.
12. Jones RB, Tervaert JW, Hauser T, et al. Rituximab versus cyclophosphamide in ANCA-associated renal vasculitis. *N Engl J Med* 2010; 363:211–220.
13. Cartin-Ceba R, Golbin J, Keogh KA, et al. Rituximab for remission induction and maintenance in granulomatosis with polyangiitis (Wegener's): a single-center ten-year experience [published online ahead of print June 21, 2012]. *Arthritis Rheum*. doi: 10.1002/art.34584

Correspondence: Ulrich Specks, MD, Division of Pulmonary and Critical Care Medicine, Mayo Clinic College of Medicine, 200 First St. SW, Rochester, MN 55905; specks.ulrich@mayo.edu