



**EDUCATIONAL OBJECTIVE:** Readers will keep a high index of suspicion for acute aortic dissection in patients who present with chest pain

**ALAN C. BRAVERMAN, MD**

Alumni Endowed Professor in Cardiovascular Diseases;  
Professor of Medicine; Director, Marfan Syndrome Clinic;  
Director, Inpatient Cardiology Firm; Cardiovascular Division,  
Department of Medicine, Washington University School of  
Medicine, St. Louis, MO

# Aortic dissection: Prompt diagnosis and emergency treatment are critical

## ABSTRACT

Diagnosing aortic dissection requires a high index of suspicion, as it may mimic other more common conditions that cause chest pain. Prompt diagnosis is key, as it requires emergency evaluation and treatment for optimal chances of survival. This paper reviews key clinical features as well as laboratory and imaging tests.

## KEY POINTS

Aortic surgery is the treatment of choice for dissection of the ascending aorta, whereas dissection of the descending aorta is initially managed medically.

Look for an underlying genetic predisposition to aortic disease and, in many instances, screen first-degree relatives for aortic disease.

Long-term management requires serial imaging of the aorta, blood pressure control, and, for many, future aortic procedures.

Measuring the D-dimer levels may help in decision-making for appropriate imaging in patients presenting with chest pain, as an elevated level raises the suspicion of dissection. However, more study of this and other biomarkers is needed.

Advances in molecular genetics and the biology of the aortic wall promise to improve the diagnosis and prognosis of aortic disease.

A 50-YEAR-OLD MAN developed severe chest pain and collapsed to the floor. The pain was sudden in onset, was burning in quality, and was located in the center of his chest. Emergency medical services arrived a few minutes later and found the patient diaphoretic and cyanotic, with an initial blood pressure of 74/54 mm Hg and a heart rate of 125 beats per minute. He was rushed to the hospital.

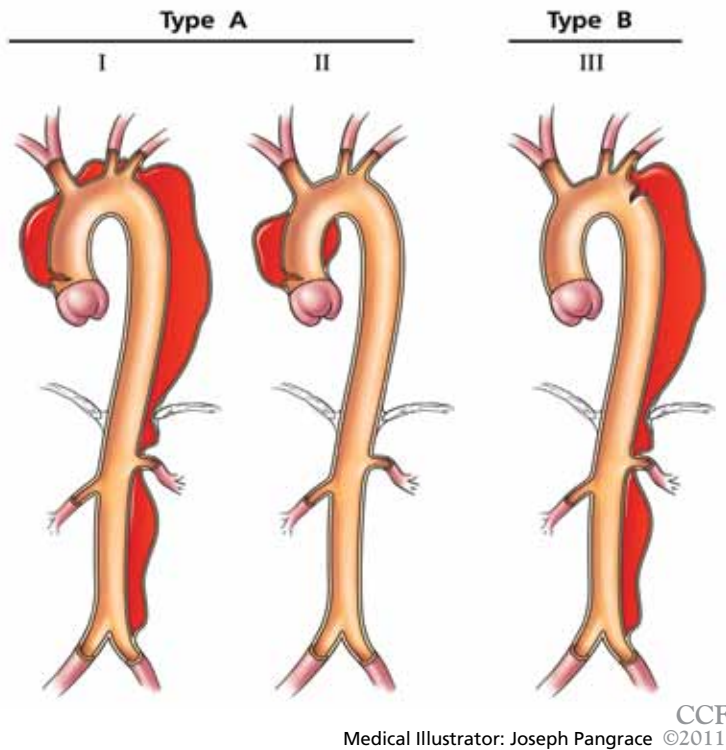
His medical history was unremarkable. He smoked one pack of cigarettes per day for 20 years. His father died of a “heart attack” at age 52.

In the emergency department he underwent echocardiography with a portable handheld unit, which showed a pericardial effusion and cardiac tamponade. He was sent for emergency computed tomography of the chest, which revealed an aneurysm of the aortic root and acute type A (Stanford classification) aortic dissection with hemopericardium.

He underwent emergency cardiac surgery. At the time of surgery, he was in cardiogenic shock from aortic dissection complicated by severe aortic regurgitation and cardiac tamponade with hemopericardium. The aortic valve was trileaflet. A 27-mm St. Jude composite valve graft root replacement was performed.

The patient did well and was discharged home 7 days after surgery. Pathologic study of the aorta revealed cystic medial degeneration. He did not have any features of Marfan syndrome or Loeys-Dietz syndrome. His three children underwent evaluation, and each had a normal physical examination and echocardiographic test results.

doi:10.3949/cjcm.78a.11053



**FIGURE 1.** Two classification schemes for acute aortic dissection. Types I, II, and III represent the DeBakey classification; the Stanford classification uses the labels A and B. The darker areas on the aorta show the locations of the dissection. Type A in the Stanford scheme involves the ascending aorta; type B does not.

## A HIGH INDEX OF SUSPICION IS CRITICAL

Acute aortic dissection is the most common aortic catastrophe, with an incidence estimated at 5 to 30 per 1 million people per year, amounting to nearly 10,000 cases per year in the United States.<sup>1-4</sup>

The diagnosis of acute aortic dissection has many potential pitfalls.<sup>2,3</sup> Aortic dissection may mimic other more common conditions, such as coronary ischemia, pleurisy, heart failure, stroke, and acute abdominal illness. Because acute aortic dissection may be rapidly fatal, one must maintain a high index of suspicion.<sup>2,3</sup> Prompt diagnosis and emergency treatment are critical.

## WHAT CAUSES AORTIC DISSECTION?

One hypothesis is that acute aortic dissection is caused by a primary tear in the aortic intima, with blood from the aortic lumen penetrating

into the diseased media leading to dissection and creating a true and false lumen.<sup>2</sup> Another is that rupture of the vasa vasorum leads to hemorrhage in the aortic wall with subsequent intimal disruption, creating the intimal tear and aortic dissection.

Once a dissection starts, pulsatile flow of blood within the aortic wall causes it to extend. The dissection flap may be localized, but it often spirals the entire length of the aorta. Distention of the false lumen with blood may cause the intimal flap to compress the true lumen and potentially lead to malperfusion syndromes.

## CLASSIFIED ACCORDING TO LOCATION

Several classification schemes are used for aortic dissection and are based on which segment of the aorta is involved (FIGURE 1).<sup>2,3</sup>

It is important to recognize the location of the dissection, as the prognosis and treatment depend on whether the ascending aorta is involved.<sup>2,3</sup> For classification purposes, the ascending aorta is the portion proximal to the brachiocephalic artery, while the descending aorta is the portion distal to the left subclavian artery.<sup>3</sup>

**The DeBakey classification** defines a type I aortic dissection as one that begins in the ascending aorta and extends at least to the aortic arch or beyond. Type II dissections involve the ascending aorta only, while type III dissections begin in the descending aorta, most often just distal to the left subclavian artery.

**The Stanford classification** scheme divides dissections into type A and type B. Type A dissections involve the ascending aorta, while type B dissections do not involve the ascending aorta.

Which classification scheme is used is not important. However, identifying patients with dissection of the ascending aorta (DeBakey type I or type II or Stanford type A) is critical, as emergency cardiac surgery is recommended for this type of dissection.<sup>2,3</sup> For the purposes of this paper, the Stanford classification scheme will be used.

Dissection that involves the ascending aorta most commonly occurs in people ages 50 to 60, whereas acute dissection of the descending aorta typically occurs in people 10 years older.<sup>1,2</sup>

An acute aortic dissection is one that has occurred within 2 weeks of symptom onset. A chronic dissection is one that occurred more than 2 weeks after symptoms began.

## ■ DISEASES AND CONDITIONS ASSOCIATED WITH AORTIC DISSECTION

Many diseases and conditions are associated with aortic dissection (TABLE 1)<sup>2,3</sup>:

**Hypertension** and disorders leading to disruption of the normal structure and function of the aortic wall. About 75% of patients with acute aortic dissection have underlying hypertension.<sup>1-3</sup>

**Cystic medial degeneration** is a common pathologic feature in many cases of aortic dissection.

**Genetic disorders** that lead to aortic aneurysm and dissection include Marfan syndrome, Loeys-Dietz syndrome, familial thoracic aortic aneurysm syndrome, bicuspid aortic valve, Turner syndrome, and vascular Ehlers-Danlos syndrome (TABLE 2).<sup>2,3,5</sup> Some of these disorders may involve abnormalities in signaling pathways, such as transforming growth factor beta, and others affect aortic smooth muscle cell contractile function.<sup>2,3</sup> Not infrequently, acute aortic dissection may be the inciting event that brings the patient with one of these genetic conditions to initial clinical attention, highlighting the importance of recognizing these disorders.

**Cocaine use and intense weight-lifting** increase the shear stresses on the aorta.<sup>2,3</sup>

**Inflammatory aortic diseases** such as giant cell arteritis.

**Pregnancy** can be complicated by aortic dissection, usually in the setting of an underlying aortopathy.<sup>5</sup>

**Iatrogenic aortic dissection** accounts for about 4% of cases, as a result of cardiac surgery, catheterization, stenting, or use of an intra-aortic balloon pump.<sup>1</sup>

**Aortic aneurysm.** Patients with thoracic aortic aneurysm are at higher risk of aortic dissection, and the larger the aortic diameter, the higher the risk.<sup>2,3,6</sup> In the International Registry of Acute Aortic Dissection (IRAD), the average size of the aorta was about 5.3 cm at the time of acute dissection. Importantly, about 40% of acute dissections of the ascend-

TABLE 1

## Risk factors for aortic dissection

### Hypertension

#### Genetically triggered thoracic aortic diseases and congenital disorders

Marfan syndrome  
Bicuspid aortic valve  
Loeys-Dietz syndrome  
Hereditary thoracic aortic aneurysm or dissection  
Vascular Ehlers-Danlos syndrome  
Coarctation of the aorta  
Turner syndrome  
Tetralogy of Fallot

### Atherosclerosis

Penetrating atherosclerotic ulcer

### Trauma (blunt or iatrogenic)

Catheter or stent  
Intra-aortic balloon pump  
Aortic or vascular surgery  
Motor vehicle accident  
Coronary artery bypass surgery or aortic valve replacement

### Cocaine use

### Inflammatory or infectious disease

Giant cell arteritis  
Takayasu arteritis  
Behçet disease  
Aortitis  
Syphilis

### Pregnancy

ADAPTED WITH PERMISSION FROM: BRAVERMAN AC, THOMPSON R, SANCHEZ L. DISEASES OF THE AORTA. IN: BONOW RO, MANN DL, ZIPES DP, LIBBY P. BRAUNWALD'S HEART DISEASE, 9TH EDITION. ELSEVIER, PHILADELPHIA, PA, 2011.

ing aorta occur in patients with ascending aortic diameters less than 5.0 cm.<sup>7,8</sup>

Thus, many factors are associated with acute dissection, and specific reasons leading to an individual's susceptibility to sudden dissection are poorly understood.

## ■ CLINICAL FEATURES OF ACUTE AORTIC DISSECTION

Because the symptoms of acute dissection may mimic other, more common conditions, one of the most important factors in the diagnosis of aortic dissection is a high clinical suspicion.<sup>1-3</sup>

**TABLE 2**

**Genetic disorders associated with aortic dissection**

**Marfan syndrome**

Autosomal dominant connective tissue disorder caused by a defect in the gene *FBN1*. Aortic root aneurysms most common. Patients with Marfan syndrome are often very tall and thin; may have long fingers, toes, arms, and legs; chest wall deformities; scoliosis; mitral valve prolapse; ocular features include lens dislocation, myopia, or retinal detachment.

**Bicuspid aortic valve**

Congenital condition affecting about 1% of the general population. Associated with aortic root and ascending aortic aneurysms due to underlying aortopathy. Patients with a bicuspid aortic valve are at risk for aortic dissection (a 5 to 10 times higher risk than in the general population). May be familial in about 10% of cases.

**Loeys-Dietz aneurysm syndrome**

Autosomal dominant disorder caused by mutations in *TGFBR1* or *TGFBR2* leading to arterial tortuosity, wide-set eyes (hypertelorism), bifid or broad uvula, cleft palate, and aortic dissection and aneurysm involving branch vessels. Soft, velvety skin and easily visible veins may be present.

**Familial thoracic aortic aneurysm and dissection**

Autosomal dominant disorder with predominant feature of thoracic aortic aneurysm and dissection. Variable penetrance and expressivity lead to wide ranges of age of onset and clinical course. May be associated with patent ductus arteriosus, cerebral aneurysm, bicuspid aortic valve, or livedo reticularis. Caused by mutations in various genes including *ACTA 2*, *MYH11*, *TGFBR1* and *TGFBR2*, *FBN1*.

**Vascular Ehlers-Danlos syndrome (type 4)**

Autosomal dominant genetic disorder that results from a mutation in gene *COL3A1* leading to abnormal collagen synthesis. Features include hyperflexible fingers, hyperlucent skin with visible veins, easy bruisability, and varicose veins. Patients are at risk for spontaneous arterial dissection and rupture, often in medium-sized arteries, and intestinal or uterine rupture.

**Turner syndrome**

Chromosomal disorder affecting 1 in 2,000 live-born girls caused by the complete or partial loss of a second sex chromosome (XO, Xp). Features include short stature, webbed neck, and underlying cardiovascular defects including bicuspid aortic valve in 25% and coarctation of the aorta in 12%. Turner patients are at increased risk of aortic dissection. Because of short stature, Turner patients may suffer aortic dissection at relatively small aortic dimensions, and this should be taken into account in planning preventive surgery.

**The prognosis and treatment depend on whether the ascending aorta is involved**

**What is the pretest risk of disease?**

Recently, the American College of Cardiology (ACC) and the American Heart Association (AHA) released joint guidelines on thoracic aortic disease.<sup>3</sup> These guidelines provide an approach to patients who have complaints that may represent acute thoracic aortic dissection, the intent being to establish a pretest risk of disease to be used to guide decision-making.<sup>3</sup>

The focused evaluation includes specific

questions about underlying conditions, symptoms, and findings on examination that may greatly increase the likelihood of acute dissection. These include:

- High-risk conditions and historical features associated with aortic dissection, such as Marfan syndrome and other genetic disorders (TABLE 2), bicuspid aortic valve, family history of thoracic aortic aneurysm or dissection, known thoracic aortic aneurysm, and recent aortic manipulation



- Pain in the chest, back, or abdomen with high-risk features (eg, abrupt onset, severe intensity, or a ripping or tearing quality)
- High-risk findings on examination (eg, pulse deficits, new aortic regurgitation, hypotension, shock, or systolic blood pressure differences).

Using this information, expedited aortic imaging and treatment algorithms have been devised to improve the diagnosis.<sup>3</sup>

Using the IRAD database of more than 2,500 acute dissections, the diagnostic algorithm proposed in the ACC/AHA guidelines was shown to be highly sensitive (about 95%) for detecting acute aortic dissection.<sup>4</sup> In addition, using this score may expedite evaluation by classifying certain patients as being at high risk of acute dissection.<sup>3,4</sup>

Important to recognize is that almost two-thirds of patients who suffered dissection in this large database did not have one of the “high-risk conditions” associated with dissection.<sup>4</sup> Additionally, the specificity of the ACC/AHA algorithm is unknown, and further testing is necessary.<sup>4</sup>

### Acute onset of severe pain

More than 90% of acute dissections present with acute pain in the chest or the back, or both.<sup>1-3</sup> The pain is usually severe, of sudden onset, and often described as sharp or, occasionally, tearing, ripping, or stabbing. The pain usually differs from that of coronary ischemia, being most severe at its onset as opposed to the less intense, crescendo-like pain of angina or myocardial infarction. The pain may migrate as the dissection progresses along the length of the aorta or to branch vessels. It may abate, leading to a false sense of security in the patient and the physician.<sup>3</sup> “Painless” dissection occurs in a minority, usually in those with syncope, neurologic symptoms, or heart failure.<sup>1-3</sup>

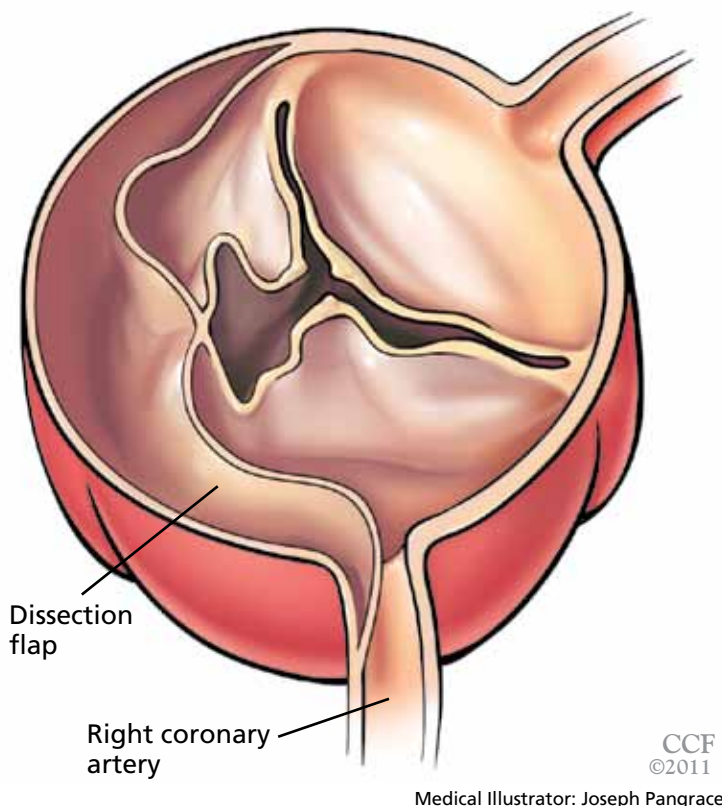
The patient with acute dissection may be anxious and may feel a sense of doom.

Acute heart failure, related to severe aortic regurgitation, may be a predominant symptom in dissection of the ascending aorta.

Syncope may occur as a result of aortic rupture, hemopericardium with cardiac tamponade, or acute neurologic complications.

Vascular insufficiency may occur in any branch vessel, leading to clinical syndromes

## A complication of acute type A aortic dissection



**FIGURE 2.** Aortic regurgitation complicating acute type A aortic dissection. The dissection flap distorts the normal alignment of the aortic leaflet, leading to malcoaptation of the aortic valve and subsequent aortic regurgitation. In this example, the dissection flap extends into the ostium of the right coronary artery.

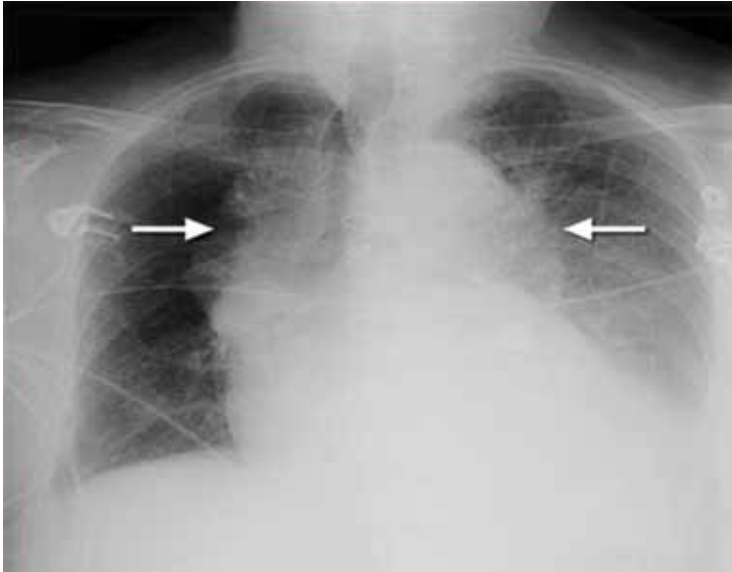
that include acute myocardial infarction, stroke, paraplegia, paraparesis, mesenteric ischemia, and limb ischemia.

### ■ PHYSICAL FINDINGS CAN VARY WIDELY

Findings on physical examination in acute aortic dissection vary widely depending on underlying conditions and on the specific complications of the dissection.

Although the classic presentation is acute, severe pain in the chest or back in a severely hypertensive patient with aortic regurgitation and pulse deficits, most patients do not have all these characteristics.<sup>4</sup> Most patients with type B dissection are hypertensive on presentation, but many with type A dissection present with normal blood pressure or hypotension.<sup>1</sup> Pulse

## Type A aortic dissection



**FIGURE 3.** Chest radiography in acute type A aortic dissection shows a widened mediastinum and enlargement of the shadows of the ascending aorta and descending aorta (arrows).

REPRODUCED WITH PERMISSION FROM: BRAVERMAN AC, THOMPSON R, SANCHEZ L. DISEASES OF THE AORTA. IN, BONOW RO, MANN DL, ZIPES DP, LIBBY P. BRAUNWALD'S HEART DISEASE, 9TH EDITION. ELSEVIER, PHILADELPHIA, PA, 2011.

**High-risk conditions:**  
**Marfan syndrome, bicuspid aortic valve, family or personal history of thoracic aortic aneurysm or dissection, recent aortic manipulation**

deficits (unequal or absent pulses) are reported in 10% to 30% of acute dissections and may be intermittent as the dynamic movement of the dissection flap interferes with branch vessel perfusion.<sup>1-3</sup>

**Aortic regurgitation** is present in about 40% of patients with acute type A dissection and may be related to one of several mechanisms (FIGURE 2)<sup>1,2</sup>:

- Aortic leaflet prolapse or distortion of the leaflet alignment
- Malcoaptation of the aortic leaflets from dilation of the aortic root and annulus
- Prolapse of the intimal flap across the aortic valve, interfering with valve function
- Preexisting aortic regurgitation from underlying aortic root aneurysm or primary aortic valve disease (such as a bicuspid aortic valve).

**Neurologic manifestations** are most common in dissection of the ascending aorta and are particularly important to recognize, as they may dominate the clinical

presentation and lead to delay in the diagnosis of dissection.<sup>2,3</sup> Neurologic syndromes include:

- Persistent or transient ischemic stroke
- Spinal cord ischemia
- Ischemic neuropathy
- Hypoxic encephalopathy.

These manifestations are related to malperfusion to branches supplying the brain, spinal cord, or peripheral nerves.<sup>9</sup>

**Syncope** is relatively common in aortic dissection and may be related to acute hypotension caused by cardiac tamponade or aortic rupture, cerebral vessel obstruction, or activation of cerebral baroreceptors.<sup>2,9</sup> It is important to consider aortic dissection in the differential diagnosis in cases of unexplained syncope.<sup>3</sup>

Aortic dissections may extend into the abdominal aorta, leading to vascular complications involving one or more branch vessels.<sup>10</sup> The renal artery is involved in at least 5% to 10% of cases and may lead to **renal ischemia, infarction, renal insufficiency, or refractory hypertension.**<sup>2</sup> **Mesenteric ischemia or infarction** occurs in about 5% of dissections, may be difficult to diagnose, and is particularly dangerous.<sup>2,8</sup> Aortic dissection may extend into the iliac arteries and may cause **acute lower extremity ischemia.**

**Acute myocardial infarction** due to involvement of the dissection flap causing malperfusion of a coronary artery occurs in 1% to 7% of acute type A aortic dissections.<sup>1-3</sup> The right coronary artery (FIGURE 2) is most commonly involved, leading to acute inferior myocardial infarction. Acute myocardial ischemia and infarction in the setting of dissection may lead to a delay in the diagnosis of dissection and to bleeding complications from antiplatelet and anticoagulant drugs given to treat the acute coronary syndrome.

**Cardiac tamponade**, occurring in about 10% of acute type A dissections, portends a higher risk of death.<sup>2,3</sup>

Additional clinical features of aortic dissection include a **left-sided pleural effusion**, usually related to an inflammatory response. An **acute hemothorax** may occur from rupture or leaking of a descending aortic dissection.

## FINDINGS ON RADIOGRAPHY AND ELECTROCARDIOGRAPHY

Chest radiography may provide the first clues of aortic dissection. The most frequent findings are a widening of the aortic shadow or mediastinum or an abnormal aortic contour (FIGURE 3).<sup>2,3</sup> However, radiographic findings are nonspecific and are subject to interobserver variability. Also, importantly, the chest radiograph is normal in 12% to 15% of cases of acute aortic dissection.<sup>1,3</sup>

Electrocardiography usually has normal or nonspecific findings, unless acute myocardial infarction complicates the dissection.

## D-DIMER LEVELS

Biomarkers for the diagnosis of acute aortic dissection are of great interest.

D-dimer levels rise in acute aortic dissection as they do in pulmonary embolism.<sup>11</sup> A D-dimer level greater than 1,600 ng/mL within the first 6 hours has a very high positive likelihood ratio for dissection, so this test may be useful in identifying patients with a high probability for dissection. In the first 24 hours after symptom onset, a D-dimer level of less than 500 ng/mL has a negative predictive value of 95%. Thus, elevations in D-dimer may help decide which imaging to perform in a patient presenting with chest pain or suspicion of dissection.<sup>11</sup>

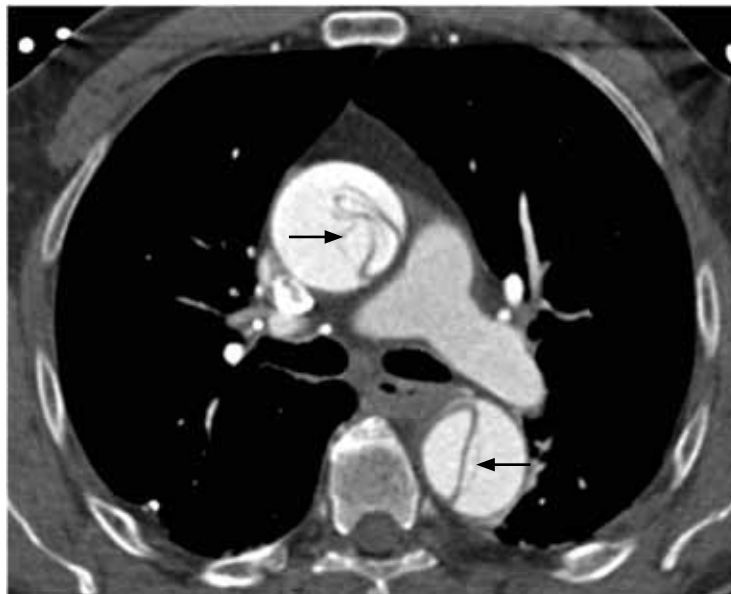However, D-dimer levels may not be elevated in dissection variants, such as aortic intramural hematoma or penetrating aortic ulcer. Additionally, once 24 hours have elapsed since the dissection started, D-dimer levels may no longer be elevated. The current ACC/AHA guidelines on thoracic aortic disease concluded that the D-dimer level cannot be used to rule out aortic dissection in high-risk individuals.<sup>3</sup>

Additional studies may clarify the appropriate role of the D-dimer assay in diagnosing aortic dissection.

## DEFINITIVE IMAGING STUDIES: CT, MRI, TEE

Contrast-enhanced computed tomography (CT), magnetic resonance imaging (MRI), and transesophageal echocardiography (TEE)

### Type A aortic dissection



**FIGURE 4.** Contrast-enhanced computed tomography in acute type A aortic dissection shows a complex intimal flap in the ascending aorta (upper arrow). The intimal flap is also visualized in the descending aorta (lower arrow).

all have very high sensitivity and specificity for the diagnosis of aortic dissection.<sup>2,3</sup> The choice of imaging study often depends on the availability of these studies, with CT and TEE being the most commonly performed initial studies.

**Contrast-enhanced CT** is the test most commonly used to diagnose aortic dissection (FIGURE 4). It is best performed with electrocardiographic gating or multidetector scanning to eliminate pulsation artifacts. The use of intravenous contrast is necessary to visualize the true and false channels; noncontrast studies may miss aortic dissection. CT may also visualize hemopericardium, aortic rupture, and branch vessel involvement.

**MRI** is outstanding for detecting and following aortic dissection, but it is usually not the initial study performed because of the time required for image acquisition and because it is generally not available on an emergency basis.

**TEE** has the advantage of being portable, but it requires adequate sedation and skilled personnel. It may define the mechanism of aortic regurgitation in acute dissection, and it may visualize the coronary ostia (FIGURE 5). Another advantage is that it can ascertain the

**The patient with acute dissection may be anxious and feel a sense of doom**

**TABLE 3**

**Indications for surgical, endovascular, and drug therapy in acute aortic dissection**

**Surgical therapy**

Acute type A aortic dissection  
Retrograde dissection into the ascending aorta

**Surgical therapy or endovascular therapy, or both**

Acute type B aortic dissection complicated by:

- Visceral ischemia
- Limb ischemia
- Rupture or impending rupture
- Aneurysmal dilation
- Refractory pain

**Medical therapy**

Uncomplicated type B aortic dissection  
Uncomplicated isolated arch dissection

REPRODUCED WITH PERMISSION FROM: BRAVERMAN AC, THOMPSON R, SANCHEZ L. DISEASES OF THE AORTA. IN, BONOW RO, MANN DL, ZIPES DP, LIBBY P. BRAUNWALD'S HEART DISEASE, 9TH EDITION. ELSEVIER, PHILADELPHIA, PA, 2011.

**Most patients do not have all of the classic features of acute aortic dissection**

functioning of the left and right heart. A disadvantage of TEE is that it may not adequately visualize the distal ascending aorta and aortic arch.

While transthoracic echocardiography (TTE) can detect aortic dissection, its sensitivity is much lower than that of other imaging tests.<sup>2,3</sup> Therefore, negative findings on TTE do not exclude aortic dissection.

**MANAGEMENT OF AORTIC DISSECTION**

When acute aortic dissection is diagnosed, multidisciplinary evaluation and treatment are necessary. Time is of the essence, as the death rate in acute dissection may be as high as 1% per hour during the first 24 hours.<sup>1-3</sup> All patients with acute aortic dissection, whether type A or type B, should be transferred to a tertiary care center with a staff experienced in managing aortic dissection and its complications.<sup>3</sup> Emergency surgery is recommended for type A aortic dissection, whereas type B dissection is generally treated medically unless complications occur.<sup>2,3</sup>

The cornerstone of drug therapy is the prompt reduction in blood pressure with a beta-blocker to reduce shear stresses on the aorta. Intravenous agents such as esmolol

(Brevibloc) or labetalol (Normodyne) are usually chosen. Sodium nitroprusside may be added to beta-blocker therapy for rapid blood pressure control in appropriate patients. The patient may require multiple antihypertensive medications. If hypertension is refractory, one must consider renal artery hypertension due to the dissection causing renal malperfusion.<sup>2</sup> Acute pain may also worsen hypertension, and appropriate analgesia should be used.

**Definitive therapy in acute dissection**

The general recommendations for surgical treatment of acute aortic dissection are listed in **TABLE 3**. The goals are to excise the intimal tear, obliterate the false channel by oversewing the aortic edges, and reconstitute the aorta, usually by placing a Dacron interposition graft.

Patients with acute type A dissection require emergency surgery,<sup>2,3</sup> as they are at risk for life-threatening complications including cardiac tamponade from hemopericardium, aortic rupture, stroke, visceral ischemia, and heart failure due to severe aortic regurgitation. When aortic regurgitation complicates acute type A dissection, some patients are adequately treated by resuspension of the aortic valve leaflets, while others require valve-sparing root replacement or prosthetic aortic valve replacement.

Surgical therapy is associated with a survival benefit compared with medical therapy in acute type A dissection.<sup>1</sup> The 14-day mortality rate for acute type A dissection treated surgically is about 25%.<sup>1</sup> Patients with high-risk features such as heart failure, shock, tamponade, and mesenteric ischemia have a worse prognosis compared with those without these features.<sup>2,12,13</sup>

Acute type B aortic dissection carries a lower rate of death than type A dissection.<sup>1-3</sup> In the IRAD cohort, the early mortality rate in those with type B dissection treated medically was about 10%.<sup>1</sup> However, when complications such as malperfusion, shock, or requirement for surgery occur in type B dissection, the mortality rate is much higher,<sup>2,14</sup> with rates of 25% to 50% reported.<sup>2</sup>

Thus, initial medical therapy is the preferred approach to acute type B dissection, and



surgery or endovascular therapy is reserved for patients with acute complications.<sup>2,3</sup> Typical indications for surgery or endovascular therapy in type B dissection include visceral or limb ischemia, aortic rupture, refractory pain, and aneurysmal dilation (TABLE 3).<sup>2</sup>

### Endovascular therapy in aortic dissection

The high mortality rate with open surgery in acute type B dissection has spurred tremendous interest in endovascular treatments for complications involving the descending aorta and branch vessels.<sup>2</sup>

Fenestration of the aorta and stenting of branch vessels were the earliest techniques used in complicated type B dissection. By fenestrating (ie, opening) the intimal flap, blood can flow from the false lumen into the true lumen, decompressing the distended false lumen.

Endovascular stenting is used for acute aortic rupture, for malperfusion syndromes, and for rapidly enlarging false lumens. Endovascular grafts may cover the area of a primary intimal tear and thus eliminate the flow into the false channel and promote false-lumen thrombosis. Many patients with complicated type B dissection are treated with a hybrid approach, in which one segment of the aorta, such as the aortic arch, is treated surgically, while the descending aorta receives an endovascular graft.<sup>2</sup>

Patients with a type B dissection treated medically are at risk for late complications, including aneurysmal enlargement and subsequent aortic rupture. The Investigation of Stent Grafts in Aortic Dissection (INSTEAD) trial included 140 patients with uncomplicated type B dissection and compared drug therapy with endovascular stent grafting.<sup>15</sup> After 2 years of follow-up, there was no difference in the rate of death between the two treatment groups. Patients receiving endovascular grafts had a higher rate of false-lumen thrombosis.

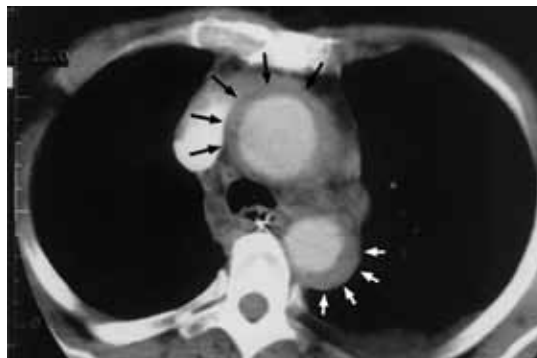More studies are under way to examine the role of endovascular therapy in uncomplicated type B dissection.

## AORTIC DISSECTION VARIANTS

### Aortic intramural hematoma

Aortic intramural hematoma is a form of acute aortic syndrome in which a hematoma

### Type B intramural hematoma



**FIGURE 5.** Contrast-enhanced computed tomography shows a type A intramural hematoma of the aorta. Note the circumferential hematoma involving the ascending aorta (black arrows) and the crescentic hematoma involving the descending aorta (white arrows).

REPRODUCED WITH PERMISSION FROM: BRAVERMAN AC, THOMPSON R, SANCHEZ L. DISEASES OF THE AORTA. IN, BONOW RO, MANN DL, ZIPES DP, LIBBY P. BRAUNWALD'S HEART DISEASE, 9TH EDITION. ELSEVIER, PHILADELPHIA, PA, 2011.

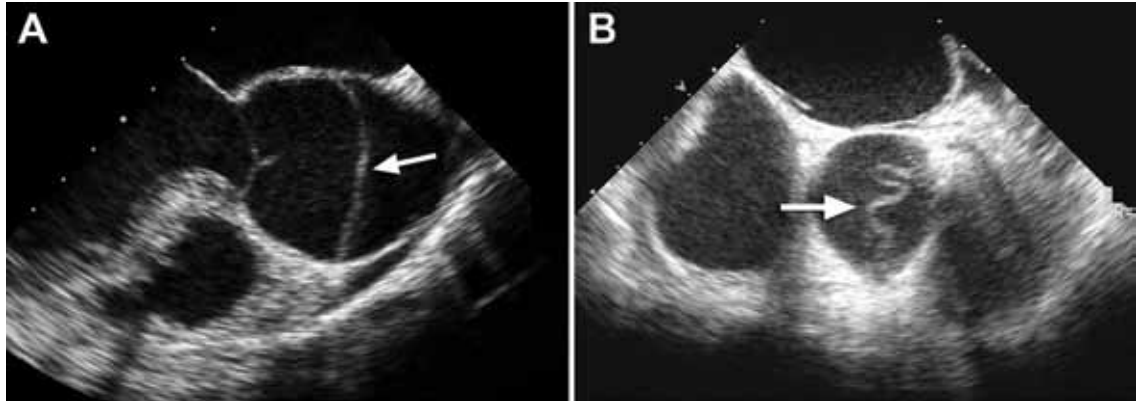
develops in the aortic media and no intimal flap is visualized either by imaging or at surgery.<sup>2,3,16</sup> It is important to recognize this clinical entity in a patient presenting with acute chest or back pain, as sometimes it is mistaken for a “thrombus in a nonaneurysmal aorta.” Intramural hematoma accounts for 5% to 25% of acute aortic syndromes, depending on the study population (it is more common in Asian studies).<sup>2,3,17</sup> It may present with symptoms similar to classic aortic dissection and is classified as type A or type B, depending on whether the ascending aorta is involved.

CT shows high-attenuation crescentic or circumferential thickening of the aortic wall on noncontrast studies and low-attenuation thickening on contrast images (FIGURE 5).<sup>2,3</sup> MRI is also highly accurate in demonstrating intramural hematoma. TEE shows aortic wall thickening with an eccentric aortic lumen and displaced intimal calcification and echolucent spaces in the aortic wall (FIGURE 6).

Patients with an intramural hematoma may progress to having complications such as hemopericardium, classic aortic dissection, aortic rupture, or aneurysmal dilation.<sup>2,3</sup> However, many cases of type B aor-

**An elevated D-dimer level may be present in acute aortic dissection**

## Type A intramural hematoma



**FIGURE 6.** Transesophageal echocardiography of acute type B intramural hematoma (arrows). **(A)** A short-axis view of the descending aorta shows typical crescentic thickening of the aortic wall in intramural hematoma. **(B)** A longitudinal view of the aorta shows an intramural hematoma (arrows).

REPRODUCED WITH PERMISSION FROM: BRAVERMAN AC, THOMPSON R, SANCHEZ L. DISEASES OF THE AORTA. IN: BONOW RO, MANN DL, ZIPES DP, LIBBY P. BRAUNWALD'S HEART DISEASE, 9TH EDITION. ELSEVIER, PHILADELPHIA, PA, 2011.

tic intramural hematoma result in complete resorption of the hematoma over time. In general, like classic aortic dissection, type A intramural hematoma is treated with emergency surgery and type B with initial medical therapy.<sup>2,3</sup>

There are reports from Southeast Asia of successful initial medical therapy for type A intramural hematoma, with surgery used for acute complications.<sup>18</sup> In the Western literature, improved outcomes are reported with initial surgical therapy.<sup>17</sup> Given the unpredictable nature of type A intramural hematoma, most experts recommend surgical therapy for appropriate candidates with acute type A intramural hematoma.<sup>2,3,19</sup>

### Penetrating atherosclerotic ulcer of the aorta

Penetrating atherosclerotic ulcer of the aorta, another acute aortic syndrome, results from acute penetration of an atherosclerotic aortic lesion through the internal elastic lamina into the media.<sup>2,3,20</sup> It is often associated with bleeding into the media, or intramural hematoma. While the ulcer may be found incidentally on imaging studies, especially in patients with severe aortic atherosclerosis, the typical presentation is acute, severe chest or back pain. It occurs most often in the descending aorta and the abdominal aorta.

Penetrating atherosclerotic ulcer may lead to pseudoaneurysm formation, focal aortic dissection, aortic rupture, or late aortic aneurysm.<sup>2</sup>

Penetrating atherosclerotic ulcer has a classic appearance on CT, MRI, and TEE, with focal ulceration and a crater-like outpouching (**FIGURE 7**). Intramural hemorrhage is often present. These lesions have a high propensity for rupture, and because of the focal nature of these lesions, they are often suitable for endovascular therapy.

### LONG-TERM MANAGEMENT AFTER AORTIC DISSECTION

After hospital discharge, patients with aortic dissection require lifelong management. This includes blood pressure control, lifestyle modification, serial imaging of the aorta with CT or MRI, patient education about the condition, and, when appropriate, screening of family members for aortic disease.<sup>5,21</sup>

Reported survival rates after hospitalization for type A dissection are 52% to 94% at 1 year and 45% to 88% at 5 years.<sup>2,22</sup> The 10-year actuarial survival rate for those with acute dissection who survive the acute hospitalization is reported as 30% to 60%. Long-term survival rates after acute type B dissection have been reported at 56% to 92% at 1 year and 48% to 82% at 5 years.<sup>23</sup> Survival

Up to 20% of patients with thoracic aortic dissection will have a first-degree relative with thoracic aortic disease

rates depend on many factors, including the underlying condition, the age of the patient, and comorbidities.

It is important to treat hypertension after aortic dissection, with a goal blood pressure of 120/80 mm Hg or less for most patients. Older studies found higher mortality rates with poorly controlled hypertension. Beta-blockers are the drugs of first choice. Even in the absence of hypertension, long-term beta-blocker therapy should be used to lessen the aortic stress and force of ventricular contraction.

### Genetic evaluation

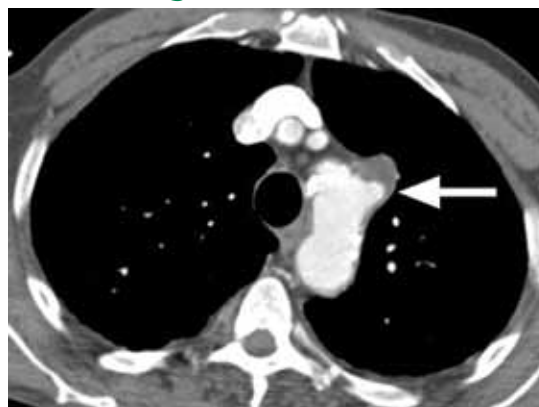Genetically triggered causes of aortic dissection should be considered. In many circumstances, referral to a medical geneticist or other practitioner knowledgeable in these conditions is important when these disorders are being evaluated (TABLE 2).

Many of these disorders have an autosomal dominant inheritance, and the patient should be asked about a family history of aortic disease, aortic dissection, or unexplained sudden death. Features of Marfan syndrome, Loeys-Dietz syndrome, and familial thoracic aortic aneurysm syndromes should be sought. Through comprehensive family studies, it is now recognized that up to 20% of patients with thoracic aortic disease (such as aneurysm or dissection) have another first-degree relative with thoracic aortic disease.<sup>2,3,24</sup> Thus, first-degree relatives of patients with aortic aneurysm or dissection should be screened for thoracic aortic aneurysm disease.

Research into molecular genetics is providing a better understanding of the genetics of aortic dissection.<sup>3</sup> New mutations associated with aortic dissection are being discovered in signaling pathways as well as elements critical for the integrity of the vascular wall.<sup>2,3</sup> However, at present, most patients with aortic dissection will not have a specific identifiable genetic defect.

Not only does genetic testing enable the accurate diagnosis of the affected individual, but also treatments are often based on this diagnosis.<sup>3</sup> Importantly, the identification of a specific gene mutation (ie, in *TGFBR1* or 2, *FBN1*, *ACTA2*, *MYH11*, and *COL3A1*) in an affected individual has the potential to identify other family members at risk.<sup>3</sup>

### Penetrating atherosclerotic ulcer



**FIGURE 7.** Contrast-enhanced computed tomography shows an acute penetrating atherosclerotic aortic ulcer with a focal pseudoaneurysm (arrow) involving the proximal descending aorta.

REPRODUCED WITH PERMISSION FROM: BRAVERMAN AC, THOMPSON R, SANCHEZ L. DISEASES OF THE AORTA. IN: BONOW RO, MANN DL, ZIPES DP, LIBBY P. BRAUNWALD'S HEART DISEASE, 9TH EDITION. ELSEVIER, PHILADELPHIA, PA, 2011.

### Follow-up imaging

It is important to continue to image the aorta after aortic dissection. Patients may develop progressive dilation or aneurysm formation of the dissected aorta, pseudoaneurysm formation after repair, or recurrent dissection. Many patients require additional surgery on the aorta because of late aneurysm formation.

CT or MRI is usually performed at least every 6 months in the first 2 years after dissection and at least annually thereafter. More centers are choosing MRI for long-term follow-up to avoid the repeated radiation exposure with serial CT.

### Patient education

Besides receiving medical therapy and undergoing imaging, patients with aortic dissection should be educated about this condition.<sup>5,21</sup> The patient should be aware of symptoms suggesting dissection and should be instructed to seek attention for any concerning symptoms.

Lifestyle modifications are also important. The patient should be educated about safe activity levels and to avoid heavy isometric exercise, such as weight-lifting. Some patients will have to cease their current occupation because of activity restrictions. ■

## REFERENCES

1. Hagan PG, Nienaber CA, Isselbacher EM, et al. International Registry of Acute Aortic Dissection (IRAD): new insights from an old disease. *JAMA* 2000; 283:897–903.
2. Braverman AC, Thompson R, Sanchez L. Diseases of the aorta. In: Bonow RO, Mann DL, Zipes DP, Libby P. *Braunwald's Heart Disease*, 9th Edition. Elsevier, Philadelphia, 2011.
3. Hiratzka LF, Bakris GL, Beckman JA, et al. American College of Cardiology Foundation/American Heart Association Task Force on Practice Guidelines; American Association for Thoracic Surgery; American College of Radiology; American Stroke Association; Society of Cardiovascular Anesthesiologists; Society for Cardiovascular Angiography and Interventions; Society of Interventional Radiology; Society of Thoracic Surgeons; Society for Vascular Medicine. Guidelines for the management of patients with thoracic aortic disease. *Circulation* 2010; 121:e266–e369.
4. Rogers AM, Herman LK, Booher AM, et al. Sensitivity of the aortic dissection detection risk score, a novel guideline-based tool for identification of acute aortic dissection at initial presentation. Results from the International Registry of Acute Aortic Dissection. *Circulation* 2011; 123:2213–2228.
5. Braverman AC. Acute aortic dissection: clinician update. *Circulation* 2010; 122:184–188.
6. Davies RR, Gallo A, Coady MA, et al. Novel measurement of relative aortic size predicts rupture of thoracic aortic aneurysms. *Ann Thorac Surg* 2006; 81:169–177.
7. Pape LA, Tsai TT, Isselbacher EM, et al. Aortic diameter >5.5 cm is not a good predictor of type A aortic dissection. Observations from the International Registry of Acute Aortic Dissection. *Circulation* 2007; 116:1120–1127.
8. Parish LM, Gorman JH III, Kahn S, et al. Aortic size in acute type A dissection: implications for preventative ascending aortic replacement. *Eur J Cardiothorac Surg* 2009; 35:941–945.
9. Gaul C, Dietrich W, Erbguth FJ. Neurological symptoms in acute aortic dissection: a challenge for neurologists. *Cerebrovasc Dis* 2008; 26:1–8.
10. Upchurch GR, Nienaber C, Fattori R, et al. Acute aortic dissection presenting with primarily abdominal pain: a rare manifestation of a deadly disease. *Ann Vasc Surg* 2005; 19:367–373.
11. Suzuki T, Distant A, Zizza A, et al. Diagnosis of acute aortic dissection by D-dimer: the International Registry of Acute Aortic Dissection substudy on biomarkers (IRAD-bio) experience. *Circulation* 2009; 119:2702–2707.
12. Tsai TT, Trimarchi S, Nienaber CA. Acute aortic dissection: perspectives from the International Registry of Acute Aortic Dissection (IRAD). *Eur J Vasc Endovasc Surg* 2009; 37:149–159.
13. Trimarchi S, Nienaber CA, Rampoldi V, et al. Contemporary results of surgery in acute type A aortic dissection: the International Registry of Acute Aortic Dissection experience. *J Thorac Cardiovasc Surg* 2005; 129:112–122.
14. Trimarchi S, Nienaber CA, Rampoldi V, et al. Role and results of surgery in acute type B aortic dissection. Insights from the International Registry of Acute Aortic Dissection (IRAD). *Circulation* 2006; 114(suppl 1):I-357 – I-364.
15. Nienaber CA, Rousseau H, Eggbrecht H, et al. Randomized comparison of strategies for type B aortic dissection. The Investigation of STent grafts in Aortic Dissection (INSTEAD) Trial. *Circulation* 2009; 120:2519–2528.
16. Evangelista A, Mukherjee D, Mehta RH, et al. Acute intramural hematoma of the aorta. *Circulation* 2005; 111:1063–1070.
17. Pelzel JM, Braverman AC, Hirsch AT, Harris KM. International heterogeneity in diagnostic frequency and clinical outcomes of ascending aortic intramural hematoma. *J Am Soc Echo* 2007; 20:1260–1268.
18. Song JK, Yim JH, Ahn JM, et al. Outcomes of patients with acute type A aortic intramural hematoma. *Circulation* 2009; 120:2046–2052.
19. Harris KM, Pelzel JM, Braverman AC. Letter regarding article, "Outcomes of patients with acute type A intramural hematoma." *Circulation* 2010; 121:e456.
20. Sundt TM. Intramural hematoma and penetrating atherosclerotic ulcer of the aorta. *Ann Thorac Surg* 2007; 83:S835–S841.
21. Juang D, Braverman A, Eagle K. Aortic dissection. *Circulation* 2008; 118:e507–e510.
22. Tsai TT, Evangelista A, Nienaber CA, et al. Long-term survival in patients presenting with type A acute aortic dissection. Insights from the international registry of acute aortic dissection. *Circulation* 2006; 114(suppl 1):I-350 – I-356.
23. Tsai TT, Fattori R, Trimarchi S, et al. Long-term survival in patients presenting with type B acute aortic dissection. Insights from the international registry of acute aortic dissection. *Circulation* 2006; 114:2226–2231.
24. Albornoz G, Coady MA, Roberts M, et al. Familial thoracic aortic aneurysms and dissections: incidence, modes of inheritance, and phenotypic patterns. *Ann Thorac Surg* 2006; 82:1400–1405.

ADDRESS: Alan C. Braverman, MD, Washington University School of Medicine, 660 South Euclid Avenue, Box 8086, St. Louis, MO 63117; e-mail [abraverm@dom.wustl.edu](mailto:abraverm@dom.wustl.edu).