

BACEL NSEIR, MD

Department of Infectious Diseases,
Ochsner Clinic Foundation,
New Orleans, LA

ANTHONY F. CUTRONA, MD

Chief, Division of Infectious Disease, Associate
Professor of Internal Medicine, Northeastern
Ohio Universities College of Medicine/West-
ern Reserve Care System, Youngstown, OH

Salmonella-related mycotic pseudoaneurysm

A 74-YEAR-OLD MAN is admitted to the hospital with a 7-day history of fever, rigors, chest pain, and general weakness. He underwent coronary artery bypass surgery 10 years ago.

High-resolution contrast-enhanced computed tomography of the chest shows an aneurysmal change near the mid-point of the descending aorta with a maximum diameter of 5 cm (FIGURE 1). Two sets of blood cultures done on admission identify *Salmonella enteritidis*, which was sensitive to ampicillin, sulfamethoxazole-trimethoprim (Bactrim), and ceftriaxone (Rocephin).

After 2 weeks of intravenous ceftriaxone 2 g/day, the patient undergoes excision of the mycotic pseudoaneurysm of the descending aorta, with placement of an aortic homograft. Biopsy of the excised aortic segment shows calcified fibroatheromatous plaques with no evidence of cystic medial degeneration or granulomas.

DISCUSSION

Mycotic aneurysm is a localized and irreversible dilatation of an artery due to destruction of the vessel wall by an infection. The dilatation is at least one and one-half times the normal diameter of the affected artery. It may be a true aneurysm or a pseudoaneurysm, involving all or some layers of the arterial wall. It is a rare but life-threatening condition.

A mycotic aneurysm can develop from septic embolization to the vasa vasorum, hematogenous seeding of an existing aneu-

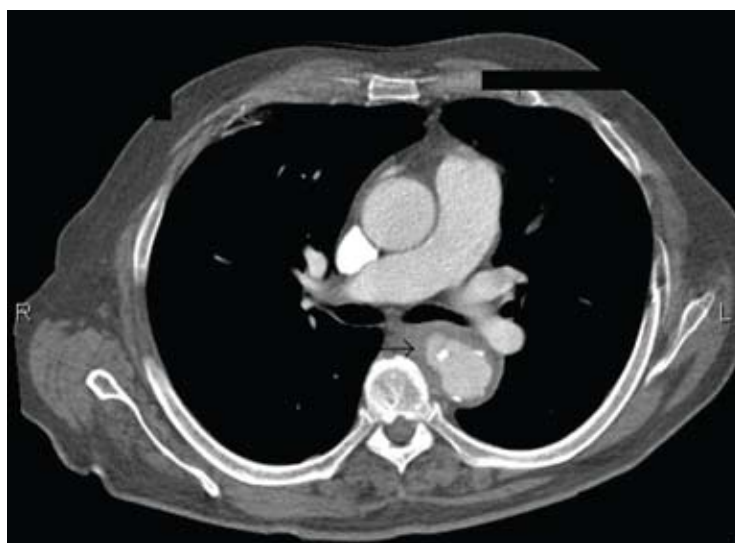


FIGURE 1.

rysm, or extension from a contiguous site of infection.^{1,2} Mycotic infections of the aorta show a preference for male patients already infected with *S enteritidis* or *S typhimurium*.³ Predisposing factors include rheumatic deformity of the valves, a bicuspid valve, impaired immunity,⁴ self-induced or iatrogenic arterial trauma,^{5,6} atherosclerotic deposits and calcification of the endovascular structure,⁷ and, in elderly patients, *Salmonella* septicemia.^{8,9} Computed tomography is the most useful imaging modality.^{10,11} Surgical interventions, in addition to parenteral antibiotic therapy for at least 6 weeks,^{11,12} are required to:

- Confirm the diagnosis
- Reconstruct the arterial vasculature
- Manage the complications of sepsis
- Start preventive measures (ie, cholecystectomy).²

doi:10.3949/ccjm.76a.08031

REFERENCES

1. Carreras M, Larena JA, Tabernero G, Langara E, Pena JM. Evolution of salmonella aortitis towards the formation of abdominal aneurysm. *Eur Radiol* 1997; 7:54–56.
2. Cicconi V, Mannino S, Caminiti G, et al. Salmonella aortic aneurysm: suggestions for diagnosis and therapy based on personal experience. *Angiology* 2004; 55:701–705.
3. Schneider S, Krulls-Munch J, Knorig J. A mycotic aneurysm of the ascending aorta and aortic arch induced by Salmonella enteritidis. *Z Kardiol* 2004; 93:964–967.
4. Johnson JR, Ledgerwood AM, Lucas CE. Mycotic aneurysm. New concepts in therapy. *Arch Surg* 1983; 118:577–582.
5. Qureshi T, Hawrych AB, Hopkins NF. Mycotic aneurysm after percutaneous transluminal femoral artery angioplasty. *J R Soc Med* 1999; 92:255–256.
6. Samore MH, Wessolossky MA, Lewis SM, Shubrooks SJ Jr, Karchmer AW. Frequency, risk factors, and outcome for bacteremia after percutaneous transluminal coronary angioplasty. *Am J Cardiol* 1997; 79:873–977.
7. Carnevalini M, Faccenna F, Gabrielli R, et al. Abdominal aortic mycotic aneurysm, psoas abscess, and aorto-bisiliac graft infection due to Salmonella typhimurium. *J Infect Chemother* 2005; 11:297–299.
8. Soravia-Dunand VA, Loo VG, Salit IE. Aortitis due to Salmonella: report of 10 cases and comprehensive review of the literature. *Clin Infect Dis* 1999; 29:862–868.
9. Malouf JF, Chandrasekaran K, Orszulak TA. Mycotic aneurysms of the thoracic aorta: a diagnostic challenge. *Am J Med* 2003; 115:489–496.
10. Gufler H, Buitrago-Tellez CH, Nesbitt E, Hauenstein KH. Mycotic aneurysm rupture of the descending aorta. *Eur Radiol* 1998; 8:295–297.
11. Lin CY, Hong GJ, Lee KC, Tsai CS. Successful treatment of Salmonella mycotic aneurysm of the descending thoracic aorta. *Eur J Cardiothorac Surg* 2003; 24:320–322.
12. Schoevaerdt D, Hanon F, Vanpee D, et al. Prolonged survival of an elderly woman with Salmonella dublin aortitis and conservative treatment. *J Am Geriatr Soc* 2003; 51:1326–1328.

.....
ADDRESS: Bacer Nseir, MD, Department of Infectious Diseases, Ochsner Clinic Foundation, 1514 Jefferson Highway, New Orleans, LA 70121; e-mail bnseird@hotmail.com.