



**EDUCATIONAL OBJECTIVE:** The reader will gain confidence in knowing when to order imaging in a patient with symptoms of rib fracture, and which imaging test to order

**SHARUKH J. BHAVNAGRI, MD**  
Imaging Institute, Cleveland Clinic

**TAN-LUCIEN H. MOHAMMED, MD**  
Department of Diagnostic Radiology, Imaging  
Institute, Cleveland Clinic

# When and how to image a suspected broken rib

## ABSTRACT

Radiographic confirmation of rib fracture is often clinically irrelevant in patients who appear to have no complications or associated injuries. However, it is essential in a number of cases, especially when the clinical presentation and history raise suspicion of complications such as organ damage, or if the patient has other risk factors or conditions for which the precise information would help in management decisions. The authors discuss when to order imaging and which imaging test to order.

## KEY POINTS

Knowing the number of ribs fractured may influence treatment decisions, such as whether to transfer a patient to a trauma center.

Classic clinical signs and symptoms of rib fracture include point tenderness, focally referred pain with general chest compression, splinting, bony crepitus, and ecchymosis.

In a patient with minor blunt trauma, when there is little suspicion of associated injury or complication, plain radiography is likely sufficient.

Computed tomography is the imaging study of choice in patients with penetrating or major chest or abdominal trauma.

A 70-YEAR-OLD MAN FALLS in his bathroom and subsequently presents to an urgent care clinic. Among his complaints is right-sided chest pain. On physical examination he has point tenderness over the lateral right thorax with some superficial swelling and bruising. The chest is normal on auscultation.

Should this patient undergo imaging to determine if he has a rib fracture? And which imaging study would be appropriate?

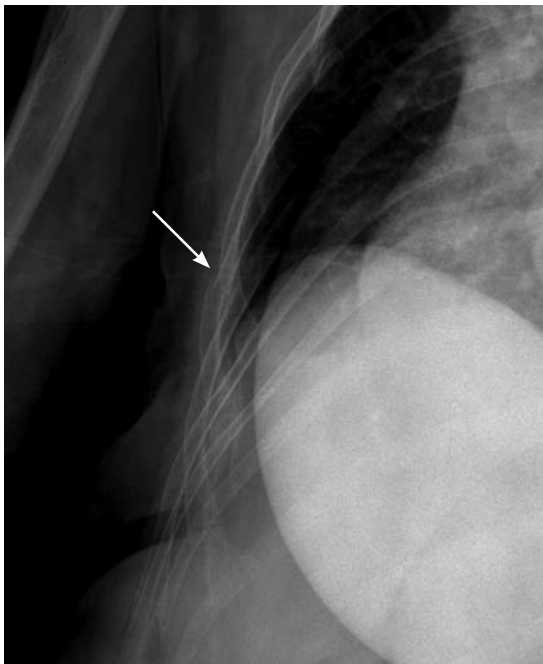
This article outlines the use of various imaging tests in the evaluation of suspected rib fractures and recommends an approach to management. This article does not address fractures in children.

## MANY CAUSES OF RIB FRACTURES

**Trauma**, the most common cause of rib fractures, includes penetrating injuries and blunt injury to the chest wall. Between 10% and 66% of traumatic injuries result in rib fractures.<sup>1</sup> Traumatic injury can result from motor vehicle accidents, assault, sports, cardiopulmonary resuscitation, physical abuse (“nonaccidental” trauma), and, rarely, severe paroxysms of coughing.<sup>2</sup>

**Cancer** can cause pathologic fractures of the rib.

**Stress fractures** of the ribs are more likely to occur in high-level athletes whose activity involves repetitive musculoskeletal loading, although they can also occur in people with repetitive coughing paroxysms.<sup>3</sup> Sports and activities that result in stress fractures include rowing, pitching or throwing, basketball, weight-lifting, ballet, golf, gymnastics, and swimming.<sup>4</sup>



**FIGURE 1.** Oblique radiographic view shows an acute rib fracture in a patient with multiple myeloma.

**The fourth through 10th ribs are the most often fractured**

#### ■ WHICH RIB IS BROKEN?

The fourth through 10th ribs are the most often fractured. Fractures of the first through the third ribs can be associated with underlying nerve and vascular injuries, and fractures of the 10th through 12th ribs are associated with damage to abdominal organs,<sup>5</sup> most commonly the liver, spleen, kidneys, and diaphragm.<sup>3</sup>

Fractures of the costal cartilage can occur by any of the mechanisms described above. The true incidence of costal cartilage fractures is not known because plain radiography, the traditional method of evaluation, does not reliably detect them.

#### ■ WHY CONFIRM A RIB FRACTURE?

For many rib fractures without associated injury, a radiographic diagnosis has little impact on patient management, which consists mainly of pain control. But knowing whether a patient has a broken rib can often be important.

**To detect associated injury.** The rate of associated injury in patients with rib fractures is high.<sup>6</sup> Potentially severe complications include:

- Pneumothorax
- Hemothorax
- Pulmonary contusion
- Flail chest
- Pneumonia
- Vascular and nerve damage (especially with trauma to the upper chest or the first through third ribs)
- Abdominal organ injury (particularly with trauma to the lower thorax or lower ribs).

The absence of a rib fracture does not preclude these conditions, however.

**To prevent complications.** Even in the absence of associated injuries, radiographic confirmation of a rib fracture can help prevent complications such as atelectasis and is particularly important in patients with comorbidities such as chronic obstructive pulmonary disease, cardiac disease, hepatic disease, renal disease, dementia, and coagulopathy.<sup>1</sup>

**To document the injury.** Radiographic documentation of a rib fracture may be required for medical-legal issues in cases of assault, motor vehicle accident, occupational injury, and abuse.

**To help manage pain.** Confirmation of rib fracture can facilitate pain management, particularly in patients with undiagnosed fractures with long-standing refractory pain. For example, conservative pain control with nonsteroidal anti-inflammatory drugs may be sufficient for a soft-tissue injury but may not be enough for a rib fracture. Intravenous narcotics or nerve blocks might be preferable.<sup>3,7</sup> Controlling pain helps limit the incidence of associated complications.

**To detect pathologic fractures.** Radiographic diagnosis can provide important information in cases of suspected pathologic fracture, as in multiple myeloma (FIGURE 1) or other malignancies.

**To count how many ribs are broken.** The more ribs broken, the greater the likelihood of illness and death in certain populations, such as the elderly. One study<sup>8</sup> found that patients over age 45 with more than four broken ribs are at a significantly higher risk of prolonged stay in the intensive care unit, prolonged ventilator support, and prolonged overall hospital stay.

Knowing the number of ribs fractured may also influence other treatment decisions, such

as whether to transfer the patient to a trauma center: a study showed that the more ribs broken, the greater the death rate, and that more than three rib fractures may indicate the need to transfer to a trauma center.<sup>6</sup>

## ■ HOW TO DIAGNOSE A BROKEN RIB

### Signs and symptoms are unreliable but important

Clinical symptoms do not reliably tell us if a rib is broken.<sup>9,10</sup> Nevertheless, the history and physical examination can uncover possible complications or associated injuries,<sup>10,11</sup> such as flail chest, pneumothorax, or vascular injury.

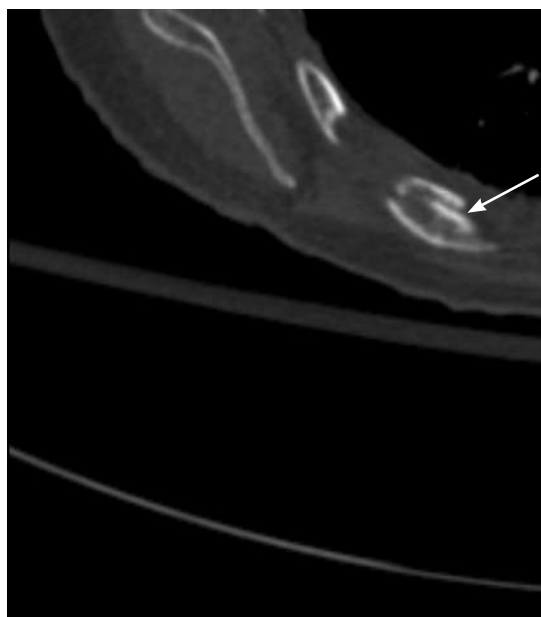
Classic clinical signs and symptoms of rib fracture include point tenderness, focally referred pain with general chest compression, splinting, bony crepitus, and ecchymosis.<sup>9</sup> A history of a motor vehicle accident (especially on a motorcycle) or other injury due to rapid deceleration, a fall from higher than 20 feet, a gunshot wound, assault, or a crushing injury would indicate a greater risk of complications.

Signs of complications may include decreased oxygen saturation, decreased or absent breath sounds, dullness or hyperresonance to percussion, tracheal deviation, hypotension, arrhythmia, subcutaneous emphysema, neck vein distension, neck hematoma, a focal neurologic deficit below the clavicles or in the upper extremities, and flail chest.<sup>11</sup> Flail chest results from multiple fractures in the same rib, so that a segment of chest wall does not contribute to breathing.

Further research is needed into the correlation of clinical symptoms with rib fractures. Much of the evidence that clinical symptoms correlate poorly with fractures comes from studies that used plain radiography to detect the fractures. However, ultrasonography and computed tomography (CT) can detect fractures that plain radiography cannot, and studies using these newer imaging tests may reveal a better correlation between clinical symptoms and rib fracture than previously thought.<sup>6</sup>

### Chest radiography may miss 50% of rib fractures, but is still useful

Plain radiography of the chest with or without oblique views and optimized by the technologist for bony detail (“bone technique”) has



**FIGURE 2.** Computed tomographic scan (zoomed axial image) shows an acute rib fracture.

historically been the imaging test of choice. However, it may miss up to 50% of fractures.<sup>10</sup> Furthermore, it is not sensitive for costal cartilage<sup>3</sup> or stress fractures.

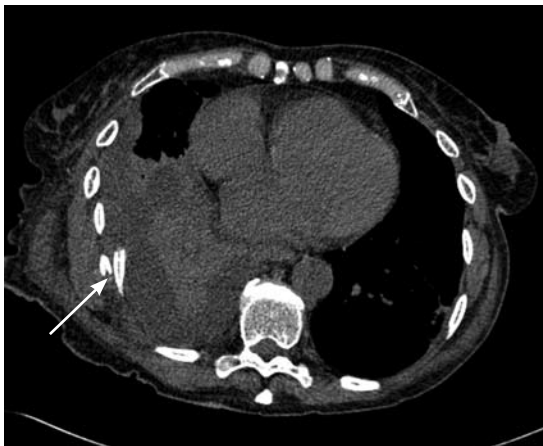Despite these limitations, plain radiography is vitally important in diagnosing complications and associated injuries such as a pneumothorax, hemothorax, pulmonary contusion, pneumomediastinum, or pneumoperitoneum. Also, a widened mediastinum could indicate aortic injury.

Currently, a standard chest x-ray is often the initial study of choice in the evaluation of chest pain and in cases of minor blunt trauma. If rib fractures are suspected clinically, a rib series can be of benefit. A rib series consists of a marker placed over the region of interest, oblique views, and optimization of the radiograph by the technologist to highlight bony detail. The decision to image a rib fracture in the absence of other underlying abnormalities or associated injuries depends on the clinical scenario.

### Computed tomography provides more detail

CT is the primary study to fully evaluate for trauma-associated injuries and to evaluate bony detail (**FIGURE 2**). Its diagnostic capabil-

**Chest x-ray is the initial study in the evaluation of chest pain and in cases of minor blunt trauma**



**FIGURE 3.** An axial image from a computed tomographic scan of the chest in a trauma patient shows a displaced fracture in a posterolateral right rib (arrow). There is an underlying effusion, the density of which indicates hemothorax. There is also a pulmonary contusion.

**Ultrasonography is useful if diagnosis of a rib fracture alone, in an accessible rib, is important**

ity is unsurpassed in this setting.<sup>11,12,13</sup> It is also useful for diagnosing costal cartilage injury, whereas radiography is not.<sup>14</sup> It can provide more details and new information when plain radiography indicates bone pathology: eg, a widened mediastinum suggesting vascular injury; pneumomediastinum or pneumoperitoneum of uncertain cause; cases of questionable pneumothorax; and locating foreign bodies or bony fragments, particularly in relation to vital vascular or nerve structures.

Additionally, CT may help elucidate non-specific findings such as lung opacification, which may represent hemothorax or pulmonary contusion or both (FIGURE 3). It can also better characterize pathologic fractures related to cancer. Specific bone reconstruction algorithms and three-dimensional reconstructions further improve CT's ability to detect rib pathology.

While CT appears to be the best imaging test for evaluating for rib fractures and associated injuries, it is relatively costly, is time-consuming, is not always available, and exposes the patient to a significant amount of radiation.

Also, while CT plays a vital role in major and penetrating trauma of the chest or abdomen, its use in other situations is more limited. Again, the issue of clinical impact of a diagnosis of rib fracture comes into play, and in this

setting CT competes with plain radiography and ultrasonography, which are less costly and involve less or no radiation exposure.

### **Ultrasonography has advantages but is not widely used**

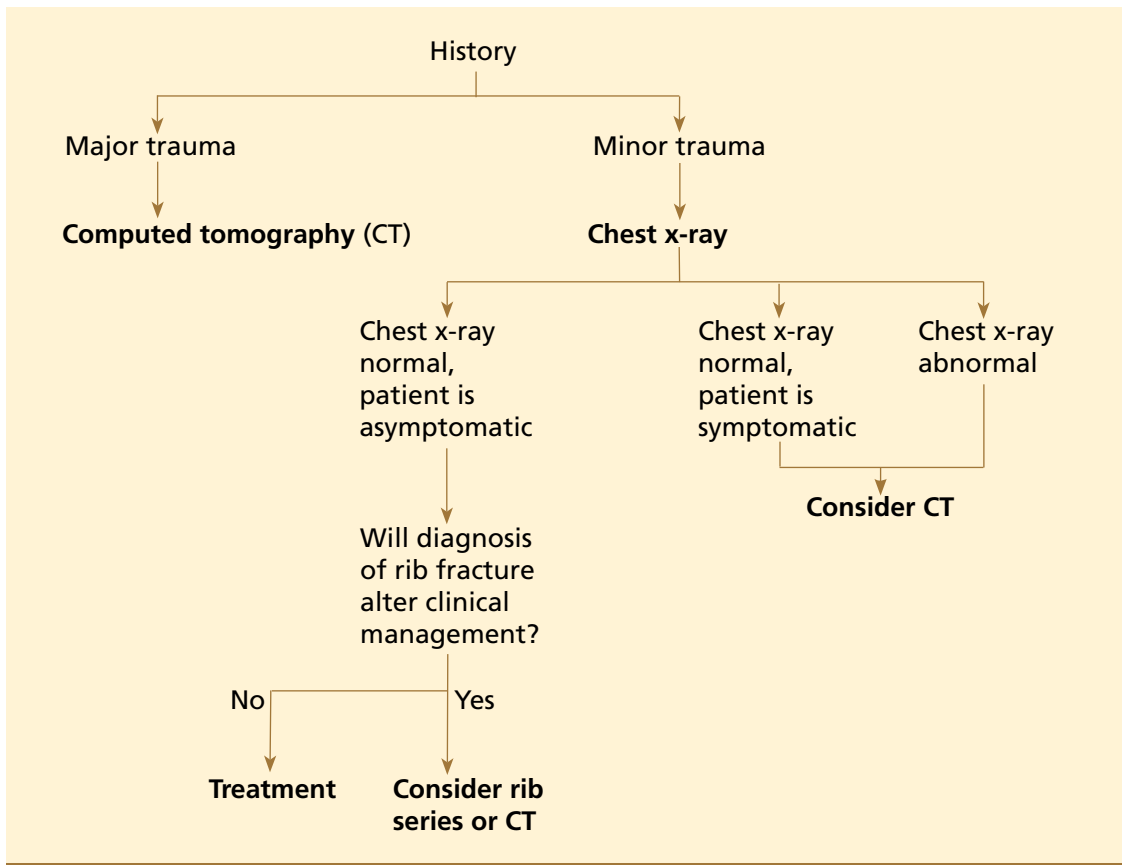
Ultrasonography can be used to look for broken ribs and costal cartilage fractures. Associated injuries such as pneumothorax, hemothorax, and abdominal organ injury can also be evaluated. Studies have found it to be much more sensitive than plain radiography in detecting rib fractures,<sup>3,15</sup> whereas other studies have suggested it is only equally sensitive or slightly better.<sup>7</sup> It also has the advantage of not using radiation.

Because of a number of disadvantages, ultrasonography is rarely used in the evaluation of rib fracture. It is time-consuming and more costly than plain radiography. It is often not readily available. It can be painful, making it impractical for trauma patients. Its results depend greatly on the skill of the technician, and it is unable to adequately assess certain portions of the thorax (eg, the first rib under the clavicle, and the upper ribs under the scapula).<sup>7,15</sup> Although able to detect some associated injuries, ultrasonography is not as sensitive and comprehensive as plain radiography and CT. Its role is therefore limited to situations in which the diagnosis of a rib fracture alone, in an accessible rib, is important.

### **Bone scan: Sensitive but not specific**

Technetium Tc 99m methylene diphosphate bone scanning can be used to look for bone pathology, including rib fractures. Bone scans are sensitive but not specific, and abnormal uptake generates an extensive differential diagnosis.<sup>16</sup> Single-photon emission CT, or SPECT, can help localize the abnormality.<sup>4</sup> Because a hot spot on a bone scan can represent a number of conditions besides rib fractures, including cancer, focal sclerosis, and focal osteosclerosis, bone scanning is not routinely used for evaluating rib fractures, although it is very sensitive for stress fractures.

Occasionally, in a patient undergoing a bone scan as part of a workup for cancer, a scan shows a lesion that might be a rib fracture. In



**FIGURE 4.** Recommended clinical management of patients with a history of chest trauma. In an asymptomatic patient, the key question is whether confirming a rib fracture with radiographic imaging will alter clinical management. In a symptomatic patient with a normal chest x-ray, one may consider CT to detect underlying injury as well as rib fractures.

**Key question:**  
In an asymptomatic patient, will confirming a rib fracture alter clinical management?

this case, one should correlate the results with those of plain radiography or CT.<sup>16</sup>

### Magnetic resonance imaging: no role yet in rib fracture evaluation

MRI is not considered appropriate for evaluating rib fractures. It may be useful if there is concern about soft-tissue or vascular abnormalities. Beyond this, further research is needed to elucidate its role in rib fracture.

### THE CHOICE OF TEST DEPENDS ON THE SITUATION

Although several imaging tests can tell us if a patient has a rib fracture, in most cases the diagnosis of a rib fracture alone has little clinical relevance. The accurate and timely assessment of associated injuries and complications is more clinically useful, and for this, plain ra-

diography and CT provide the most useful information. The choice of which test to use in a patient with a suspected rib fracture depends on the clinical circumstances (FIGURE 4).

In patients with penetrating or major chest or abdominal trauma, CT is the study of choice. It provides the most information about associated injuries, and it accurately detects rib fractures. This helps target treatment of associated injuries, and helps identify patients at higher risk, such as those with significant vascular, pulmonary, or abdominal injuries and those with a greater number of fractures. An unstable, critically injured patient would not be a candidate for CT because of the risk of transport to the scanner; chest radiography would have to suffice in these cases.

In cases of minor blunt trauma when there is little suspicion of associated inju-



ries or complications, plain radiography is likely sufficient. If there is suspicion of a rib fracture alone and confirmation is of clinical importance (eg, in the elderly or those with long-standing refractory pain, or when certain pain management treatments are being considered), then oblique radiographic views, bone technique, and marker placement over the concerning region are recommended. The role of ultrasonography in this setting is still up for debate.

In cases of suspected rib fracture with long-standing pain refractory to conservative pain management, plain radiography with oblique views, bone technique, and marker placement is useful. If the radiograph is negative or if there is a high suspicion of cartilage fracture, CT or ultrasonography may be of benefit only if the diagnosis will alter clinical management.

If stress fracture is suspected, a nuclear bone scan may be helpful to first detect an abnormality, and CT may then be used for correlation if needed.

#### ■ CASE CONCLUDED: LIVING WITH UNCERTAINTY

As for the 70-year-old man presented at the beginning of this article, the first question is

whether we suspect an associated injury on the basis of clinical features. If we had clinical findings suspicious for pneumothorax or hemothorax, plain radiography of the chest would be indicated. Since the patient was not involved in major trauma, a CT scan is not indicated as the first study.

Our patient has clinical findings suggesting a rib fracture without associated injury. In this setting, routine posteroanterior and lateral chest radiography would be useful to rule out major associated injuries and, perhaps, to find a rib fracture. If the chest film is normal and rib fracture is still suspected, we must decide whether the diagnosis would alter our clinical management. Our patient would likely be treated the same regardless of whether or not he has a fracture; therefore, we would prescribe pain management.

Chest radiography was performed to rule out associated injuries, especially since the patient was elderly, but the chest x-ray did not reveal anything. On follow-up approximately 1 month later, he appeared improved, with less pain and tenderness. This may be due to healing of a rib fracture or healing of his soft-tissue injury. We will never know whether he truly had a fracture, but it is irrelevant to his care. ■

Whether he truly had a rib fracture is irrelevant to his care

#### ■ REFERENCES

- Bergeron E, Lavoie A, Clas D, et al. Elderly trauma patients with rib fractures are at greater risk of death and pneumonia. *J Trauma* 2003; 54:478–485.
- Lederer W, Mair D, Rabl W, Baubin M. Frequency of rib and sternum fractures associated with out-of-hospital cardiopulmonary resuscitation is underestimated by conventional chest x-ray. *Resuscitation* 2004; 60:157–162.
- Kara M, Dikmen E, Erdal HH, Simsir I, Kara SA. Disclosure of unnoticed rib fractures with the use of ultrasonography in minor blunt chest trauma. *Eur J Cardiothorac Surg* 2003; 24:608–613.
- Connolly LP, Connolly SA. Rib stress fractures. *Clin Nucl Med* 2004; 29:614–616.
- Bansidhar BJ, Lagares-Garcia JA, Miller SL. Clinical rib fractures: are follow-up chest x-rays a waste of resources? *Am Surg* 2002; 68:449–453.
- Stawicki SP, Grossman MD, Hoey BA, Miller DL, Reed JF 3rd. Rib fractures in the elderly: a marker of injury severity. *J Am Geriatr Soc* 2004; 52:805–808.
- Hurley ME, Keye GD, Hamilton S. Is ultrasound really helpful in the detection of rib fractures? *Injury* 2004; 35:562–566.
- Holcomb JB, McMullin NR, Kozar RA, Lygas MH, Moore FA. Morbidity from rib fractures increases after age 45. *J Am Coll Surg* 2003; 196:549–555.
- Deluca SA, Rhea JT, O'Malley TO. Radiographic evaluation of rib fractures. *AJR Am J Roentgenol* 1982; 138:91–92.
- Dubinsky I, Low A. Non-life threatening blunt chest trauma: appropriate investigation and treatment. *Am J Emerg Med* 1997; 15:240–243.
- Sears BW, Luchette FA, Esposito TJ, et al. Old fashion clinical judgment in the era of protocols: is mandatory chest x-ray necessary in injured patients? *J Trauma* 2005; 59:324–332.
- Traub M, Stevenson M, McEvoy S, et al. The use of chest computed tomography versus chest x-ray in patients with major blunt trauma. *Injury* 2007; 38:43–47.
- Trupka A, Waydhas C, Hallfeldt KK, Nast-Kolb D, Pfeifer KJ, Schweiberer L. Value of thoracic computed tomography in the first assessment of severely injured patients with blunt chest trauma: results of a prospective study. *J Trauma* 1997; 43:405–412.
- Malghem J, Vande Berg B, Lecouvet F, Maldague B. Costal cartilage fractures as revealed on CT and sonography. *AJR Am J Roentgenol* 2001; 176:429–432.
- Griffith JF, Rainer TH, Ching AS, Law KL, Cocks RA, Metreweli C. Sonography compared with radiography in revealing acute rib fracture. *AJR Am J Roentgenol* 1999; 173:1603–1609.
- Niitsu M, Takeda T. Solitary hot spots in the ribs on bone scan: value of thin-section reformatted computed tomography to exclude radiography negative fractures. *J Comput Assist Tomogr* 2003; 27:469–474.

ADDRESS: Tan-Lucien H. Mohammed, MD, Department of Diagnostic Radiology, Hb6, Cleveland Clinic, 9500 Euclid Avenue, Cleveland, OH 44195; e-mail mohammm@ccf.org.