

**MELISSA P. PILIANG, MD**

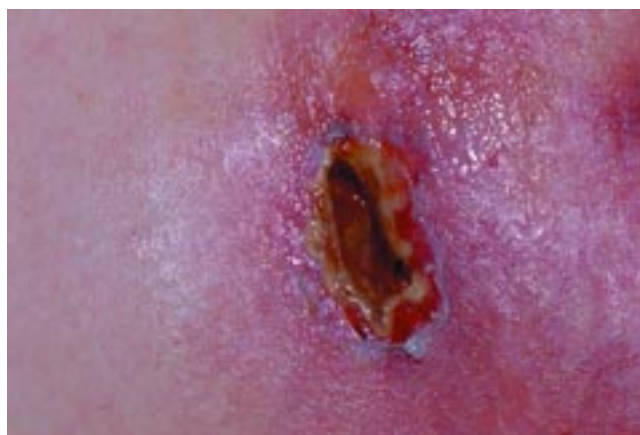Department of Dermatology and  
Department of Anatomic Pathology,  
Cleveland Clinic

**JAMES K. STOLLER, MD, MS\***

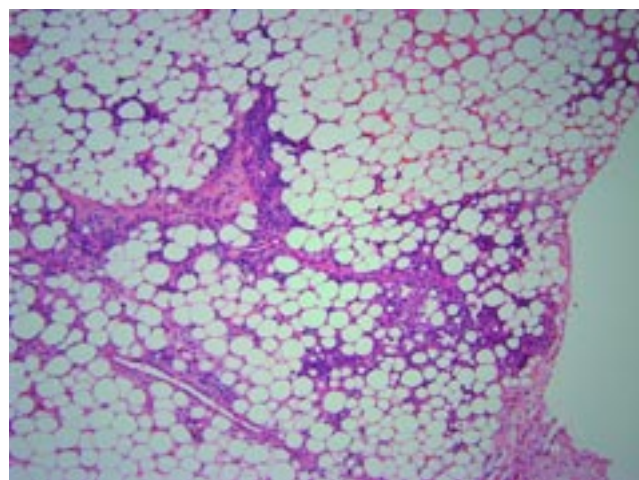
Executive Director, Leadership Development,  
Head, Section of Respiratory Therapy, Respiratory  
Institute, Cleveland Clinic; Jean Wall Bennett  
Professor of Medicine, Cleveland Clinic Lerner  
College of Medicine of Case Western Reserve  
University

# The Clinical Picture

## A woman with ulcerating, painful skin lesions



**FIGURE 1.** A necrotic, weeping ulcer from the upper extremity, measuring approximately 2 cm.



**FIGURE 2.** Skin biopsy shows lobular panniculitis with neutrophils (small bluish dots) and adipocyte necrosis. Hematoxylin-eosin stain,  $\times 400$ .

**A** 47-YEAR-OLD WOMAN developed painful, weeping skin nodules on her upper arm (**FIGURE 1**). She had previously enjoyed good health and said she had no family history of such lesions. She had no personal or family history of liver, pancreatic, renal, or lung disease.

She was taking no medications, and her physical examination revealed nothing remarkable other than her skin nodules. A biopsy was performed on one of the lesions; its histologic features (**FIGURE 2**) support the diagnosis of a neutrophilic, primarily lobular panniculitis.

\*Dr. Stoller has disclosed that he has received honoraria from Baxter Healthcare, Talecris Biotherapeutics, Grifols, and CSL Behring for speaking and teaching and from Talecris Biotherapeutics for consulting.

**Q:** On the basis of the skin findings, which test should be ordered to establish a diagnosis?

- ☐ Serum anti-nuclear antibody (ANA)
- ☐ Alpha-1 antitrypsin serum level
- ☐ Angiotensin-converting enzyme (ACE)
- ☐ Serum amylase

**A:** The lesions of a lobular, neutrophilic panniculitis should raise the possibility of alpha-1 antitrypsin deficiency. Hence, measuring the alpha-1 antitrypsin serum level is the best answer.

Many other conditions can give rise to panniculitis, including pancreatitis, lupus, and sarcoidosis, each of which is suggested by the various other test choices above. However, although the ANA level might be elevated in lupus, the ANA is quite nonspecific. The

## Panniculitis due to alpha-1 antitrypsin deficiency

### SUMMARY

Panniculitis is an uncommon complication of alpha-1 antitrypsin deficiency, which is an under-recognized condition. Collective experience to date permits enhanced understanding of the clinical manifestations and treatment of alpha-1 antitrypsin deficiency-associated panniculitis. Further study is needed to determine its precise pathophysiology and optimal treatment.

### KEY POINTS

- Panniculitis due to alpha-1 antitrypsin deficiency produces recurrent, tender erythematous nodules that ulcerate and produce an oily discharge.
- Serum alpha-1 antitrypsin levels should be included in the laboratory workup of panniculitis.
- Deep, incisional biopsy including subcutaneous fat is needed to make the histologic diagnosis.
- Treatment with intravenous pooled human plasma alpha-1 proteinase can produce rapid improvement.

### Panniculitis may be the only clinical manifestation of alpha-1 antitrypsin deficiency

serum ACE level is frequently ordered as a screening test for sarcoidosis, although it has very little utility in its diagnosis. Panniculitis due to pancreatitis with an elevated serum amylase level would be relatively unlikely in the absence of pancreatic symptoms (eg, abdominal pain).

Panniculitis may be the only clinical manifestation of alpha-1 antitrypsin deficiency, which can also be accompanied (depending on the phenotype) by chronic obstructive pulmonary disease and cirrhosis. Since alpha-1 antitrypsin deficiency is underrecognized in general, suspecting it when patients present with panniculitis will likely enhance its detection. Similarly, national guidelines recommend testing for alpha-1 antitrypsin deficiency in patients with either symptomatic, fixed airflow obstruction or cirrhosis that is otherwise unexplained, as well as in patients with panniculitis.<sup>1</sup>

### ■ PANNICULITIS DUE TO ALPHA-1 ANTITRYPSIN DEFICIENCY

Alpha-1 antitrypsin deficiency is clearly, though uncommonly, associated with panni-

culitis, which is inflammation of the subcutis. Clinical manifestations of panniculitis associated with this condition include red, painful nodules that may ulcerate and drain an oily discharge. The most common sites of involvement include the thighs, buttocks, and areas of physical trauma. The pathophysiology of panniculitis in alpha-1 antitrypsin deficiency presumably involves unopposed elastase activity.

### Likely due to proteolytic damage

Though incompletely understood, the panniculitis in alpha-1 antitrypsin deficiency is likely the result of unopposed proteolytic damage in the subcutaneous fat by membrane-bound serine proteases, akin to the pathogenesis of pulmonary emphysema in people with severe deficiency of alpha-1 antitrypsin. Supporting evidence for the inflammatory, proteolytic pathogenesis of panniculitis in alpha-1 antitrypsin deficiency includes the presence of inflammatory exudates in the subcutaneous tissues, as well as the rapid improvement seen with the infusion of purified pooled human alpha-1 proteinase inhibitor.<sup>2-4</sup>

### Red, painful nodules

Panniculitis due to alpha-1 antitrypsin deficiency classically presents as red, painful nodules that may break down and ooze an oily discharge.<sup>5-10</sup> As in the patient presented here, common sites of occurrence are areas of trauma, eg, on the thighs and buttocks, abdomen, and upper extremities (FIGURE 1). Indeed, in a review of the 41 reported cases of panniculitis related to alpha-1 antitrypsin deficiency, Geraminejad et al<sup>11</sup> reported that the erythematous plaques and nodules occurred on the thighs, hips, buttocks, or groin in 44% of cases in which the location was cited. Factors predisposing to panniculitis include trauma (cited in 35% of instances), cryosurgery, and, in the case of alpha-1 antitrypsin deficiency, extravasation of intravenous clarithromycin (Biaxin).<sup>11-13</sup>

Clinical features that distinguish the panniculitis associated with alpha-1 antitrypsin deficiency from other types of panniculitis include ulceration and an oily discharge, both of which were present in the patient discussed here.

### Neutrophils, necrosis, scarring, fibrosis

Several distinctive phases and features characterize the histology of panniculitis associated with alpha-1 antitrypsin deficiency.<sup>5,7</sup> Initially, neutrophils briskly infiltrate the reticular dermis, splaying the collagen bundles. In the subcutaneous fat, the neutrophilic infiltrate is in a lobular pattern, affecting individual adipocytes. Rarely, a septal pattern or a mixed lobular and septal pattern can be seen. This phase is followed by dissolution of the dermal collagen, with liquefactive necrosis of the subcutaneous fat (clinically appearing as ulceration and leading to oily drainage). In the late stage, there is scarring and fibrosis with little or no inflammation.

### Various treatments tried

Various therapies for panniculitis associated with alpha-1 antitrypsin deficiency have been tried, including corticosteroids, doxycycline (Vibramycin), dapsone, plasma exchange, liver transplantation, and intravenous pooled human plasma alpha-1 proteinase inhibitor (so-called augmentation therapy). Because panniculitis associated with alpha-1 antitrypsin deficiency is rare, neither controlled, blinded studies nor even large observational series have been reported. However, the limited reported experience with augmentation therapy suggests that it can confer rapid and dramatic improvement in panniculitis in patients with alpha-1 antitrypsin deficiency. ■

### REFERENCES

1. American Thoracic Society, European Respiratory Society. American Thoracic Society/European Respiratory Society statement: standards for the diagnosis and management of individuals with alpha-1 anti-trypsin deficiency. *Am J Respir Crit Care Med* 2003; 168:818–900.
2. Smith KC, Pittelkow MR, Su WP. Panniculitis associated with severe alpha-1 antitrypsin deficiency. Treatment and review of the literature. *Arch Dermatol* 1987; 123:1655–1661.
3. Furey NL, Golden RS, Potts SR. Treatment of alpha-1 antitrypsin deficiency, massive edema, and panniculitis with alpha-1 protease inhibitor [letter]. *Ann Intern Med* 1996; 125:699.
4. O'Riordan K, Blei A, Rao MS, Abecassis M. Alpha-1 antitrypsin deficiency-associated panniculitis: resolution with intravenous alpha-1 antitrypsin administration and liver transplantation. *Transplantation* 1997; 63:480–482.
5. Stoller JK, Piliang M. Panniculitis in alpha-1 antitrypsin deficiency: a review. *Clin Pulm Med* 2008; 15:113–117.
6. Hendrick SJ, Silverman AK, Solomon AR, Headington JT. Alpha-1 antitrypsin deficiency associated with panniculitis. *J Am Acad Derm* 1988; 18:684–692.
7. Loche F, Trembeau-Martinage C, Laplanche G, Massip P, Bazex J. Panniculitis revealing qualitative alpha-1 antitrypsin deficiency (MS variant). *Eur J Dermatol* 1999; 9:565–567.
8. McBean J, Sable A, Maude J, Robinson-Bostom L. Alpha 1-anti-trypsin deficiency panniculitis. *Cutis* 2003; 71:205–209.
9. Pittelkow MR, Smith KC, Su WP. Alpha-1 antitrypsin deficiency and panniculitis. Perspectives on disease relationship and replacement therapy. *Am J Med* 1988; 84:80–86.
10. Requena L, Sánchez Yus E. Panniculitis. Part II. Mostly lobular panniculitis. *J Am Acad Dermatol* 2001; 45:325–361.
11. Geraminejad P, DeBloom JR 2nd, Walling HW, Sontheimer RD, VanBeek M. Alpha-1-antitrypsin associated panniculitis: the MS variant. *J Am Acad Dermatol* 2004; 51:645–655.
12. Linares-Barrios M, Conejo-Mir IS, Artola Igarza JL, Navarrete M. Panniculitis due to alpha-1 antitrypsin deficiency induced by cryosurgery [letter]. *Br J Dermatol* 1998; 138:552–553.
13. Parr DG, Stewart DG, Hero I, Stockley RA. Panniculitis secondary to extravasation of clarithromycin in a patient with alpha 1-antitrypsin deficiency (phenotype PiZ). *Br J Dermatol* 2003; 149:410–413.

ADDRESS: Melissa P. Piliang, MD, Department of Dermatology, A61, Cleveland Clinic, 9500 Euclid Avenue, Cleveland, OH 44195; e-mail [pilianm@ccf.org](mailto:pilianm@ccf.org).