

**ANAT GALOR, MD**Bascom Palmer Eye Institute,
University of Miami, Miami, FL**BENNIE H. JENG, MD***Cole Eye Institute, Cleveland Clinic; Assistant
Professor of Ophthalmology, Cleveland Clinic
Lerner College of Medicine of Case Western
Reserve University, Cleveland, OH

Red eye for the internist: When to treat, when to refer

■ ABSTRACT

When a patient presents with redness in the eye, the cause needs to be diagnosed quickly. Some of the diseases that cause redness in the eye can be initially managed by an internist, but others call for quick referral to an ophthalmologist. This article reviews the spectrum of conditions manifesting as a red eye, emphasizing how to differentiate between the benign and the vision-threatening.

■ KEY POINTS

Blepharitis, conjunctivitis, corneal abrasion, dry eye, and subconjunctival hemorrhage are benign and can usually be managed initially by an internist, although referral is usually indicated if symptoms persist or progress.

Patients with corneal bacterial infection, uveitis, scleritis, or acute narrow-angle glaucoma need immediate referral to an ophthalmologist, as do most patients with a red eye who use contact lenses, who have had trauma to the eye, or who have vision changes, severe pain, nausea, vomiting, severe headache, marked purulent discharge, or abnormalities in the cornea or anterior segment.

Because it is difficult to distinguish between infectious and noninfectious conditions, and because treating infections with corticosteroids alone can have grave consequences, we recommend that internists generally not use topical corticosteroids to treat eye symptoms.

*Dr. Jeng has disclosed that he has received honoraria from Alcon for teaching and speaking.

MANY PATIENTS present to internists because of redness in the eye. The possible causes range from benign (which generally can be handled by an internist) to vision-threatening (which need prompt or emergency referral to an ophthalmologist).

This article, a primer on red eye for the internist, reviews the conditions that can cause this ocular sign—the ones that internists can comfortably manage and the ones that are best managed by an eye specialist (TABLE 1).

■ HISTORY HELPS IDENTIFY THE CAUSE

The internist should ascertain:

- Whether one or both eyes are affected
- The duration of symptoms
- Previous eye and medical problems
- The type of discharge (watery or purulent), if present
- Whether the patient has any visual changes, pain, or photosensitivity.

Refer patients to an ophthalmologist for further evaluation if they use contact lenses or if they have had trauma to the eye, vision changes, severe pain, or systemic symptoms such as nausea, vomiting, or severe headache.

■ BASIC EYE EXAMINATION

Examine:

- Visual acuity
- Pupil size and reaction to light
- The pattern and location of the redness
- The cornea and anterior segment for gross abnormalities such as corneal opacities, hypopyon (a layer of inflammatory cells in the anterior chamber), and hyphema

TABLE 1

Causes of red eye and their typical presenting symptoms

CAUSE	PRESENTING SYMPTOMS	SIDE TYPICALLY AFFECTED
CONDITIONS A GENERALIST CAN INITIALLY MANAGE		
Subconjunctival hemorrhage	None	Unilateral
Blepharitis	Burning, foreign body sensation, watering, crusting of lashes; worse in morning	Bilateral
Keratoconjunctivitis sicca	Foreign body sensation, burning, watering; worse at end of day	Bilateral
Eyelid malposition	Burning, foreign body sensation, watering	Unilateral or bilateral
Conjunctivitis		
Viral	Excessive watery discharge, irritation, pruritus	Unilateral or bilateral
Bacterial	Thick purulent discharge, irritation, pruritus	Unilateral or bilateral
Allergic	White mucoid discharge, pruritus	Bilateral
Corneal abrasion	Pain, photophobia, watering, blurred vision	Unilateral
Pinguecula, pterygium	Irritation, foreign body sensation	Unilateral or bilateral
Episcleritis	None	Often unilateral
Thyroid-related eye disease	Burning, watering, foreign body sensation, double vision,* decreased vision*	Unilateral or bilateral
CONDITIONS NEEDING REFERRAL WITHIN 48 HOURS		
Scleritis	Deep pain, can awaken patient	Unilateral
Acute anterior uveitis	Pain, photophobia	Unilateral
Canaliculitis	Pain, swelling, discharge from punctum	Unilateral
Dacryocystitis	Pain, swelling, redness over lacrimal sac	Unilateral
CONDITIONS NEEDING IMMEDIATE REFERRAL		
Acute angle-closure glaucoma	Pain, watering, halos around lights, headache, nausea, vomiting	Unilateral
Foreign body in eye	Pain, irritation, watering	Unilateral
Keratitis (herpetic, bacterial)	Pain, photophobia, watering, blurred vision	Unilateral

*If these symptoms are present, immediate referral is warranted

(hemorrhage in the anterior chamber) (Use a penlight.)

- The preauricular lymph nodes. Preauricular lymphadenopathy, detected by palpation, suggests but is not specific for viral conjunctivitis.
- Funduscopy has little value in evaluating a red eye.

Refer immediately anyone who has marked purulent discharge or abnormalities in the cornea or anterior segment.

■ CONDITIONS A GENERALIST CAN INITIALLY MANAGE

Subconjunctival hemorrhage

Broken conjunctival blood vessels can bleed into the subconjunctival space (FIGURE 1). These hemorrhages can occur spontaneously or be due to trauma, the Valsalva maneuver, antiplatelet agents, antithrombotics, or vita-

min E in high doses.

Subconjunctival hemorrhages are harmless and do not cause pain or vision changes. No treatment is required, and the blood resorbs within a few weeks. However:

- Measure the blood pressure—uncontrolled hypertension can present with subconjunctival hemorrhage.¹
- If the patient is on an antithrombotic agent, test the prothrombin and activated partial thromboplastin times.
- If the patient has recurrent unexplained episodes of subconjunctival hemorrhage, look for a bleeding disorder such as von Willebrand disease, hemophilia, or autoimmune thrombocytopenic purpura.

Blepharitis

Blepharitis, a common condition, is inflammation of the eyelid margins. Anterior blepharitis affects the eyelashes and anterior eye-

lid margin and is most often caused by a low-grade staphylococcal infection or seborrheic dermatitis. Posterior blepharitis involves the orifices of the slender sebaceous glands of the eyelids (the meibomian glands) and is often associated with acne rosacea.

Symptoms include ocular burning, a sensation that a foreign body is in the eye, and watering. Symptoms are typically worse in the morning and gradually improve throughout the day. Although the onset is sudden in some patients, blepharitis is usually chronic—often lifelong—and starts insidiously.

A sign of anterior blepharitis is crusting around the eyelashes. Patients with concomitant seborrheic dermatitis also have oily skin and flaking from the eyebrows and scalp. Signs of posterior blepharitis are oil inspissation around the meibomian gland openings, telangiectasias of the eyelid margin, and accompanying acne rosacea (skin pustules, telangiectasias, and erythema).

Treat both forms with eyelid hygiene: applying warm compresses to the eyelid margins, followed by gentle massage to remove the debris from the eyelashes and meibomian glands. This is done two to four times daily until acute symptoms resolve, then once daily. Because blepharitis is chronic, eyelid hygiene must be continued indefinitely to prevent acute exacerbations.

Posterior blepharitis that does not respond to hygiene can be also treated with oral tetracycline, which is believed to improve meibomian gland function and alter bacterial colonization.

Some patients also have tear deficiency, which can be addressed with tear replacement therapy (see below).^{2,3}

Keratoconjunctivitis sicca (dry eye)

Dryness can cause mild eye redness. Patients typically report a foreign body sensation, burning, and paradoxically, watering. Symptoms often worsen as the day progresses and are most prominent at night.

Dryness can be due to:

- Local disturbances in the tear film such as aqueous deficiency
- An abnormal eyelid position
- Systemic autoimmune conditions such as Sjögren syndrome
- Hormonal changes (eg, in menopause)

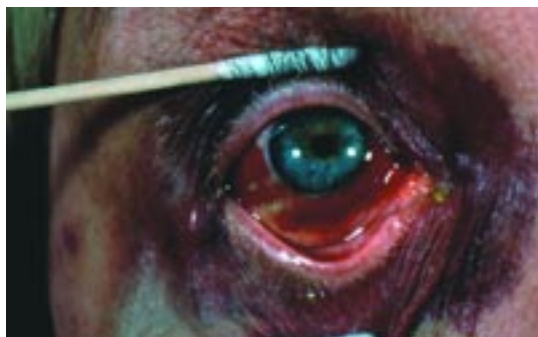

FIGURE 1. Subconjunctival hemorrhage after blunt trauma to the periocular area.

- Excessively dry environments (eg, winter)
- Medications, including anticholinergics, antihistamines, antidepressants (eg, tricyclics), and antihypertensives (eg, beta-blockers).

Staining the cornea with fluorescein highlights small epithelial defects; rose bengal highlights devitalized cells.

Treat initially with artificial tears (eg, Refresh Tears, GenTeal, Systane, Bion Tears) and ointments (eg, Refresh Liquigel, Lacri-Lube). Dry eye has an inflammatory component; cyclosporine ophthalmic 0.05% (Restasis) may increase tear production and improve symptoms.⁴

Refer patients with symptoms that do not respond to therapy. An ophthalmologist can place silicone plugs in the canaliculi, a procedure with a 75% success rate for improving dry-eye symptoms.⁵ Plugs must be carefully fitted: loose ones can spontaneously dislodge, and tight ones can irritate the eye.

Eyelid malposition

Entropion (in-turning of the eyelid) causes eyelashes to rub on the cornea. **Ectropion** (outward turning of the eyelid) results in tear-film abnormalities and corneal exposure. Both conditions are most commonly caused by aging but may be secondary to scarring or to mechanical, paralytic, or congenital conditions. Definitive treatment involves surgery to restore the normal eyelid position. Several techniques have high success rates.¹

Lagophthalmos (inability to fully close the eyes) is caused by orbicularis muscle dysfunction, which may be secondary to Bell palsy, stroke, or neurosurgical procedures that disrupt the facial nerve. The exposed cornea is

Paradoxically, patients with dry eye typically report watering

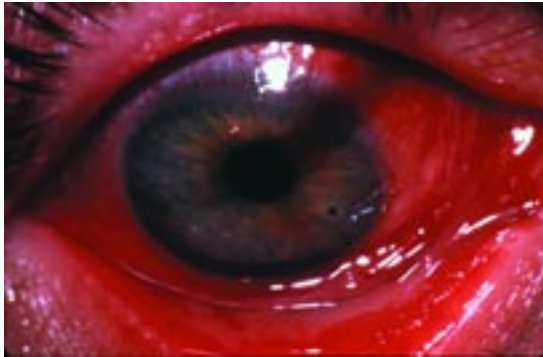

FIGURE 2. Viral conjunctivitis with an intensely red eye and a white fibrin membrane in the inferior fornix.

prone to dryness and irritation. Treatments include artificial tears, lubricating ointments, and surgery—gold weight placement or suturing the eyelid margins (tarsorrhaphy).

Floppy eyelid syndrome refers to a lax upper eyelid that may evert during contact with the pillow during sleep, resulting in irritation and inflammation of the upper palpebral conjunctiva. Signs and symptoms are unilateral eye irritation, burning, and a ropy mucous discharge, which is usually worse in the morning. The upper eyelid is lax and easily everted when pulled toward the eyebrow. Most patients are obese, have obstructive sleep apnea, and sleep on the affected side.

Tell the patient to tape the affected eyelid shut or wear a protective eye shield in bed to prevent rubbing the eye on the pillow. Definitive treatment is surgery to tighten the lax upper eyelid.⁶

Conjunctivitis

Conjunctivitis involves hyperemia and edema of the bulbar conjunctiva (the part of the conjunctiva covering the eyeball) along with papillary and follicular changes of the palpebral conjunctiva (the inner layer of the eyelids).

Conjunctivitis can be viral, bacterial, or allergic, or due to wearing contact lenses; the cause can usually be distinguished by the history and physical examination.

Viral conjunctivitis, usually caused by an adenovirus, is more common than bacterial conjunctivitis in adults. The patient typically has had a recent upper respiratory tract infection or was exposed to conjunctivitis.

The onset is acute with redness in one eye

and excessive watery discharge (**FIGURE 2**). The other eye becomes involved within days in about half of cases. Symptoms can include itching, photophobia, watering, and foreign body sensation. Patients often report “matting” and “crusting” of the eyelids in the mornings. Examination reveals follicular conjunctivitis on the lower palpebral conjunctiva and often preauricular lymphadenopathy.

Treat supportively with cool compresses. Symptoms often worsen for a few days, then slowly improve over 1 to 2 weeks.

Viral conjunctivitis is contagious for 2 weeks after the second eye becomes involved, and good hygiene must be maintained to avoid spreading it to coworkers and family members. Those who work with the public, in schools, or in health-care facilities should be given a 2-week leave of absence to avoid spreading the infection to others.

Refer to an ophthalmologist if symptoms do not resolve in 2 weeks, as certain subtypes of adenovirus can cause prolonged symptoms with corneal involvement.⁷

Bacterial conjunctivitis can be caused by gram-positive or gram-negative organisms and is differentiated from viral conjunctivitis by thick, purulent discharge rather than excessive watering (**FIGURE 3**). Examination reveals papillary conjunctivitis and sometimes preauricular lymphadenopathy.

Treat bacterial conjunctivitis empirically with antibiotic eyedrops (eg, a fluoroquinolone, a polymyxin, or sulfacetamide—several brands available) four times daily for 7 to 10 days, even though most cases are self-limited and do not result in complications. Cultures can be obtained, especially if the patient is in the hospital⁸ or if the conjunctivitis persists after 1 week of antibiotic therapy.

Refer patients with vision changes or who do not improve after 1 week of treatment.^{9,10}

Hyperacute bacterial conjunctivitis should be suspected if the onset is abrupt with copious purulent discharge. Most often associated with *Neisseria gonorrhoeae* infection, it can lead to corneal involvement, including perforation and visual loss (**FIGURE 4**).

Treat aggressively with both a topical antibiotic (usually a fluoroquinolone) four times daily and a systemic antibiotic such as ceftriaxone (Rocephin) given as a single 1-g

Bacterial conjunctivitis has thick, purulent discharge; viral has excessive watering

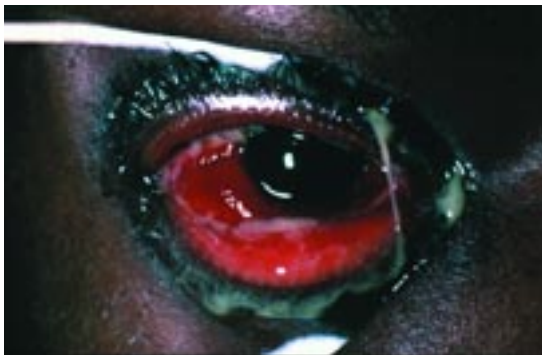

FIGURE 3. Bacterial conjunctivitis. Note pus in inferior fornix and along eyelid margins.

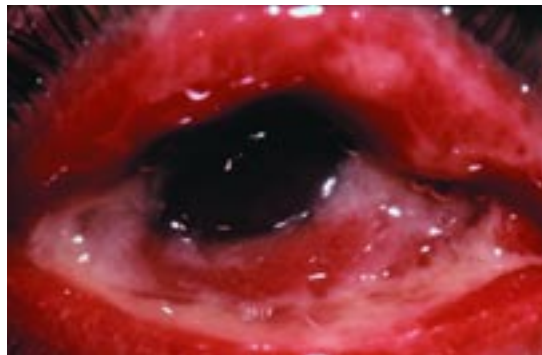

FIGURE 4. Hyperacute conjunctivitis caused by *Neisseria gonorrhoeae*. Note profuse discharge in a very red eye.

intramuscular injection.^{11,12} Because one-third of patients with gonorrheal infection also have chlamydial infection, treatment for both diseases is frequently prescribed.

Chlamydial infection, a sexually transmitted disease, can cause chronic follicular conjunctivitis. The genital tract infection may be asymptomatic. Diagnosis is made by swabbing the conjunctiva to culture for *Chlamydia trachomatis*. Treat systemically with either azithromycin (Zithromax) in a single 1-g oral dose or a 10–14-day course of either doxycycline (Doryx) 100 mg twice daily or erythromycin 250 mg four times daily.¹³

Allergic conjunctivitis is characterized by bilateral itching that worsens with scratching. Discharge is variable but is usually clear or white and stringy. Many patients have a history of seasonal or perennial allergies.

Remove offending allergens, if possible. Topical mast cell stabilizers and antihistamines relieve symptoms but may exacerbate underlying dry eye symptoms. A combined mast cell stabilizer and antihistamine such as olopatadine (Patanol), ketotifen (Zaditor), or epinastine (Elestat) can be given twice daily.^{14,15} Artificial tears can treat the associated dryness.

Topical corticosteroids may be used to treat an acute, severe episode but should not be used long-term. In fact, because it is difficult to differentiate between infectious and noninfectious eye conditions, and because treating some infections with corticosteroids by themselves can have grave consequences, we recommend that internists generally refrain from using them.

Oral antihistamines may relieve symp-

toms but are usually less effective than topical therapy.

Refer if symptoms do not resolve after 2 weeks of topical treatment.

Giant papillary conjunctivitis, most often seen in patients who wear soft contact lenses, presents with bilateral contact lens intolerance, itching, mucous discharge, and giant papillae on the upper palpebral conjunctiva.

Again, promptly refer any patient who wears contact lenses and presents with a red eye, owing to the risk of a vision-threatening corneal infection. The patient should stop wearing contact lenses for about 1 month, after which he or she can be refitted with new soft or gas-permeable lenses and taught better lens hygiene. During an acute episode, topical mast cell stabilizers are helpful for mild irritation, and topical steroids (prednisolone phosphate 1%) are helpful for more severe irritation. Topical steroids should never be used on a long-term basis because of possible adverse effects. Artificial tears can be used for dryness.¹⁵

Corneal abrasion

Corneal abrasions (traumatic removal of part of the corneal epithelium) are often caused by fingernails, paper, makeup applicators, metallic foreign bodies, or vegetative matter. Signs and symptoms are pain, photophobia, foreign body sensation, and watering. Depending on the location and severity of the abrasion, visual acuity may be decreased. To see abrasions better, instill fluorescein dye and examine the eye under a light with a cobalt blue filter or under Wood's lamp illumination (**FIGURE 5**).

1/3 of patients with gonorrhea also have Chlamydia

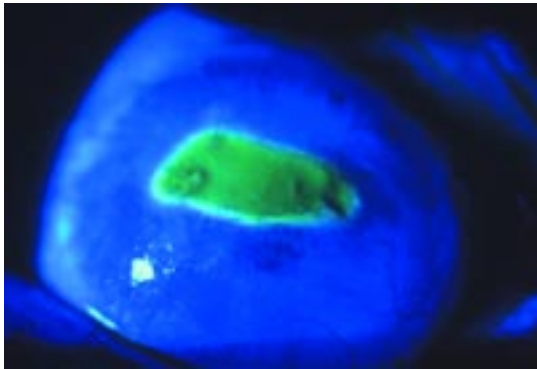


FIGURE 5. Corneal abrasion staining brilliantly with fluorescein dye under a cobalt blue filter.

Treat with topical antibiotics to prevent infection until the corneal epithelium has healed.¹⁶ However, most abrasions heal rapidly without sequelae because epithelial cells proliferate and migrate rapidly.

Refer if symptoms persist for longer than 48 hours or if pain suddenly worsens after the healing process has started.

Pingueculae and pterygia

A **pinguecula** is a small, yellow, benign growth on the nasal and temporal conjunctiva near the limbus. A **pterygium** is a wing-shaped band of fibrovascular tissue originating on the conjunctiva and extending onto the cornea. Both conditions are idiopathic but are believed to arise from chronic sun exposure.

Pingueculae can become inflamed and can cause eye redness and irritation. Treat conservatively with lubrication and judicious use of topical steroids; if irritation persists, pingueculae can be surgically removed.¹⁷

Episcleritis

Episcleritis is inflammation of the superficial vessels of the episclera, the connective tissue layer between the conjunctiva and the sclera. It presents with a sectoral area of redness (although it can be diffuse) and is not typically associated with pain, vision changes, or discharge. The condition tends to be recurrent and unilateral, but it can be bilateral or alternating. The underlying pathophysiology is believed to be autoimmune, although a systemic evaluation is often unrevealing.

Episcleritis is treated with topical corticosteroids or oral nonsteroidal anti-inflammatory

drugs (NSAIDs); refer if the disease persists or recurs.

Thyroid-related eye disease

Thyroid-associated ophthalmopathy, an autoimmune process, usually occurs in patients with known thyroid disease, although it may develop before other systemic symptoms. Symptoms can include irritation and double vision. Signs are bulging eyes, eyelid retraction, chemosis (swelling of the conjunctiva around the cornea), conjunctival injection, periorbital edema, and limited ocular motility.

Although most cases can be managed with lubrication, vision loss may occur due to corneal exposure or compressive optic neuropathy. Patients with significant visual changes should be referred immediately to an ophthalmologist.¹⁸

CONDITIONS NEEDING REFERRAL WITHIN 48 HOURS

Scleritis

Scleritis is inflammation of the deep vessels within the episclera. The red color appears more pronounced and more purplish than in episcleritis and does not blanch after phenylephrine drops are given. The eye is tender to palpation and may be painful enough to awaken the patient from sleep. Vision is not typically affected unless the cornea, anterior chamber, or posterior segment is involved.

Half of patients who have scleritis have an associated systemic disease, eg, rheumatoid arthritis (most common), other autoimmune diseases (Wegener granulomatosis, relapsing polychondritis, inflammatory bowel disease), or infections such as tuberculosis and syphilis.

Therefore, one should search for an underlying systemic condition with a thorough history, physical examination, chest radiography (for sarcoidosis and tuberculosis), and laboratory testing: antineutrophil cytoplasmic antibody test, fluorescent treponemal antibody absorption test, Lyme antibody test, (if in an endemic area), urinalysis, a complete blood count, and a comprehensive metabolic panel.

However, patients should be promptly referred to an ophthalmologist for diagnosis and management. Treatment can depend on

Thyroid eye disease may develop before other thyroid symptoms

the underlying diagnosis, and is often guided by the status of the scleritis. Mild scleritis can be treated with oral NSAIDs; more severe disease should be treated with oral corticosteroids with or without corticosteroid-sparing agents such as methotrexate, mycophenolate (CellCept), cyclophosphamide (Cytoxan, Neosar),^{19,20} or tumor necrosis factor-alpha antagonists such as infliximab (Remicade) or etanercept (Enbrel).²¹

Anterior uveitis

Uveitis is inflammation of the uvea (the pigmented layer between the sclera and retina that includes the iris, ciliary body, and choroid). Anterior uveitis is most commonly idiopathic but can be caused by trauma, secondary to herpes virus infection, or associated with the HLA-B27 antigen.

Acute anterior uveitis presents with pain, photophobia, and blurred vision. Perilimbal (circumcorneal) injection overlies the inflamed ciliary body. The pupil is often constricted and poorly reactive to light. Chronic anterior uveitis, defined as lasting more than 6 weeks, typically presents with gradual vision loss and floaters, rather than with the acute pain or severe redness of acute disease. Anterior uveitis is diagnosed by finding cells and flare in the anterior chamber using a slit lamp.

Refer patients to an ophthalmologist immediately to help avoid visual consequences.^{22,23} Treatment begins with topical corticosteroid drops and can also include oral corticosteroids or long-term immunosuppression with corticosteroid-sparing agents.

Nasolacrimal infections

Canaliculitis is an inflammation of the canaliculus, the conduit bringing tears from the eye to the nasolacrimal duct. It presents with mild, unilateral eye redness and a slight discharge that can be expressed from the punctum. It is most commonly caused by *Actinomyces israelii* infection, but *Candida* and *Aspergillus* species can also be involved.

Refer to an ophthalmologist for treatment, which involves mechanically removing the granular material from the canaliculi, combined with probing and irrigating the nasolacrimal system with penicillin G solution.

TABLE 2

Signs, symptoms, and conditions requiring referral to an ophthalmologist

Signs, symptoms, and patient history

Anterior segment abnormalities
Contact lens use
Corneal abnormalities
Severe headache
Marked purulent discharge
Nausea or vomiting
Pain
Trauma
Vision changes

Conditions requiring referral within 48 hours

Acute anterior uveitis
Canaliculitis
Dacryocystitis
Scleritis

Conditions requiring emergency referral

Acute angle-closure glaucoma
Corneal infections
Foreign body not easily removed in office

Dacryocystitis is inflammation of the lacrimal sac (the dilated upper end of the nasolacrimal duct) and is caused by obstruction of the duct. *Staphylococcus* and *Streptococcus* species are usually involved. Symptoms include unilateral pain, swelling, and redness over the lacrimal sac at the medial canthus of the eye. Purulent discharge can be expressed from the punctum.

Treatment consists of oral antibiotics with gram-positive coverage followed by surgery to open a passage for drainage from the lacrimal sac into the nasal cavity (dacryocystorhinotomy) once the infection has resolved.²⁴

CONDITIONS NEEDING IMMEDIATE REFERRAL

Conditions that require immediate referral to an ophthalmologist can be differentiated from more benign conditions by severe pain or vision loss (TABLE 2).

Acute angle-closure glaucoma

Patients suffering from an episode of acute angle-closure glaucoma report severe eye pain, seeing halos around lights, headache, nausea, and vomiting. Farsighted people and older people are at greater risk, owing to their eye

Search for an underlying systemic condition in patients with scleritis

anatomy. The eyeball is firm to palpation, and the pupil is mid-dilated and poorly reactive to light. The cornea may appear hazy.

Acute angle-closure glaucoma is an emergency and requires immediate lowering of intraocular pressure to avoid permanent vision loss.²⁵

Ocular foreign body

A foreign body lodged in or around the eye causes irritation, redness, and pain. Suspect it in any patient with an appropriate history.

Evert the upper eyelid to search for an occult object and remove any loosely adherent exogenous material on the conjunctiva or sclera. Topical broad-spectrum antibiotic ointments or drops can be started.

Immediately refer any patient with a foreign body that does not dislodge easily for removal and management, or if the patient was working near high-speed objects or with metal on metal (raising the possibility of fragments completely penetrating into the eye).²⁶

Keratitis (corneal inflammation)

Keratitis is inflammation at any level of the cornea.

Herpes keratitis presents with unilateral pain, photophobia, and watering. The most common physical finding is a branching ulcer seen with fluorescein staining under Wood's lamp illumination. Antiviral treatment with an oral medication (acyclovir [Zovirax] 400 mg five times daily) or topical medication (trifluridine 1% [Viroptic] nine times daily) shortens the course of the disease.^{27,28} Corticosteroid eye-drops should never be given for epithelial herpetic disease without consulting an ophthalmologist.

Bacterial keratitis threatens sight: infection with a virulent bacterium such as *Pseudomonas aeruginosa* can cause perforation of the cornea within 48 hours. Patients typically report the rapid onset of pain, photophobia, and decreased vision. Common predisposing risk factors include contact lens use and trauma. Examination reveals infiltration, ulceration, and edema of the cornea, and anterior chamber inflammation. Refer immediately to an ophthalmologist for evaluation and management; delaying treatment can have severe visual consequences.²⁹

REFERENCES

- Leibowitz HM. The red eye. *N Engl J Med* 2000; 343:345–351.
- Smith RE, Flowers CW Jr. Chronic blepharitis: a review. *CLAO J* 1995; 21:200–207.
- McCulley JP, Shine WE. Changing concepts in the diagnosis and management of blepharitis. *Cornea* 2000; 19:650–658.
- Smith RE. The tear film complex: pathogenesis and emerging therapies for dry eyes. *Cornea* 2005; 24:1–7.
- Tai MC, Cosar CB, Cohen EJ, Rapuano CJ, Laibson PR. The clinical efficacy of silicone punctal plug therapy. *Cornea* 2002; 21:135–139.
- McNab AA. Floppy eyelid syndrome and obstructive sleep apnea. *Ophthalmol Plast Reconstr Surg* 1997; 13:98–114.
- Alvarenga L, Marinho S, Mark M. Viral conjunctivitis. In: Krachmer JH, Mannis MJ, Holland EJ, eds. *Cornea*. Vol 1. 2nd ed. Philadelphia: Elsevier Mosby; 2005:629–638.
- Tarabishy AB, Hall GS, Procop GW, Jeng BH. Bacterial culture isolates from hospitalized pediatric patients with conjunctivitis. *Am J Ophthalmol* 2006; 142:678–680.
- Smith J. Bacterial conjunctivitis. *Clin Evid* 2004; 12:926–932.
- Sheikh A, Hurwitz B. Topical antibiotics for acute bacterial conjunctivitis: Cochrane systematic review and meta-analysis update. *Br J Gen Pract* 2005; 55:962–964.
- Ullman S, Roussel TJ, Forster RK. Gonococcal keratoconjunctivitis. *Surv Ophthalmol* 1987; 32:199–208.
- Deschenes J, Seamone C, Baines M. The ocular manifestations of sexually transmitted diseases. *Can J Ophthalmol* 1990; 25:177–185.
- Nakagawa H. Treatment of chlamydial conjunctivitis. *Ophthalmologica* 1997; 211(suppl 1):25–28.
- Owen CG, Shah A, Henshaw K, Smeeth L, Sheikh A. Topical treatments for seasonal allergic conjunctivitis: systematic review and meta-analysis of efficacy and effectiveness. *Br J Gen Pract* 2004; 54:451–456.
- Stahl JL, Barney NR. Ocular allergic disease. *Curr Opin Allergy Clin Immunol* 2004; 4:455–459.
- Galor A, Jeng B, Singh A. Current management of corneal abrasion: an evidence based review. *Compr Ophthalmol Update* 2005; 5:105–111.
- Hirst LW. The treatment of pterygium. *Surv Ophthalmol* 2003; 48:145–180.
- Mizen TR. Thyroid eye disease. *Semin Ophthalmol* 2003; 18:243–247.
- Pavesio CE, Meier FM. Systemic disorders associated with episcleritis and scleritis. *Curr Opin Ophthalmol* 2001; 12:471–478.
- Okhravi N, Oduduwa B, McCluskey P, Lightman S. Scleritis. *Surv Ophthalmol* 2005; 50:351–363.
- Smith JR, Levinson RD, Holland GN, et al. Differential efficacy of tumor necrosis factor inhibition in the management of inflammatory eye disease and associated rheumatic disease. *Arthritis Rheum* 2001; 45:252–257.
- Chang JH, Wakefield D. Uveitis: a global perspective. *Ocul Immunol Inflamm* 2002; 10:263–279.
- Chang JH, McCluskey PJ, Wakefield D. Acute anterior uveitis and HLA-B27. *Surv Ophthalmol* 2005; 50:364–388.
- Jordan D. Dacryoadenitis, dacryocystitis, and canaliculitis. In: Krachmer JH, Mannis MJ, Holland EJ, eds. *Cornea*. Vol 1. 2nd ed. Philadelphia: Elsevier Mosby; 2005:541–546.
- Saw SM, Gazzard G, Friedman DS. Interventions for angle-closure glaucoma: an evidence-based update. *Ophthalmology* 2003; 110:1869–1878.
- Khaw PT, Shah P, Elkington AR. Injury to the eye. *BMJ* 2004; 328:36–38.
- Suresh PS, Tullo AB. Herpes simplex keratitis. *Indian J Ophthalmol* 1999; 47:155–165.
- Tullo A. Pathogenesis and management of herpes simplex virus keratitis. *Eye* 2003; 17:919–922.
- Limberg MB. A review of bacterial keratitis and bacterial conjunctivitis. *Am J Ophthalmol* 1991; 112:25–95.

ADDRESS: Bennie H. Jeng, MD, Cole Eye Institute, I-32, Cleveland Clinic, 9500 Euclid Avenue, Cleveland, OH 44195; e-mail: jengb@ccf.org.