

ANDREW D. SMITH, MD, PhD

Radiology Institute, Cleveland Clinic

PAUL SCHOENHAGEN, MDCardiovascular Imaging Laboratory; Radiology
Institute and Heart and Vascular Institute,
Cleveland Clinic

CT imaging for acute aortic syndrome

ABSTRACT

Acute aortic syndrome can be due to acute aortic dissection, intramural hematoma, penetrating atherosclerotic ulcer, or unstable thoracic aneurysm. These life-threatening conditions are clinically indistinguishable, often presenting with acute chest pain. Contrast-enhanced, cardiac-gated multidetector computed tomography (CT) is a highly accurate imaging method for determining the cause of acute aortic syndrome.

KEY POINTS

Acute aortic syndrome typically presents with chest pain in patients with a history of hypertension. In young patients with aortic dissection, one should consider Marfan syndrome and other connective tissue abnormalities.

Cardiac gating is essential to avoid cardiac motion artifacts when evaluating the aortic root with contrast-enhanced multidetector CT.

Urgent surgical repair is often necessary, especially for acute aortic dissection and intramural hematoma in the ascending aorta and aortic arch, unstable or ruptured thoracic aneurysm, and symptomatic penetrating atherosclerotic ulcers.

ACTUTE AORTIC SYNDROME is often a life-threatening emergency, but because the presenting symptoms are nonspecific, it can be difficult to diagnose. Advances in computed tomography (CT) have made the diagnosis of acute aortic syndromes easier and faster.

See related editorial, page 25

This article discusses the role of CT in patients with acute aortic syndrome. We review the imaging features and common indications for treating the various causes of acute aortic syndrome, and we discuss the possibly wider future role of CT for evaluating acute chest pain.

ACUTE AORTIC SYNDROME PRESENTS WITH CHEST PAIN

Acute aortic syndrome is defined as chest pain due to an aortic condition such as acute aortic dissection, intramural hematoma, penetrating atherosclerotic ulcer, or unstable thoracic aneurysm (see below).¹

Risk factors² are listed in **TABLE 1**. Most patients have a history of hypertension; however, the blood pressure may be low at the time of presentation if the aorta has ruptured.

Of 464 patients included in the International Registry of Acute Aortic Dissection (IRAD),³ 85% had acute symptoms. The pain was more often described as sharp than as the classic tearing pain. More than 70% of patients had hypertension.³ Half of patients younger than 40 years had Marfan syndrome⁴; a young patient with Marfan features who presents with acute chest pain should be strongly suspected of having aortic dissection. A bicuspid aortic valve or a history of aortic surgery should also raise the suspicion of acute aortic dissection.⁴

TABLE 1

Risk factors for acute aortic syndrome

Acquired and congenital disorders of the aortic wall

Bicuspid aortic valve
Coarctation
Connective tissue disorders
Ehlers-Danlos syndrome
Familial annuloaortic ectasia
Familial aortic dissection
Marfan syndrome

Vascular inflammation

Behçet disease
Giant cell arteritis
Syphilitic aortitis
Takayasu arteritis

Multifactorial complex acquired conditions

Atherosclerosis
Diabetes
Dyslipidemia
Hypertension
Renal disease

Iatrogenic factors

Endovascular instrument
Valvular or aortic surgery

Modifiable risk factors

Cocaine or other illicit drug use
Smoking

**CT is nearly
100% sensitive
and specific for
evaluating
acute aortic
syndrome**

Acute chest pain is nonspecific

Acute chest pain is a nonspecific symptom: besides esophageal disease, it can be due to pneumonia, pulmonary embolism, pneumothorax, or acute coronary syndrome, and these must be ruled out on the basis of the history, physical findings, cardiac enzyme levels, electrocardiographic findings, and chest radiographic findings (FIGURE 1).

Furthermore, other possible manifestations of acute aortic syndrome are also nonspecific, eg, unexplained syncope, stroke, acute onset of congestive heart failure, pulse differentials (weaker pulses in one or more extremities), and malperfusion syndromes of the extremities or viscera.

Although aortic disease can sometimes cause acute coronary syndrome, keep in mind that acute coronary syndrome is more than 100 times more common than acute aortic dissection.³

IMAGING STUDIES FOR ACUTE AORTIC SYNDROME

Contrast-enhanced, cardiac-gated multidetector CT is nearly 100% sensitive and specific for evaluating acute aortic syndrome (TABLE 2).⁵

Transthoracic echocardiography is limited for evaluating acute aortic syndromes. However, transesophageal echocardiography is about 95% sensitive and specific for diagnosing acute aortic dissection, and intramural hematoma, and associated valvular regurgitation if the personnel who perform and interpret the test are highly experienced (although this level of expertise is not always available in the emergency department).⁵

CT has been improved

Several recent advances have contributed to CT's very high sensitivity and specificity for diagnosing aortic disease.

Multiple detectors. Today's CT machines have up to 64 rows of detectors, and this enables them to generate multiple simultaneous images with a slice thickness of less than 1 mm. Multidetector CT is also extremely fast: spiral imaging of the thorax can be done in a single breath-hold, which eliminates respiratory motion artifact.

Cardiac synchronization of the image acquisition (cardiac gating) should be performed whenever the heart, coronary vessels, pulmonary veins, or aortic root needs to be evaluated; without cardiac gating, motion of the aortic root wall during the cardiac cycle causes artifacts in more than 90% of CT studies,⁵⁻⁷ precluding adequate evaluation of these structures (FIGURE 2). In cardiac gating, CT is synchronized with electrocardiography, "freezing" the action at specific phases of the cardiac cycle, typically during diastole when heart motion is limited. Two types of cardiac synchronization are available: retrospective gating and prospective triggering.

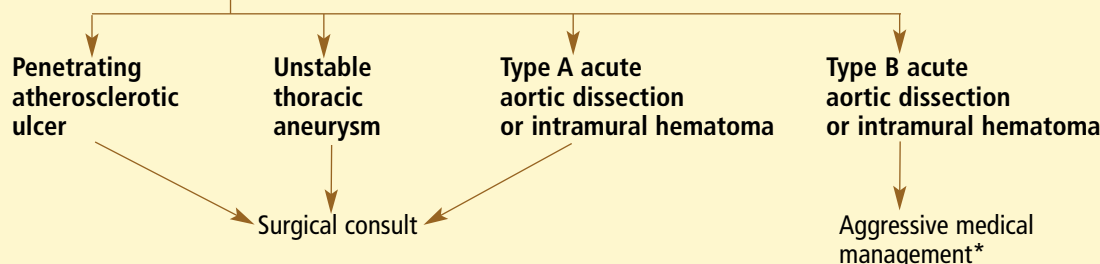
In retrospective gating ("spiral" or "helical" scanning), the x-ray source stays on throughout the cardiac cycle, but only the data from the desired part of the cardiac cycle are used to construct images. With this method, one can refine the images and remove motion abnormalities caused by irreg-

Patient presents with acute chest pain and history of hypertension

Perform history and physical examination and appropriate cardiac workup, including electrocardiography, laboratory tests, and chest radiography, to rule out acute coronary syndrome, pulmonary embolism, and other common causes of acute chest pain

Obtain intravenous access (18-gauge catheter in forearm or large-bore central line)

Order contrast-enhanced cardiac-gated multidetector computed tomography of the chest; include abdomen and pelvis if visceral organ or thrombotic symptoms are present



*Surgical consult is recommended if imaging features of visceral vessel ischemia, acute vessel thrombosis, or progression of aneurysmal dilatation are seen or if Marfan syndrome is suspected or known

FIGURE 1. Diagnostic strategy for acute aortic syndrome

TABLE 2

Imaging studies for acute aortic syndrome

IMAGING STUDY	ADVANTAGES	DISADVANTAGES
Cardiac-gated multidetector computed tomography	Highly specific and sensitive Can diagnose major causes of acute aortic syndrome Rapid scan and interpretation times	Large doses of ionizing radiation and contrast
Chest radiography	Very rapid result Very helpful to exclude nonaortic causes	Low-to-moderate specificity for acute aortic syndrome Low sensitivity for aortic pathology
Transesophageal echocardiography	Highly specific and sensitive for ascending aortic dissection and aneurysmal disease	Requires skilled personnel to perform and interpret Often unavailable in the emergency department
Angiography	Highly sensitive and specific for aortic dissection and aneurysmal disease	Invasive Requires contrast Cannot diagnose intramural hematoma
Magnetic resonance imaging	Highly specific and sensitive Can diagnose major causes of acute aortic syndrome Can be accurate without using contrast	Difficult to arrange in an emergency Prolonged scanning time and limited ability to manage unstable patients during scan

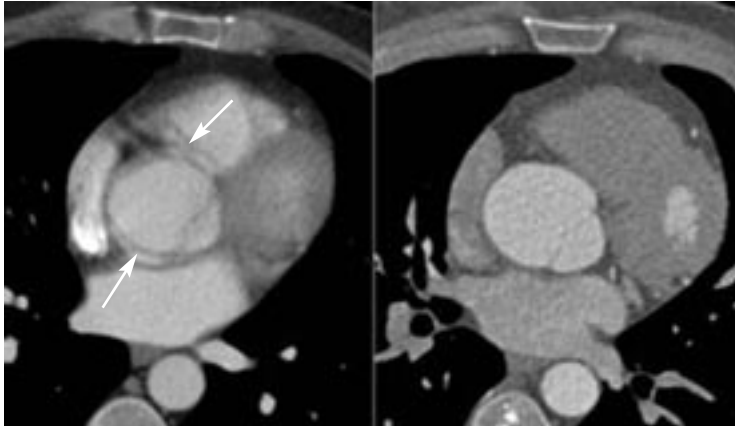
Without gating**With gating**

FIGURE 2. Left, an axial image from a contrast-enhanced, nongated CT study with 3-mm slices of the aortic root from a patient with acute aortic syndrome demonstrates cardiac motion artifact mimicking an acute aortic dissection (arrows, left panel). Right, contrast-enhanced, cardiac-gated CT with 0.75-mm slices of the aortic root reveals no dissection, although the aortic root is dilated.

The FDA has warned that gadolinium contrast is associated with nephrogenic systemic fibrosis in patients with poor renal function

ular heartbeats. This acquisition technique is currently the most frequently used.

In prospective triggering (“step and shoot”), the x-ray source is turned on only during diastole or another prespecified part of the cardiac cycle. An advantage is that the patient is exposed to less radiation. A disadvantage is that, afterward, one has very little ability to correct any motion artifacts that occurred due to changes in heart rate or dysrhythmias.

Other improvements that have increased the sensitivity and specificity of CT for evaluating acute aortic syndrome are the ability to generate images in multiple planes (multiplanar reformation) on dedicated computer workstations.

■ INTRAVENOUS CONTRAST IMPROVES IMAGING STUDIES

Intravenous contrast is necessary for CT to achieve its high accuracy for diagnosing aortic disease. However, it should be noted that in a CT study without contrast enhancement, an acute intramural hematoma is easily recognized by the higher Hounsfield-unit value of the blood products in the wall in comparison with the flowing blood in the lumen.

Check renal function

Before doing an intravenous contrast study, the serum creatinine level should be checked as a measure of renal function. Generally, if the serum creatinine concentration is less than 2.0 mg/dL and if the patient is hydrated and does not have diabetes, iodinated intravenous contrast can be given safely. If the patient’s serum creatinine level is between 1.5 and 2.0 mg/dL or if he or she is dehydrated or has diabetes, isosmolar iodinated contrast (iodixanol [Visipaque]) may be used.

An alternative that can be used for some patients with contrast allergy is gadolinium chelate, a paramagnetic compound normally used in magnetic resonance imaging. However, it is less radiopaque and much more expensive than iodinated contrast. It should be noted that the US Food and Drug Administration has recently warned that gadolinium contrast is associated with a systemic fibrosing disorder (nephrogenic systemic fibrosis) in patients with poor renal function (usually but not only in patients on dialysis).⁸ Because of this risk, gadolinium contrast should generally be used only in patients with good renal function who have had a prior serious adverse reaction to iodinated contrast.

Insert a large-gauge intravenous line

Proper intravenous access is needed for contrast injection. To opacify the aorta properly, the contrast must be injected rapidly (3.0 mL/second) using a power injector.

We recommend at least an 18-gauge peripheral intravenous catheter in the forearm or a large-bore central line (an introducer or Hickman catheter). Smaller-gauge intravenous lines (often located in smaller veins such as in the wrist) and most central lines placed without radiographic or surgical assistance (eg, triple-lumen central catheters) cannot safely handle such a rapid rate without infiltration or embolization. Some peripherally inserted central catheters are designed to handle high injection rates and are typically labeled with the injection rate.

■ USE OF CT IN SPECIFIC ACUTE AORTIC SYNDROMES

Acute aortic dissection

Aortic dissection occurs when a tear in the intimal layer allows blood to enter and accumulate

Two systems for classifying aortic dissections

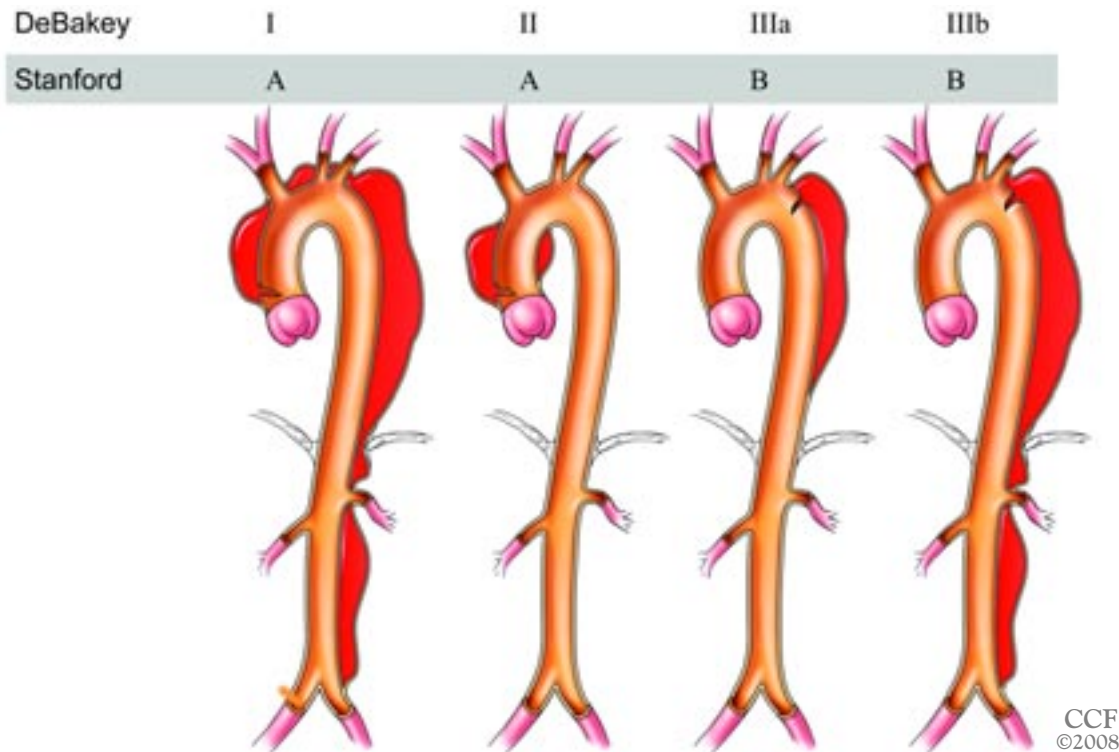


FIGURE 3. The DeBakey and Stanford systems

in the medial layer of the aorta, giving rise to a true lumen and a false lumen separated by an intimomedial flap. Dissection is considered to be acute if symptoms have been present for less than 2 weeks.⁹

Aortic dissections are often complex and can spiral around the aorta. The relationship of the intimomedial flap to the coronary arteries, aortic-arch branch vessels, and visceral branch vessels can be described on contrast-enhanced, cardiac-gated CT scans. The true lumen is often smaller and more opacified with contrast than the false lumen; intimal calcification often surrounds the true lumen. Slender areas of low attenuation (“cobwebs”) are occasionally seen in the false lumen. The false lumen also has beaked edges where it meets the true lumen, which usually appears rounder.^{2,10} The radiologist should state where the dissection begins and ends, determine if target vessel ischemia is evident, and assess for concomitant aneurysmal dilatation of the aorta. Contrast-enhanced, cardiac-gated multidetector CT of the aorta is necessary to properly evaluate the aortic root.

The Stanford system. Two systems exist for classifying the location of aortic dissections: the DeBakey system and the Stanford system (FIGURE 3). The Stanford system is more clinically useful and uses the following classification:

- Type A dissections involve the ascending aorta and aortic arch, with or without involvement of the descending aorta (FIGURE 4, FIGURE 5)
- Type B dissections involve the descending aorta beginning distal to the left subclavian artery (FIGURE 6).¹¹

Type A acute aortic dissection generally should be surgically repaired immediately to avoid fatal complications such as extension into the pericardium, pleural space, coronary arteries, or aortic valvular ring. It can also cause stroke, visceral ischemia, or circulatory failure.^{2,11} Without surgery, 20% of patients with type A acute aortic dissection die within 24 hours, 30% within 48 hours, 40% within 1 week, and 50% within 1 month.² The initial target is the tear in the ascending aorta: typically the aortic root or

The pain of acute aortic dissection is more often described as sharp rather than tearing

Type A dissection

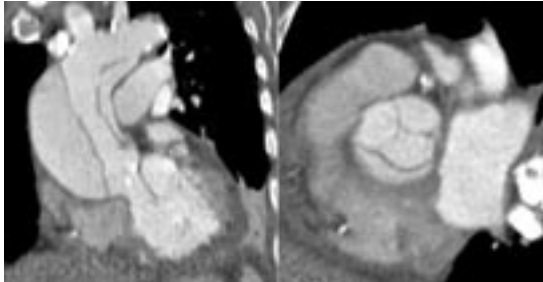


FIGURE 4. Coronal reformatted image (left) and oblique reformatted image (right) from contrast-enhanced, cardiac-gated computed tomography in a patient with acute aortic syndrome show a type A aortic dissection involving the aortic root, extending around the aortic valve, and aneurysmal dilatation of the aortic root.

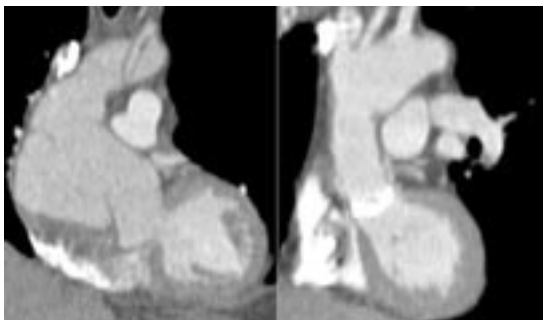


FIGURE 5. Oblique reformatted images from contrast-enhanced, cardiac-gated CT before (left) and after (right) surgical aortic root repair with aortic valve replacement in a patient who initially presented with acute aortic syndrome and had a type A acute aortic dissection with aneurysmal dilatation of the aortic root.

the ascending aorta or both are replaced and the aortic valve is repaired if indicated (**FIGURE 5**). Further aortic repair can often be delayed or may not be needed if the disease does not progress with medical management.

Without surgery, type B acute aortic dissection has a 30-day mortality rate of 10%.² Patients who develop renal failure, ischemic leg symptoms, or visceral ischemic symptoms with acute aortic syndrome should undergo imaging of the chest, abdomen, and pelvis. Type B acute aortic dissection without end-organ ischemia is typically managed with antihypertensive drugs. Except in patients with Marfan syndrome, only a small minority of

Type B dissection

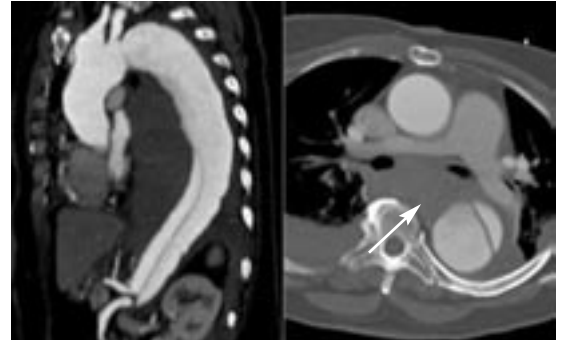


FIGURE 6. A coronal reformatted image (left) and an axial image (right) from contrast-enhanced, cardiac-gated CT in a patient who presented with acute aortic syndrome show a type B aortic dissection extending from the aortic arch (distal to the arch vessels) into the abdomen. Hemorrhage from recent rupture is seen in the left and right hemithorax and in the mediastinum (arrow).

type B dissections progress to type A dissections. Urgent aortic repair, often with an endovascular stent graft, is needed if imaging shows visceral vessel occlusion or ischemia, acute vessel thrombosis, or progression of aneurysmal dilatation.

Aortic intramural hematoma

Intramural hematomas are believed to be caused by a spontaneous hemorrhage of the vasa vasorum into the medial layer. They appear as crescent-shaped areas of increased attenuation with eccentric aortic wall-thickening and displacement of intimal calcifications. Hematomas do not enhance after contrast administration, and unlike dissections, they usually do not spiral around the aorta.

Intramural hematomas can also be classified according to the Stanford system. Type A intramural hematomas (**FIGURE 7**) have traditionally been urgently treated with surgery because they can progress to dissection, aortic rupture, or pericardial, pleural, or mediastinal hemorrhage. Recent evidence suggests that some patients with a limited type A intramural hematoma may be managed with aggressive medical therapy with frequent serial imaging to monitor progression of disease.^{2,12}

Type B intramural hematomas are typically managed with medical therapy and often

Suspect aortic dissection in a young person with Marfan features and acute chest pain

regress with time, although they can progress to dissection or aneurysmal formation.

Unstable thoracic aneurysm

Thoracic aneurysms are considered unstable if they are enlarging rapidly, show signs of imminent rupture, or have already ruptured (typically, the rupture is contained if the patient survives for imaging).

An aortic aneurysm is defined as a permanent dilation at least 150% of normal size, or larger than 5 cm if in the thoracic aorta or larger than 3 cm if in the abdominal aorta. True aneurysms involve all three layers of the aorta and tend to be fusiform; pseudoaneurysms tend to be saccular and often arise after trauma, surgery, or infection. Dilations are more likely to rupture if they grow at least 1 cm per year or measure 6.0 cm or more (if in the ascending aorta) or 7.2 cm (if in the descending thoracic aorta).¹³

How big the aortic diameter needs to be before invasive treatment—surgery or an endovascular procedure—is indicated depends on the characteristics of the individual patient, and an experienced surgeon should be involved in the decision. Patients are typically treated when a dilation in the ascending aorta reaches 5.5 cm or when one in the descending aorta reaches 6.0 cm; patients with Marfan syndrome should undergo invasive treatment for aneurysms with smaller diameters.^{14,15}

CT signs of imminent rupture include a high-attenuating crescent in the wall of the aorta, discontinuous calcification in a circumferentially calcified aorta, an aorta that conforms to the neighboring vertebral body (“draped” aorta), and an eccentric nipple shape to the aorta.^{16,17}

CT signs of rupture include hemothorax (usually in the left hemithorax) and stranding of the periaortic fat (FIGURE 8).

Penetrating atherosclerotic ulcer

When an atherosclerotic ulcer penetrates the aortic intima and extends into the media, it can lead to dissection, an intramural hematoma, aneurysm, or aortic rupture. Many penetrating aortic ulcers are focal lesions of the descending thoracic aorta. On contrast-enhanced, cardiac-gated CT they appear as contrast-filled irregular outpouch-

Aortic intramural hematoma

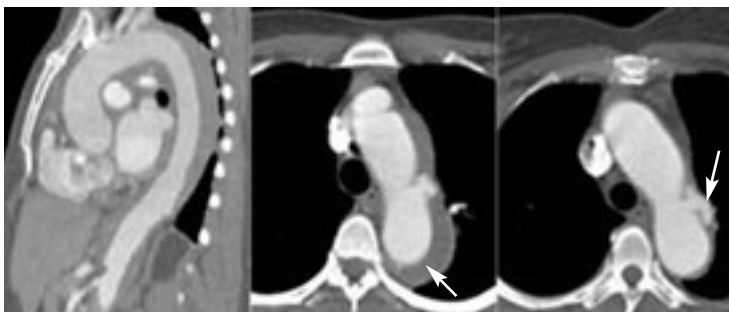


FIGURE 7. Coronal reformatted image (left) and axial image (middle) from contrast-enhanced, cardiac-gated CT in a patient with an acute type A intramural hematoma and a penetrating ulcer. Note the eccentric increased attenuation in the lateral aspect of the aortic arch representing the hematoma (arrow, middle panel) and the contrast-filled outpouching laterally representing the penetrating ulcer. Follow-up imaging several months later (right) shows that the intramural hematoma resolved although the penetrating ulcer persisted (arrow, right panel).

Rupture of the aorta

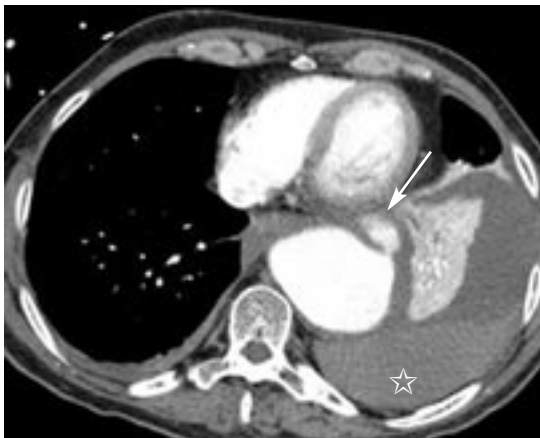

FIGURE 8. Axial image from contrast-enhanced, cardiac-gated CT in a patient with acute aortic syndrome and hypotension demonstrates aneurysmal dilatation of the descending thoracic aorta with a contained aortic rupture anterolaterally (arrow). A layering left hemothorax is also visible (star). The patient underwent urgent endovascular stent repair.

ings of the aortic wall (FIGURE 9).^{18,19}

Typical patients are elderly, and many have coexisting atherosclerotic atheromata and aneurysmal disease. Some experts contend that most saccular aneurysms are caused by penetrating atherosclerotic ulcers.¹⁹

Surgery to stabilize disease is recommended for a penetrating ulcer that causes acute aortic syndrome, or in patients with hemodynamic instability, aortic rupture, distal embolization, or a rapidly enlarging aorta. For a penetrating ulcer that is found incidentally in a patient without acute aortic syndrome, medical management of risk factors is recommended, with annual follow-up to see if it enlarges.

FUTURE USES OF IMAGING IN PATIENTS WITH ACUTE CHEST PAIN

Multidetector CT systems are undergoing rapid technical advances, including the recently released dual x-ray source multidetector CT scanners and the expected multidetector CTs with 128 to 256 detector rows. These and other developments will improve temporal resolution and decrease radiation exposure. Calcium artifacts—which hinder the evaluation of coronary arteries that contain atherosclerotic calcifications—will be reduced, thereby improving the accuracy of diagnosing acute coronary disease. As clinical knowledge increases based on the experience gained from the new technology, indications for imaging may expand.

CT of the chest performed for aortic disease provides information about other organ systems that may be considered when evaluating the cause of chest pain.²⁰

Evaluating pulmonary artery embolism

Although current contrast-enhanced, cardiac-gated CT of the aorta is not ideal for assessing the pulmonary arteries, it can almost always rule out central pulmonary artery thromboemboli and evaluate the more distal pulmonary arteries in a more limited way.

'Triple rule-out' CT

Several institutions now use CT (typically with 64-row scanners) to simultaneously eval-

Penetrating atherosclerotic ulcer

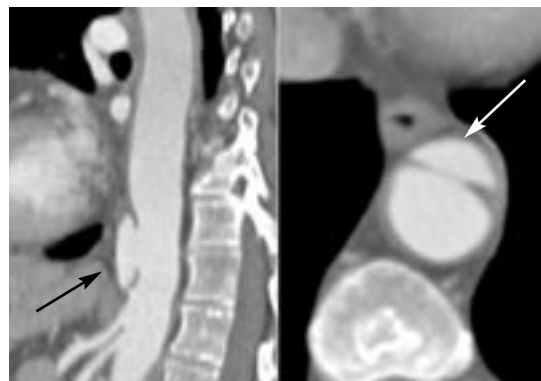


FIGURE 9. Coronal reformatted image (left) and axial image (right) from contrast-enhanced, cardiac-gated CT in a patient with acute aortic syndrome demonstrate a focal contrast-filled outpouching of the distal thoracic aorta consistent with a penetrating atherosclerotic ulcer (arrows).

uate patients for coronary artery disease, acute aortic syndrome, and pulmonary embolism—or “triple rule-out CT.” The study can be performed with dual intravenous contrast bolus techniques with nongated contrast-enhanced CT of the pulmonary arteries, rapidly followed by cardiac-gated, contrast-enhanced CT of the aorta. The pulmonary arteries can be evaluated on the initial nongated study, and the aorta (including the aortic root) and the coronary arteries are evaluated on the cardiac-gated portion. The timing of the contrast bolus for optimal opacification of the pulmonary arteries and the coronary arteries has yet to be determined.

The usefulness of assessing all three vascular beds with a single study is currently still unclear and the protocol is currently not routinely performed at Cleveland Clinic. Its sensitivity, specificity, and cost-benefit ratio are also unclear and must be determined in prospective clinical trials, which are currently under way.²¹

Penetrating aortic ulcers appear as contrast-filled, irregular outpouchings of the aortic wall

REFERENCES

1. Vilacosta I, Roman JA. Acute aortic syndrome. *Heart* 2001; 85:365–368.
2. Nienaber CA, Eagle KA. Aortic dissection: new frontiers in diagnosis and management: Part I: From etiology to diagnostic strategies. *Circulation* 2003; 108:628–635.
3. Hagan PG, Nienaber CA, Isselbacher EM, et al. The International Registry of Acute Aortic Dissection (IRAD): new insights into an old disease. *JAMA* 2000; 283:897–903.
4. Januzzi JL, Isselbacher EM, Fattori R, et al; International Registry of Aortic Dissection (IRAD). Characterizing the young patient with aortic dissection: results from the International Registry of Aortic Dissection (IRAD). *J Am Coll Cardiol* 2004; 43:665–669.
5. Manghat NE, Morgan-Hughes GJ, Roobottom CA. Multi-detector row computed tomography: imaging in acute aortic syndrome. *Clin*

- Radiol 2005; 60:1256–1267.
6. **Roos JE, Willmann JK, Weishaupt D, Lachat M, Marincek B, Hilfiker PR.** Thoracic aorta: motion artifact reduction with retrospective and prospective electrocardiography-assisted multi-detector row CT. *Radiology* 2002; 222:271–277.
 7. **Cademartiri F, Pavone P.** Advantages of retrospective ECG-gating in cardio-thoracic imaging with 16-row multislice computed tomography. *Acta Biomed* 2003; 74:126–130.
 8. **US Food and Drug Administration.** Public Health Advisory: Gadolinium-containing Contrast Agents for Magnetic Resonance Imaging (MRI): Omniscan, OptiMARK, Magnevist, ProHance, and MultiHance. US Food and Drug Administration; June 8, 2006, updated May 23, 2007. http://www.fda.gov/cder/drug/advisory/gadolinium_agents.htm.
 9. **Hirst AE Jr, Johns VJ Jr, Kime SW Jr.** Dissecting aneurysm of the aorta: a review of 505 cases. *Medicine (Baltimore)* 1958; 37:217–279.
 10. **Batra P, Bigoni B, Manning J, et al.** Pitfalls in the diagnosis of thoracic aortic dissection at CT angiography. *Radiographics* 2000; 20:309–320.
 11. **Daily PO, Trueblood HW, Stinson EB, Wuerfle RD, Shumway NE.** Management of acute aortic dissections. *Ann Thorac Surg* 1970; 10:237–247.
 12. **Yamada T, Tada S, Harada J.** Aortic dissection without intimal rupture: diagnosis with MR imaging and CT. *Radiology* 1988; 168:347–352.
 13. **Coady MA, Rizzo JA, Elefteriades JA.** Developing surgical interventional criteria for thoracic aortic aneurysms. *Cardiol Clin* 1999; 17:827–839.
 14. **Svensson LG, Khitin L.** Aortic cross-sectional area/height ratio timing of aortic surgery in asymptomatic patients with Marfan syndrome. *J Thorac Cardiovasc Surg* 2002; 123:360–361.
 15. **Svensson LG, Kim KH, Lytle BW, Cosgrove DM.** Relationship of aortic cross-sectional area to height ratio and the risk of aortic dissection in patients with bicuspid aortic valves. *J Thorac Cardiovasc Surg* 2003; 126:892–893.
 16. **Bhalla S, West OC.** CT of nontraumatic thoracic aortic emergencies. *Semin Ultrasound CT MR* 2005; 26:281–304.
 17. **Posniak HV, Olson MC, Demos TC, Benjoya RA, Marsan RE.** CT of thoracic aortic aneurysms. *Radiographics* 1990; 10:839–855.
 18. **Castaner E, Andreu M, Gallardo X, Mata JM, Cabezu MA, Pallardo Y.** CT in nontraumatic acute thoracic aortic disease: typical and atypical features and complications. *Radiographics* 2003; 23:S93–S110.
 19. **Quint LE, Williams DM, Francis IR, et al.** Ulcer-like lesions of the aorta: imaging features and natural history. *Radiology* 2001; 218:719–723.
 20. **Stillman AE, Oudkerk M, Ackerman M, et al.** Use of multidetector computed tomography for the assessment of acute chest pain: a consensus statement of the North American Society of Cardiac Imaging and the European Society of Cardiac Radiology. *Int J Cardiovasc Imaging* 2007; 23:415–427.
 21. **Savino G, Herzog C, Costello P, Schoepf UJ.** 64 slice cardiovascular CT in the emergency department: concepts and first experiences. *Radiol Med (Torino)* 2006; 111:481–496.

ADDRESS: Paul Schoenhagen, MD, Cardiovascular Imaging, Hb6, Cleveland Clinic, 9500 Euclid Avenue, Cleveland, OH 44195; schoenp@ccf.org.