

MARIA A. NAGEL, MDDepartment of Neurology, University of
Colorado Health Sciences Center, Denver**DONALD H. GILDEN, MD**Departments of Neurology and Microbiology,
University of Colorado Health Sciences
Center, Denver

The protean neurologic manifestations of varicella-zoster virus infection

ABSTRACT

Multiple neurologic complications may follow the reactivation of varicella-zoster virus (VZV), including herpes zoster (also known as zoster or shingles), postherpetic neuralgia, vasculopathy, myelitis, necrotizing retinitis, and zoster sine herpette (pain without rash). These conditions can be difficult to recognize, especially as several can occur without rash.

KEY POINTS

The most common sequela of herpes zoster is postherpetic neuralgia, which can persist for months and sometimes years after the rash resolves.

VZV vasculopathy can present as transient ischemic attacks, ischemic or hemorrhagic stroke, or aneurysm.

Vasculopathy and neurologic complications of VZV are best diagnosed by detecting VZV DNA in bodily fluids or tissues or anti-VZV immunoglobulin G in the cerebrospinal fluid.

Most neurologic complications of VZV reactivation require antiviral treatment.

It is prudent to recommend the recently approved zoster vaccine for healthy adults older than 60 who are seropositive for VZV.

VARICELLA-ZOSTER VIRUS (VZV) is an exclusively human, highly neurotropic alphaherpesvirus. Primary infection causes chickenpox, after which the virus becomes latent in cranial nerve ganglia, dorsal root ganglia, and autonomic ganglia along the entire neuraxis. Decades later, VZV can reactivate to cause a number of neurologic conditions.

This article discusses the protean manifestations of VZV reactivation and their diagnosis and treatment.

VZV REACTIVATION HAS MANY MANIFESTATIONS

VZV reactivation can produce a number of neurologic complications:

- Herpes zoster (shingles), manifesting as pain and rash in up to three dermatomes
- Postherpetic neuralgia, the most common sequela of zoster, is pain that persists for months and sometimes years after the rash resolves
- Vasculopathy, manifesting as transient ischemic attacks, ischemic or hemorrhagic stroke, or aneurysm
- Myelitis, which is often progressive and sometimes fatal in immunocompromised patients
- Zoster sine herpette—neurologic disease without rash (formerly called dermatomal-distribution pain without rash), which can cause meningoencephalitis, vasculopathy, myelitis, cerebellar ataxia, and polyneuritis cranialis
- Necrotizing retinitis (of which VZV reactivation is the most common cause), leading to visual loss.

Herpes zoster (shingles)

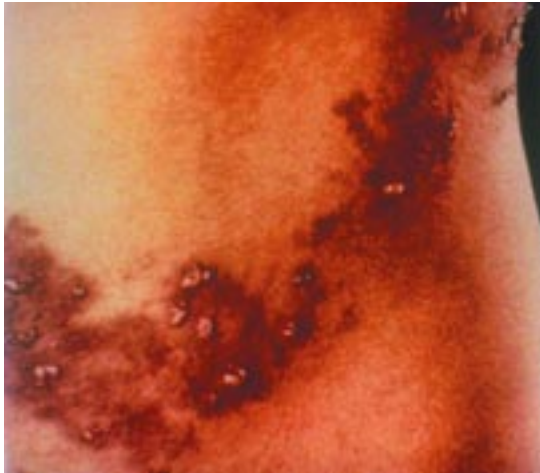


FIGURE 1. Herpes zoster in the lumbar region.

■ HERPES ZOSTER: TYPICALLY IN OLDER PATIENTS

Zoster typically occurs in people older than 60 years,¹ as VZV-specific cell-mediated immunity declines with age. Other causes of immune deficiency that can lead to zoster are cancer chemotherapy, antirejection therapy in transplant recipients, and acquired immunodeficiency syndrome (AIDS).² In fact, zoster in an otherwise young, healthy patient may be the first manifestation of human immunodeficiency virus (HIV) infection.³ Varicella in infancy predisposes to zoster earlier in adulthood.⁴

Zoster is presumed to be caused by retrograde transport of the virus from ganglia to the skin in a host partially immune to VZV. However, VZV can be isolated from the blood of immunocompromised patients with localized and disseminated zoster, suggesting that the disease can spread through the blood stream.⁵

A painful rash

Zoster rash is a vesicular eruption on an erythematous base in one to three dermatomes (**FIGURE 1**), usually accompanied by severe, sharp, lancinating, radicular pain, itching, and unpleasant, abnormal sensations (dysesthesias). Patients may also have decreased sensation in the affected area, while the skin is exquisitely sensitive to touch (allodynia).

The cardinal pathologic features of zoster are inflammation and hemorrhagic necrosis with associated neuritis, localized leptomeningitis, unilateral segmental poliomyelitis, and degeneration of related motor and sensory roots.^{6,7} Demyelination has also been observed in areas with mononuclear cell infiltration and microglial proliferation. Intranuclear inclusions, viral antigen, and herpesvirus particles have been detected in acutely infected ganglia.^{8–11} Magnetic resonance imaging may show enhancement of ganglia and the affected nerve roots.¹²

Can affect any part of the body

Zoster can affect any level of the neuraxis. The most common site is the chest.

The face is the next most commonly affected area, typically in the ophthalmic distribution of the trigeminal nerve, although nearly any cranial nerve may be involved. Herpes zoster ophthalmicus involves VZV reactivation in the first division of the trigeminal (fifth cranial) nerve. It is often accompanied by zoster keratitis, which can lead to blindness if it is not treated. Patients with visual symptoms should undergo an immediate slit-lamp examination by an ophthalmologist, especially if skin lesions extend to the nose (Hutchinson sign).

Involvement of the optic nerves with subsequent optic neuritis, neuropathy, or both occurs rarely in association with herpes zoster ophthalmicus and other cutaneous zoster eruptions.^{13,14}


Ophthalmoplegia (paralysis of the ocular muscles) following zoster involves cranial nerves III, VI, and less frequently IV.^{13,15–17}

Involvement of the maxillary and mandibular distribution of the trigeminal nerve can produce osteonecrosis and spontaneous tooth exfoliation.^{18–20}

Involvement of the geniculate ganglion of cranial nerve VII causes weakness or paralysis of ipsilateral facial muscles, with rash in the external auditory canal, involving the tympanic membrane (zoster oticus), or on the ipsilateral anterior two thirds of the tongue or hard palate. Lesions in these areas are often missed.

Ramsay Hunt syndrome is characterized by peripheral facial weakness and zoster oticus.²¹ Although it is traditionally defined as lower motor neuron facial palsy with zoster

Zoster typically occurs in people older than 60 years



oticus, many patients also have tinnitus, hearing loss, nausea, vomiting, vertigo, and nystagmus, indicating involvement not only of the geniculate ganglion, but also of cranial nerve VIII within the bony facial canal. Cranial nerves V, VI, IX, and X are also involved in rare instances.²²

Compared with Bell palsy (peripheral facial paralysis without rash), Ramsay Hunt syndrome often initially involves more severe facial paralysis, and patients are less likely to recover completely.²³ Peripheral facial paralysis caused by VZV may develop without rash, as demonstrated by a fourfold rise in antibody to VZV or by VZV DNA in auricular skin, blood mononuclear cells, middle ear fluid, or saliva.²⁴ Patients with idiopathic facial weakness should be suspected of having this variant of zoster sine herpete.

Zoster in the cervical or lumbar nerve distribution may be followed by lower motor neuron-type weakness in the arm or leg, respectively.^{25,26}

Cervical zoster may be followed by diaphragmatic weakness in rare cases.²⁷ Rare cases of thoracic zoster have been associated with abdominal muscle weakness, which can result in abdominal herniation.²⁸

Treatment:

Analgesics, sometimes antiviral drugs

Treatment decisions about zoster should take into account the patient's age and immune status.

In immunocompetent patients younger than age 50, analgesics are used to relieve pain. Antiviral drugs—famciclovir (Famvir) 500 mg orally three times daily or valacyclovir (Valtrex) 1 g orally three times daily—are not required but speed healing of the rash. At any age, zoster in the distribution of the trigeminal nerve should be treated with famciclovir 500 mg three times daily.

In immunocompetent patients age 50 and older, treatment with both analgesic and antiviral drugs is recommended and is essential in patients with ophthalmic-distribution zoster. More patients with Ramsay Hunt syndrome recover if they are treated within 7 days of onset,^{29,30} although this has not yet been proven in prospective randomized trials. We also use prednisone 60 mg orally for 3 to 5 days

A new live-virus VZV vaccine is approved for adults

Oxman et al,¹⁰⁵ in a prospective, double-blind trial, vaccinated more than 38,000 healthy men and women age 60 and older (median age 69 years) with an attenuated Oka/Merck VZV vaccine or placebo. The vaccine contained 18,700 to 60,000 pock-forming units of virus (for comparison, the vaccine given to American children since 1995 contains about 1,350 pock-forming units). After 3 years, subjects in the vaccination group had a 51% lower incidence of shingles, a 66% lower incidence of postherpetic neuralgia, and a 61% lower burden of illness compared with the placebo group. The incidence of zoster in the placebo group was 11.1 per 1,000-person years, similar to the rate found in an epidemiologic survey done in the early 1990s: more than 10 cases per 1,000-person years in people older than 75 years.¹⁰⁶

Like the live-virus varicella vaccine used in children, the adult vaccine appears to be safe and clinically effective. In the first 42 days after vaccination, serious adverse events (including death) occurred in 1.4% of both the vaccine and placebo recipients. In a subset of more than 6,000 subjects who kept daily diaries of minor adverse effects for 42 days, injection-site erythema, pain, tenderness, swelling, or pruritus were reported in 48% of vaccine recipients vs 17% of placebo recipients, and serious adverse events were significantly more frequent in vaccine recipients (1.9%) than placebo recipients (1.3%, $P = .03$), although no specific

adverse event emerged.

Although the Oka/Merck VZV vaccine for children on rare occasions unmasks an immunodeficiency disorder, no cases of disseminated zoster were reported that might have been attributed to zoster vaccine in a person with an undiagnosed lymphoma, leukemia, or other immunodeficiency disorder.

The incidence of side effects in elderly subjects (age ≥ 70) vs younger subjects was not examined but might be important in future analyses, because the at-risk population over age 70 is projected to increase substantially in the coming decades.

In 2006, zoster vaccine received approval from the US Food and Drug Administration (FDA) for healthy adults older than age 60 who are seropositive for VZV. Zoster vaccine increases cell-mediated immunity to VZV in this population, and the boost is likely to last for decades. Because zoster and postherpetic neuralgia are common and serious, it seems prudent to recommend zoster vaccine. The US Census Bureau projects that by the year 2050, more than 21 million Americans will be 85 years old or older.¹⁰⁷ Widespread vaccination would help to further evaluate risk in general as well as efficacy in the very elderly. The FDA has not approved the VZV vaccine for elderly adults who have had zoster or for immunocompromised individuals.

to reduce the inflammatory response, although double-blind, placebo-controlled studies to confirm additional efficacy are also lacking.

In immunocompromised patients, intravenous acyclovir (Zovirax) 5 to 10 mg/kg three times daily for 5 to 7 days is recommended.

■ POSTHERPETIC NEURALGIA CAN PERSIST FOR YEARS

More than 40% of zoster patients older than 60 years develop postherpetic neuralgia, characterized by constant severe stabbing pain or by burning dysesthetic pain that persists for months and sometimes years after the rash resolves.³¹

The cause and pathogenesis of postherpetic neuralgia are unknown. One theory is that neurons in the ganglia or even in the spinal cord are altered so they are more excitable. Another theory is that the virus persists or continues to reproduce slowly in the ganglia. The theories are not mutually exclusive. Evidence for the theory of low-level ganglionitis is that many patients with postherpetic neuralgia have VZV DNA and proteins in their blood mononuclear cells,^{32–36} and some patients respond to antiviral treatment.³⁷

Management is primarily supportive

Although postherpetic neuralgia is not life-threatening, it is difficult to manage.

Treatment is supportive, with neuroleptic drugs and various analgesics, including opiates, to alleviate pain. No universally accepted treatment exists, but the following can be used:

- **Topical agents:** lidocaine 5% patches (Lidoderm) with up to three patches applied at one time for up to 12 hours within a 24-hour period; trolamine salicylate (Aspercreme); aloe vera (Flexall 454). These are applied directly to the painful area.
- **Gabapentin** (Neurontin), starting at 300 mg by mouth daily and gradually increased to a maximum of 3,600 mg per day (divided into three doses).^{38,39} Combination treatment with morphine and gabapentin decreases pain better than either drug alone or placebo.⁴⁰
- **Tricyclic antidepressants**, including amitriptyline (Elavil 10–25 mg orally at bedtime with a maximum dose of 150–200 mg/day), nortriptyline (Pamelor), maprotiline (Ludiomil), and desipramine (Norpramin).
- **Carbamazepine** (Carbatrol, Tegretol) 600 to 1,200 mg daily.
- **Pregabalin** (Lyrica) 150 to 300 mg orally daily as 75- to 150-mg doses twice daily or as 50- to 100-mg doses three times daily. If only minimal relief is obtained with 300 mg daily after 2 weeks, the dose can be increased to a maximum of 600 mg per day in two or three divided doses.
- **Controlled-release oxycodone** (Oxycontin) 10 to 40 mg orally every 12 hours.
- **Controlled-release morphine sulfate and tricyclic antidepressants.**⁴¹
- **Levetiracetam** (Keppra) can be given at 500 mg orally per day and titrated upward, as tolerated, by 500 mg per week to a maximum dose of 1,500 mg twice a day.⁴²
- **Diazepam** (Valium) 2 mg three times daily can be considered to supplement any of the above agents.

Antiviral therapy may help

Oral acyclovir, famciclovir, or valacyclovir reduces the duration and severity of pain after zoster.^{43–45} In a recent prospective, open-label phase I/II trial,³⁷ 15 patients with moderate to severe postherpetic neuralgia received intravenous acyclovir for 2 weeks followed by oral

Varicella zoster virus vasculopathy

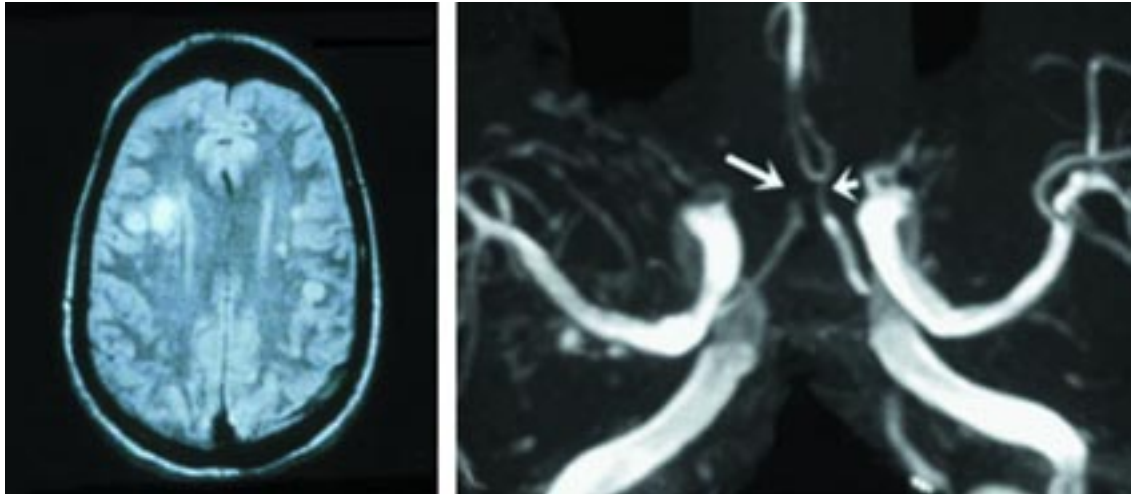


FIGURE 2. Left, magnetic resonance imaging of the brain shows multiple areas of infarction in both hemispheres, primarily involving white matter and gray-white matter junctions. Right, three-dimensional time-of-flight magnetic resonance angiography of the circle of Willis shows marked narrowing of the anterior cerebral arteries with occlusion on the right (long arrow) and marked stenosis on the left (short arrow).

MAGNETIC RESONANCE IMAGE REPRINTED FROM GILDEN DH, MAHALINGAM R, COHRS RJ, KLEINSCHMIDT-DEMASTERS BK, FORGHANI B. THE PROTEAN MANIFESTATIONS OF VARICELLA-ZOSTER VIRUS VASCULOPATHY. *J NEUROVIROL* 2002; 8(SUPPL 2):75–79.

MAGNETIC RESONANCE ANGIOGRAM REPRINTED FROM GILDEN DH, LIPTON HL, WOLF JS, ET AL. TWO PATIENTS WITH UNUSUAL FORMS OF VARICELLA-ZOSTER VIRUS VASCULOPATHY. *N ENGL J MED* 2002; 347:1500–1503. REPRINTED WITH PERMISSION FROM MASSACHUSETTS MEDICAL SOCIETY. COPYRIGHT 2002. ALL RIGHTS RESERVED.

Without treatment, the mortality rate in VZV vasculopathy is 25%

valacyclovir for 1 month; 8 (53%) reported improved pain.

■ VZV VASCULOPATHY CAN CAUSE STROKE

VZV vasculopathy results from virus infection in large or small cerebral arteries.

The most common presentation in elderly patients who are not otherwise immunocompromised is zoster in the distribution of the trigeminal nerve, followed days to weeks later by contralateral hemiplegia. Some patients present with some combination of headache, fever, mental status changes, transient ischemic attacks, and focal deficit (stroke). VZV vasculopathy often occurs without rash.^{46,47}

The clinical spectrum of VZV vasculopathy is protean. For example, one case of VZV vasculopathy was characterized by posterior ischemic optic neuropathy with normal findings on cerebral angiography and magnetic resonance imaging.⁴⁸ Cerebral aneurysms

and hemorrhage can also develop from viral invasion of vessels.^{49,50}

Laboratory and imaging findings

Cerebrospinal fluid analysis usually shows mononuclear pleocytosis (increased number of cells) and oligoclonal bands on electrophoresis. The oligoclonal immunoglobulin G (IgG) is antibody directed against VZV.⁵¹

Brain imaging usually reveals ischemic or hemorrhagic infarcts or both, more deep-seated than cortical, and at gray-white matter junctions. Cerebral angiography also reveals areas of focal arterial stenosis or occlusion (FIGURE 2).

On pathological studies, macroscopic lesions can be seen at the junction of gray and white matter. Microscopically, the virus is present in affected cerebral arteries⁵² but not in areas of brain infarction, although in chronic cases virus may be seen in brain parenchyma close to arteries and veins. The primary site of VZV is in cerebral arteries that contain multi-nucleated giant cells, Cowdry A inclusion bodies, and herpes virus

Varicella-zoster virus myelitis

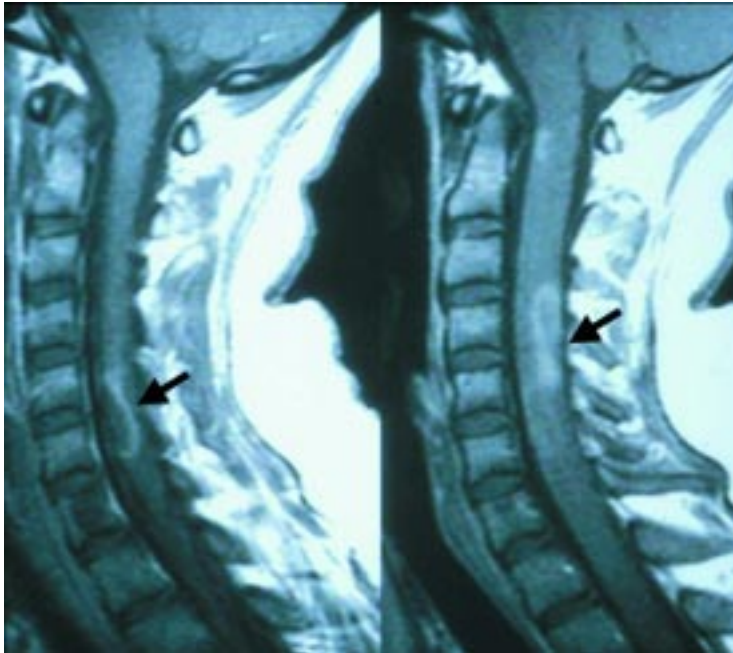


FIGURE 3. Magnetic resonance imaging abnormalities in a patient with varicella-zoster virus myelitis. Note the cervical, longitudinal, serpiginous enhancing lesions (arrows).

In many cases of VZV vasculopathy, the CSF contains anti-VZV IgG but no VZV DNA

particles. Postmortem analysis has revealed not only VZV DNA but also VZV antigen in cerebral vessels.⁵²

Diagnosis requires VZV DNA or antibodies in cerebrospinal fluid

Confirmation of VZV vasculopathy requires the finding of VZV DNA by polymerase chain reaction (PCR) or of anti-VZV IgG in the cerebrospinal fluid. Both tests must be performed to confirm VZV vasculopathy, and only negative results for both tests can exclude the diagnosis.⁵³

Although PCR is the best test to diagnose herpes simplex virus (HSV) encephalitis, in many cases of VZV vasculopathy the cerebrospinal fluid does not contain PCR-amplifiable VZV DNA but does contain anti-VZV IgG.^{46–48} This is probably because the disease is chronic, with productive viral infection usually restricted to cerebral arteries. Only in protracted cases of VZV vasculopathy is the virus found in the cerebral parenchyma.⁵⁴ In addition, because VZV vasculopathy is chronic, the cerebrospinal fluid is more likely to contain anti-VZV IgG than VZV DNA. In

contrast, in acute HSV encephalitis, HSV DNA is present early in the course of disease, while antiviral antibody is not detected until the second week.⁵⁵

Patients with VZV vasculopathy tend to have neurologic symptoms, signs, and abnormalities on cerebrospinal fluid analysis and on imaging studies similar to those in patients with other vasculopathies or vasculitides. All patients who are being evaluated for a vasculopathy or vasculitis should also be evaluated for VZV, particularly because it can occur without rash. Rapid diagnosis of VZV vasculopathy is important: the death rate without treatment is 25%,⁵⁶ and treatment with intravenous acyclovir may cure it even if neurologic disease has been present for months.⁴⁸

■ VZV MYELITIS CAN BE SELF-LIMITING OR PROGRESSIVE

Two clinical presentations of VZV myelitis predominate.

A self-limiting, monophasic, spastic paraparesis with or without sensory features and sphincter problems usually occurs in immunocompetent patients, days to weeks after acute varicella or zoster. The pathogenesis is unknown. The cerebrospinal fluid usually has a mild mononuclear pleocytosis with normal or slightly elevated protein. Steroids are used for treatment,⁵⁷ although sometimes the condition improves spontaneously.⁵⁸

An insidious, progressive, and sometimes fatal myelitis is seen mostly in immunocompromised patients and, because of the AIDS epidemic, has become the more common presentation. Importantly, VZV myelitis may develop without rash.

Diagnosis

Magnetic resonance imaging shows enhancing lesions that are longitudinal and serpiginous (FIGURE 3). The cerebrospinal fluid has a mild, predominantly mononuclear pleocytosis with elevated protein. The diagnosis is confirmed by finding VZV-specific DNA or anti-VZV IgG in cerebrospinal fluid.⁵⁹ Pathologic and virologic analyses of the spinal cord from fatal cases have revealed frank invasion of VZV in the parenchyma⁶⁰ and, in some instances, spread of the virus to adjacent nerve roots.⁶¹

Outer retinal necrosis

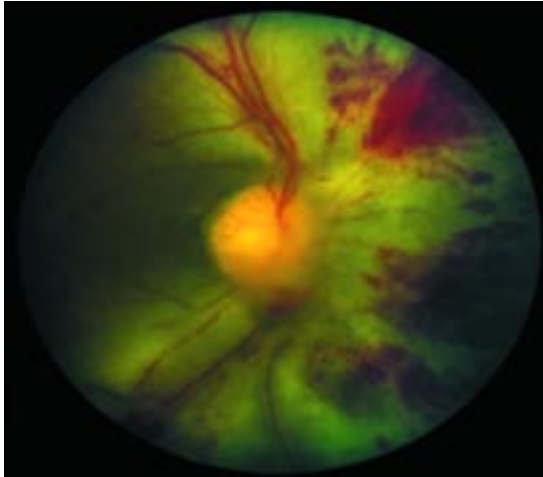


FIGURE 4. Fundus photograph of a patient with VZV vasculopathy and progressive outer retinal necrosis. Note the diffuse retinal hemorrhages and whitening with macular involvement.

REPRINTED FROM NAKAMOTO BK, DOROTHEO EU, BIOUSSE V, TANG RA, SCHIFFMAN JS, NEWMAN NJ. PROGRESSIVE OUTER RETINAL NECROSIS PRESENTING WITH ISOLATED OPTIC NEUROPATHY. *NEUROLOGY* 2004; 63:2423–2425. REPRINTED WITH PERMISSION FROM LIPPINCOTT WILLIAMS & WILKINS PUBLISHERS.

Acute retinal necrosis can occur in immuno-competent or immuno-compromised patients

Treatment

Some cases have responded to antiviral therapy.^{62–64} Early diagnosis and aggressive treatment with intravenous acyclovir has been helpful, even in immunocompromised patients.⁶² The benefit of treating with steroids in addition to antiviral agents is unknown.

■ VZV RETINAL NECROSIS: TREATMENT MAY SAVE SIGHT

VZV can cause necrotizing retinitis, which can manifest as two clinical syndromes: acute retinal necrosis and progressive outer retinal necrosis.

Acute retinal necrosis

Acute retinal necrosis can occur in immuno-competent or immunocompromised patients. It can be caused by VZV,⁶⁵ HSV 1, or HSV 2.^{66,67} Patients present with periorbital pain and floaters with hazy vision and loss of peripheral vision. The necrosis, caused by occlusive vasculopathy, is focal, being located in well-demarcated areas beyond the major temporal vascular arcades, and it extends the full thickness of the retina. A distinguishing

feature is prominent inflammation in the anterior chamber and vitreous body.⁶⁸

Treatment is typically with intravenous acyclovir, corticosteroids, and aspirin, followed by oral acyclovir.⁶⁹ Intravitreal injections of foscarnet (Foscavir) and oral acyclovir have been used in mild cases that have been caught early. Acute retinal necrosis due to VZV has also been successfully treated with brivudine (not available in the United States) and valganciclovir (Valcyte).⁷⁰

Progressive outer retinal necrosis

Progressive outer retinal necrosis is almost always caused by VZV. It is the second most common opportunistic retinal infection among patients with AIDS in North America (cytomegalovirus is the most common).⁷¹ It occurs primarily in patients with AIDS who have CD4 counts lower than 10 cells/mm³ and in other patients with immunosuppression.^{72,73}

Progressive outer retinal necrosis may be preceded by retrobulbar optic neuritis and aseptic meningitis,⁷⁴ central retinal artery occlusion, or ophthalmic-distribution zoster,⁷⁵ and may occur with multifocal vasculopathy or myelitis.

Patients present with sudden painless loss of vision, floaters, and constricted visual fields due to retinal detachment. Unlike acute retinal necrosis, there is little or no inflammation in the anterior chamber or vitreous and no occlusive vasculitis. Multifocal, discrete opacified lesions begin in the outer retinal layers peripherally or the posterior pole or both; only late in the disease are inner retinal layers involved. Diffuse retinal hemorrhages and whitening with macular involvement bilaterally are characteristic findings (**FIGURE 4**).

VZV was shown to be the causative agent by the detection of VZV DNA, VZV antigen, and virus particles in aqueous and vitreous biopsy specimens⁷⁶ and in vitreous and retinal cultures,⁷⁷ as well as by histologic examination of necropsy specimens from eyes and brains combined with in situ hybridization.⁷⁸ Although VZV is the most common cause of progressive outer retinal necrosis, there have been rare reports of cytomegalovirus antigen and HSV 1 in the retina of patients with the condition,⁷⁹ as well as amplified cytomegalovirus DNA in the vitreous body.⁸⁰

Progressive outer retinal necrosis must be immediately recognized and treated because of its destructive nature and the high likelihood of retinal detachment. Unfortunately, multiple combinations of antiviral medications and other experimental treatments have not been widely successful. Intravenous acyclovir has given poor or inconsistent results,⁸¹ and even in cases in which acyclovir helped, VZV retinopathy recurred when the drug was tapered or stopped.

Patients treated with combined intravenous ganciclovir (Cytovene) and foscarnet or with ganciclovir alone had a better final visual acuity than those treated with acyclovir or foscarnet alone.⁸² In one instance, oral bromovinyl-deoxyuridine treatment was successful when acyclovir failed.⁸³ Aggressive combined antiviral treatment over a prolonged period with repair of retinal detachment may save a patient's vision. The best treatment for patients with AIDS may be prevention with highly active antiretroviral therapy, which appears to reduce the incidence of progressive outer retinal necrosis.⁸⁴

■ ZOSTER SINE HERPETE

The concept that zoster sine herpette (pain without rash) is due to reactivation of VZV was first supported by the description in zoster patients of dermatomal-distribution radicular pain in areas distinct from pain with rash.⁸⁵ Now that we recognize that zoster sine herpette exists, it has considerable implications for the diagnosis and treatment of patients with post-herpetic neuralgia, as VZV reactivation can produce various neurologic disorders without rash, all caused by the same pathogen.

The first verification of zoster sine herpette was in a physician who developed acute trigeminal-distribution pain without rash, associated with a fourfold rise in serum antibody specific to VZV.⁸⁶

Schott⁸⁷ described four patients who, years after trigeminal-distribution zoster, developed zoster sine herpette in the same distribution of the trigeminal nerve; unfortunately, none of these patients was studied virologically. Further virologic verification of zoster sine herpette came from PCR analysis of cerebrospinal fluid from two men with prolonged

thoracic-distribution radicular pain without rash. Amplifiable VZV DNA, but not HSV DNA, was found in their cerebrospinal fluid and blood mononuclear cells, and pain resolved after treatment with intravenous acyclovir.⁸⁸

In another virologically confirmed case, the patient had electromyographic fibrillation potentials restricted to chronically painful thoracic roots.⁸⁹ MRI of another patient with virologically verified active VZV infection revealed inflammation in ganglia and nerve roots corresponding to persistent pain.¹²

More than radicular pain

Further virologic analyses have revealed that the spectrum of zoster sine herpette is considerably larger than the classic presentation of radicular pain without rash. For example, there have been numerous reports of VZV-associated meningoencephalitis, vasculopathy, myelitis, cerebellar ataxia, and polyneuritis cranialis without rash.

Meningoencephalitis. Powell et al⁹⁰ described a patient with meningoencephalitis without rash whose cerebrospinal fluid contained VZV DNA. Mancardi et al⁹¹ described a patient with encephalomyelitis without rash, in whom anti-VZV antibody was found in the cerebrospinal fluid. Kleinschmidt-DeMasters et al⁹² described a patient with HIV with a fatal encephalomyelitis and necrotizing vasculitis without rash, pathologically verified to be caused by VZV.

Vasculopathy. Cases of unifocal and multifocal VZV vasculopathy without rash that resulted in stroke have been verified virologically.^{46,47} Gilden et al⁵⁹ described two patients with myelopathy that occurred without rash. One developed myelopathy 5 months after zoster rash, when amplifiable VZV DNA was detected in the cerebrospinal fluid. The other developed myelopathy while zoster was present; the myelopathy resolved, but recurred 6 months later without rash, when the cerebrospinal fluid contained VZV DNA and VZV antibody.

Cerebellar ataxia without rash may complicate childhood varicella.⁹³ Dangond et al⁹⁴ reported on a child who became ataxic 5 days before chickenpox developed. In addition, Ratzka et al⁹⁵ reported a case of cerebellar

The spectrum of zoster sine herpette is much larger than radicular pain

ataxia without rash in an adult in whom VZV DNA and VZV antibody were found in the cerebrospinal fluid.

Polyneuritis cranialis without rash due to VZV infection has also been described,⁹⁶ with involvement of cranial nerves IX, X, and XI, as well as upper cervical nerve roots. Anti-VZV antibodies were detected in the cerebrospinal fluid.

Ocular abnormalities. Several reports of ocular abnormalities associated with zoster sine herpette have emerged. Goon et al⁹⁷ reported a case of severe, unremitting eye pain: VZV DNA was found in nasal and conjunctival samples. There have also been cases of cranial nerve III palsies,⁹⁸ retinal periphlebitis,⁹⁹ uveitis,^{98,100} iridocyclitis,¹⁰¹ and disciform keratitis,¹⁰² all without rash and all confirmed virologically to be caused by VZV.

Unusual cases. A 77-year-old man with T-cell lymphoma with no history of zoster rash developed an acute fatal meningoradiculitis of cranial nerve roots and the cauda equina, which was pathologically and virologically confirmed to be caused by VZV.¹⁰³

In another case, an immunocompetent adult experienced relentless trigeminal-distribution pain for more than a year without a history of zoster rash; pathologic and virologic analysis of a trigeminal ganglionic mass confirmed chronic active VZV ganglionitis.¹⁰⁴

How common is VZV infection without rash?

It is difficult to estimate the clinical extent and prevalence of VZV without rash. Patients with prolonged radicular pain or other neurologic signs and symptoms should be tested for anti-VZV IgG antibody and VZV DNA (by PCR) in the cerebrospinal fluid, and for VZV DNA in blood mononuclear cells examined for VZV DNA.

WHICH PATIENTS NEED DIAGNOSTIC TESTING?

Although the diagnosis of zoster is usually made by observation alone, other neurologic complications of VZV reactivation such as myelitis, progressive outer retinal necrosis, vasculopathy, and zoster sine herpette usually require virologic confirmation, particularly when rash is absent.

Evidence of active VZV infection is supported by any of the following positive tests:

- Anti-VZV IgM in serum or cerebrospinal fluid
- Anti-VZV IgG in cerebrospinal fluid
- VZV DNA in blood mononuclear cells or cerebrospinal fluid.

Testing for anti-VZV IgG in the serum alone is useless because nearly all adults have it. In our experience, the most valuable tests are for VZV DNA and anti-VZV IgG in cerebrospinal fluid. Much less often, anti-VZV IgM is found in serum or cerebrospinal fluid, and even less often, VZV DNA is found in blood mononuclear cells during acute neurologic disease.

Some clinical hospital laboratories either test for anti-VZV IgG or send specimens to an outside laboratory. If a hospital cannot test for anti-VZV IgG or IgM, the referring physician should contact Dr. Donald Gilden (don.gilden@uchsc.edu) or Dr. Maria Nagel (maria.nagel@uchsc.edu), who will arrange to have the specimen tested at no cost to the patient. ■

Acknowledgments. The authors' work is supported in part by grants (AG06127 and NS32623 to Dr. Gilden) from the National Institutes of Health. We thank Marina Hoffman for editorial review and Cathy Allen for assistance in preparation of the manuscript.

REFERENCES

1. Harnisch JP. Zoster in the elderly: clinical, immunologic and therapeutic considerations. *J Am Geriatr Soc* 1984; 32:789–793.
2. Gilden DH, Cohrs RJ, Mahalingam R. Clinical and molecular pathogenesis of varicella virus infection. *Viral Immunol* 2003; 16:243–258.
3. Leppard B, Naburi AE. Herpes zoster: an early manifestation of HIV infection. *Afr Health* 1998; 21:5–6.
4. Kakourou T, Theodoridou M, Mostrou G, Syriopoulou V, Papadogeorgaki H, Constantopoulos A. Herpes zoster in children. *J Am Acad Dermatol* 1998; 39:207–210.
5. Gold E. Serologic and virus-isolation studies of patients with varicella or herpes-zoster infection. *N Engl J Med* 1966; 274:181–185.
6. Head H, Campbell AW, Kennedy PG. The pathology of herpes zoster and its bearing on sensory localisation. *Rev Med Virol* 1997; 7:131–143.
7. Denny-Brown D, Adams RD, Fitzgerald PJ. Pathologic features of herpes zoster: a note on "geniculate herpes." *Arch Neurol Psychiatry* 1944; 51:216–231.
8. Cheatham WJ, Dolan TF Jr, Dower JC, Weller TH. Varicella: report of two fatal cases with necropsy, virus isolation, and serologic studies. *Am J Pathol* 1956; 32:1015–1035.
9. Ghatak NR, Zimmerman HM. Spinal ganglion in herpes zoster. A light and electron microscopic study. *Arch Pathol* 1973; 95:411–415.
10. Esiri MM, Tomlinson AH. Herpes zoster. Demonstration of virus in trigeminal nerve and ganglion by immunofluorescence and electron microscopy. *J Neurol Sci* 1972; 15:35–48.

Testing for anti-VZV IgG in the serum alone is useless because nearly all adults have it

11. Nagashima K, Nakazawa M, Endo H. Pathology of the human spinal ganglia in varicella-zoster virus infection. *Acta Neuropathol (Berl)* 1975; 33:105–117.
12. Blumenthal DT, Salzman KL, Baringer JR, Forghani B, Gilden DH. MRI abnormalities in chronic active varicella zoster infection. *Neurology* 2004; 63:1538–1539.
13. Carroll WM, Mastaglia FL. Optic neuropathy and ophthalmoplegia in herpes zoster oticus. *Neurology* 1979; 29:726–729.
14. Meenken C, van den Horn GJ, de Smet MD, van der Meer JT. Optic neuritis heralding varicella zoster virus retinitis in a patient with acquired immunodeficiency syndrome. *Ann Neurol* 1998; 43:534–536.
15. Archambault P, Wise JS, Rosen J, Polomeno RC, Auger N. Herpes zoster ophthalmoplegia. Report of six cases. *J Clin Neuroophthalmol* 1988; 8:185–193.
16. Sodhi PK, Goel JL. Presentations of cranial nerve involvement in two patients with herpes zoster ophthalmicus. *J Commun Dis* 2001; 33:130–135.
17. Karmon Y, Gadoth N. Delayed oculomotor nerve palsy after bilateral cervical zoster in an immunocompetent patient. *Neurology* 2005; 65:170.
18. Manz HJ, Canter HG, Melton J. Trigeminal herpes zoster causing mandibular osteonecrosis and spontaneous tooth exfoliation. *South Med J* 1986; 79:1026–1028.
19. Garty BZ, Dinari G, Sarnat H, Cohen S, Nitzan M. Tooth exfoliation and osteonecrosis of the maxilla after trigeminal herpes zoster. *J Pediatr* 1985; 106:71–73.
20. Volvoikar P, Patil S, Dinkar A. Tooth exfoliation, osteonecrosis and neuralgia following herpes zoster of trigeminal nerve. *Indian J Dent Res* 2002; 13:11–14.
21. Sweeney CJ, Gilden DH. Ramsay Hunt syndrome. *J Neurol Neurosurg Psychiatry* 2001; 71:149–154.
22. Asnis DS, Micic L, Giaccio D. Ramsay Hunt syndrome presenting as a cranial polyneuropathy. *Cutis* 1996; 57:421–424.
23. Robillard RB, Hilsinger RL Jr, Adour KK. Ramsay Hunt facial paralysis: clinical analyses of 185 patients. *Otolaryngol Head Neck Surg* 1986; 95:292–297.
24. Furuta Y, Ohtani F, Aizawa H, Fukuda S, Kawabata H, Bergstrom I. Varicella-zoster virus reactivation is an important cause of acute peripheral facial paralysis in children. *Pediatr Infect Dis J* 2005; 24:97–101.
25. Merchut MP, Gruener G. Segmental zoster paresis of limbs. *Electromyogr Clin Neurophysiol* 1996; 36:369–375.
26. Yoleri O, Olmez N, Oztura I, Sengul I, Gunaydin R, Memis A. Segmental zoster paresis of the upper extremity: a case report. *Arch Phys Med Rehabil* 2005; 86:1492–1494.
27. Anderson JP, Keal EE. Cervical herpes zoster and diaphragmatic paralysis. *Br J Dis Chest* 1969; 63:222–226.
28. Tjandra J, Mansel RE. Segmental abdominal herpes zoster paresis. *Aust N Z J Surg* 1986; 56:807–808.
29. Murakami S, Hato N, Horiuchi J, Honda N, Gyo K, Yanagihara N. Treatment of Ramsay Hunt syndrome with acyclovir-prednisone: significance of early diagnosis and treatment. *Ann Neurol* 1997; 41:353–357.
30. Furuta Y, Ohtani F, Mesuda Y, Fukuda S, Inuyama Y. Early diagnosis of zoster sine herpette and antiviral therapy for the treatment of facial palsy. *Neurology* 2000; 55:708–710.
31. Rogers RS 3rd, Tindall JP. Herpes zoster in the elderly. *Postgrad Med* 1971; 50:153–157.
32. Vafai A, Wellish M, Gilden DH. Expression of varicella-zoster virus in blood mononuclear cells of patients with postherpetic neuralgia. *Proc Natl Acad Sci USA* 1988; 85:2767–2770.
33. Devlin ME, Gilden DH, Mahalingam R, Dueland AN, Cohrs R. Peripheral blood mononuclear cells of the elderly contain varicella-zoster virus DNA. *J Infect Dis* 1992; 165:619–622.
34. Mahalingam R, Wellish M, Brucklier J, Gilden DH. Persistence of varicella-zoster virus DNA in elderly patients with postherpetic neuralgia. *J Neurovirol* 1995; 1:130–133.
35. Terada K, Niiizuma T, Kawano S, Kataoka N, Akisada T, Orita Y. Detection of varicella-zoster virus DNA in peripheral mononuclear cells from patients with Ramsay Hunt syndrome or zoster sine herpette. *J Med Virol* 1998; 56:359–363.
36. Gilden DH, Cohrs RJ, Hayward AR, Wellish M, Mahalingam R. Chronic varicella-zoster virus ganglionitis—a possible cause of postherpetic neuralgia. *J Neurovirol* 2003; 9:404–407.
37. Quan D, Hammack BN, Kittelson J, Gilden DH. Improvement of postherpetic neuralgia after treatment with intravenous acyclovir followed by oral valacyclovir. *Arch Neurol* 2006; 63:940–942.
38. Rowbotham M, Harden N, Stacey B, Bernstein P, Magnus-Miller L. Gabapentin for the treatment of postherpetic neuralgia: a randomized controlled trial. *JAMA* 1998; 280:1837–1842.
39. Rice AS, Maton S; Postherpetic Neuralgia Study Group. Gabapentin in postherpetic neuralgia: a randomised, double blind, placebo controlled study. *Pain* 2001; 94:215–224.
40. Gilon I, Bailey JM, Tu D, Holden RR, Weaver DF, Houlden RL. Morphine, gabapentin, or their combination for neuropathic pain. *N Engl J Med* 2005; 352:1324–1334.
41. Dubinsky RM, Kabbani H, El-Chami Z, Boutwell C, Ali H; Quality Standards Subcommittee of the American Academy of Neurology. Practice parameter: treatment of postherpetic neuralgia: an evidence-based report of the Quality Standards Subcommittee of the American Academy of Neurology. *Neurology* 2004; 63:959–965.
42. Rowbotham MC, Manville NS, Ren J. Pilot tolerability and effectiveness study of levetiracetam for postherpetic neuralgia. *Neurology* 2003; 61:866–867.
43. Huff JC. Antiviral treatment in chickenpox and herpes zoster. *J Am Acad Dermatol* 1988; 18:204–206.
44. Beutner KR, Friedman DJ, Forszpaniak C, Andersen PL, Wood MJ. Valaciclovir compared with acyclovir for improved therapy for herpes zoster in immunocompetent adults. *Antimicrob Agents Chemother* 1995; 39:1546–1553.
45. Tying S, Barbarash RA, Nahlik JE, et al. Famciclovir for the treatment of acute herpes zoster: effects on acute disease and postherpetic neuralgia. A randomized, double-blind, placebo-controlled trial. Collaborative Famciclovir Herpes Zoster Study Group. *Ann Intern Med* 1995; 123:89–96.
46. Nau R, Lantsch M, Stiefel M, Polak T, Reiber H. Varicella zoster virus-associated focal vasculitis without herpes zoster: recovery after treatment with acyclovir. *Neurology* 1998; 51:914–915.
47. Gilden DH, Bennett JL, Kleinschmidt-DeMasters BK, Song DD, Yee AS, Steiner I. The value of cerebrospinal fluid antiviral antibody in the diagnosis of neurologic disease produced by varicella zoster virus. *J Neurol Sci* 1998; 159:140–144.
48. Gilden DH, Lipton JH, Wolf JS, et al. Two patients with unusual forms of varicella-zoster virus vasculopathy. *N Engl J Med* 2002; 347:1500–1503.
49. Fukumoto S, Kinjo M, Hokamura K, Tanaka K. Subarachnoid hemorrhage and granulomatous angiitis of the basilar artery: demonstration of the varicella-zoster-virus in the basilar artery lesions. *Stroke* 1986; 17:1024–1028.
50. O'Donohue JM, Enzmann DR. Mycotic aneurysm in angiitis associated with herpes zoster ophthalmicus. *AJNR Am J Neuroradiol* 1987; 8:615–619.
51. Burgoon MP, Hammack BN, Owens GP, Maybach AL, Eikelenboom MJ, Gilden DH. Oligoclonal immunoglobulins in cerebrospinal fluid during varicella zoster virus (VZV) vasculopathy are directed against VZV. *Ann Neurol* 2003; 54:459–463.
52. Gilden DH, Kleinschmidt-DeMasters BK, Wellish M, Hedley-Whyte ET, Rentier B, Mahalingam R. Varicella zoster virus, a cause of waxing and waning vasculitis: the New England Journal of Medicine case 5-1995 revisited. *Neurology* 1996; 47:1441–1446.
53. Nagel MA, Forghani B, Mahalingam R, et al. The value of detecting anti-VZV IgG antibody in CSF to diagnose VZV vasculopathy. *Neurology* 2007; 68:1069–1073.
54. Ryder JW, Croen K, Kleinschmidt-DeMasters BK, Ostrove JM, Straus SE, Cohn DL. Progressive encephalitis three months after resolution of cutaneous zoster in a patient with AIDS. *Ann Neurol* 1986; 19:182–188.
55. Aurelius E, Johansson B, Skoldenberg B, Staland A, Forsgren M. Rapid diagnosis of herpes simplex encephalitis by nested polymerase chain reaction assay of cerebrospinal fluid. *Lancet* 1991; 337:189–192.
56. Hilt DC, Buchholz D, Krumholz A, Weiss H, Wolinsky JS. Herpes zoster ophthalmicus and delayed contralateral hemiparesis caused by cerebral angiitis: diagnosis and management approaches. *Ann Neurol* 1983; 14:543–553.

57. Pina MA, Ara JR, Capablo JL, Omenaca M. Myelitis and optic neuritis caused by varicella [in Spanish]. *Rev Neurol* 1997; 25:1575–1576.
58. Celik Y, Tabak F, Mert A, Celik AD, Aktuglu Y. Transverse myelitis caused by varicella. *Clin Neurol Neurosurg* 2001; 103:260–261.
59. Gilden DH, Beinlich BR, Rubinstien EM, et al. Varicella-zoster virus myelitis: an expanding spectrum. *Neurology* 1994; 44:1818–1823.
60. Kleinschmidt-DeMasters BK, Gilden DH. Varicella-zoster virus infections of the nervous system: clinical and pathologic correlates. *Arch Pathol Lab Med* 2001; 125:770–780.
61. Devinsky O, Cho ES, Petito CK, Price RW. Herpes zoster myelitis. *Brain* 1991; 114:1181–1196.
62. de Silva SM, Mark AS, Gilden DH, et al. Zoster myelitis: improvement with antiviral therapy in two cases. *Neurology* 1996; 47:929–931.
63. Chua HC, Tjia H, Sitoh YY. Concurrent myelitis and Guillain-Barré syndrome after varicella infection. *Int J Clin Pract* 2001; 55:643–644.
64. Schvoerer E, Frechin V, Warter A, et al. Persistent multiple pulmonary nodules in a nonimmunocompromised woman after varicella-related myelitis treated with acyclovir. *J Clin Microbiol* 2003; 41:4904–4905.
65. Soushi S, Ozawa H, Matsushashi M, Shimazaki J, Saga U, Kurata T. Demonstration of varicella-zoster virus antigens in the vitreous aspirates of patients with acute retinal necrosis syndrome. *Ophthalmology* 1988; 95:1394–1398.
66. Thompson WS, Culbertson WW, Smiddy WE, Robertson JE, Rosenbaum JT. Acute retinal necrosis caused by reactivation of herpes simplex virus type 2. *Am J Ophthalmol* 1994; 118:205–211.
67. Tan JCH, Byles D, Stanford MR, Frith PA, Graham EM. Acute retinal necrosis in children caused by herpes simplex virus. *Retina* 2001; 21:344–347.
68. Holland GN. The progressive outer retinal necrosis syndrome. *Int Ophthalmol* 1994; 18:163–165.
69. Bonfili AA, Eller AW. Acute retinal necrosis. *Semin Ophthalmol* 2005; 20:155–160.
70. Savant V, Saeed T, Denniston A, Murray PI. Oral valganciclovir treatment of varicella zoster virus acute retinal necrosis. *Eye* 2004; 18:544–545.
71. Engstrom RE Jr, Holland GN, Margolis TP, et al. The progressive outer retinal necrosis syndrome. A variant of necrotizing herpetic retinopathy in patients with AIDS. *Ophthalmology* 1994; 101:1488–1502.
72. Guex-Crosier Y, Rochat C, Herbot CP. Necrotizing herpetic retinopathies. A spectrum of herpes virus-induced diseases determined by the immune state of the host. *Ocul Immunol Inflamm* 1997; 5:259–265.
73. Lewis JM, Nagae Y, Tano Y. Progressive outer retinal necrosis after bone marrow transplantation. *Am J Ophthalmol* 1996; 122:892–895.
74. Franco-Paredes C, Bellehumeur T, Merchant A, Sanghi P, DiazGranados C, Rimland D. Aseptic meningitis and optic neuritis preceding varicella-zoster progressive outer retinal necrosis in a patient with AIDS. *AIDS* 2002; 16:1045–1049.
75. Menerath JM, Gerard M, Laurichesse H, et al. Bilateral acute retinal necrosis in a patient with acquired immunodeficiency syndrome [in French]. *J Fr Ophtalmol* 1995; 18:625–633.
76. Tran TH, Rozenberg F, Cassoux N, Rao NA, LeHoang P, Bodaghi B. Polymerase chain reaction analysis of aqueous humour samples in necrotizing retinitis. *Br J Ophthalmol* 2003; 87:79–83.
77. Margolis TP, Lowder CY, Holland GN, et al. Varicella-zoster virus retinitis in patients with the acquired immunodeficiency syndrome. *Am J Ophthalmol* 1991; 112:119–131.
78. van den Horn GJ, Meenken C, Troost D. Association of progressive outer retinal necrosis and varicella zoster encephalitis in a patient with AIDS. *Br J Ophthalmol* 1996; 80:982–985.
79. Kashiwase M, Sata T, Yamauchi Y, et al. Progressive outer retinal necrosis caused by herpes simplex virus type 1 in a patient with acquired immunodeficiency syndrome. *Ophthalmology* 2000; 107:790–794.
80. Biswas J, Choudhry S, Priya K, Gopal L. Detection of cytomegalovirus from vitreous humor in a patient with progressive outer retinal necrosis. *Indian J Ophthalmol* 2002; 50:319–321.
81. Johnston WH, Holland GN, Engstrom RE Jr, Rimmer S. Recurrence of presumed varicella-zoster virus retinopathy in patients with acquired immunodeficiency syndrome. *Am J Ophthalmol* 1993; 116:42–50.
82. Moorthy RS, Weinberg DV, Teich SA, et al. Management of varicella zoster virus retinitis in AIDS. *Br J Ophthalmol* 1997; 81:189–194.
83. Dullaert H, Maudgal PC, Leys A, Dralands L, Clercq E. Bromovinyldeoxyuridine treatment of outer retinal necrosis due to varicella-zoster virus: a case-report. *Bull Soc Belge Ophtalmol* 1996; 262:107–113.
84. Austin RB. Progressive outer retinal necrosis syndrome: a comprehensive review of its clinical presentation, relationship to immune system status, and management. *Clin Eye Vis Care* 2000; 12:119–129.
85. Lewis GW. Zoster sine herpette. *Br Med J* 1958; 2:418–421.
86. Easton HG. Zoster sine herpette causing acute trigeminal neuralgia. *Lancet* 1970; 2:1065–1066.
87. Schott GD. Triggering of delayed-onset postherpetic neuralgia. *Lancet* 1998; 351:419–420.
88. Gilden DH, Wright RR, Schneck SA, Gwaltney JM Jr, Mahalingam R. Zoster sine herpette, a clinical variant. *Ann Neurol* 1994; 35:530–533.
89. Amlie-Lefond C, Mackin GA, Ferguson M, Wright RR, Mahalingam R, Gilden DH. Another case of virologically confirmed zoster sine herpette, with electrophysiologic correlation. *J Neurovirol* 1996; 2:136–138.
90. Powell KF, Wilson HG, Croxson MO, et al. Herpes zoster meningoencephalitis without rash: varicella zoster virus DNA in CSF. *J Neurol Neurosurg Psychiatry* 1995; 59:198–199.
91. Mancardi GL, Melioli G, Traverso F, Tabaton M, Farinelli M, Terragna A. Zoster sine herpette causing encephalomyelitis. *Ital J Neurol Sci* 1987; 8:67–70.
92. Kleinschmidt-DeMasters BK, Mahalingam R, Shimek C, et al. Profound cerebrospinal fluid pleocytosis and Froin's syndrome secondary to widespread necrotizing vasculitis in an HIV-positive patient with varicella zoster virus encephalomyelitis. *J Neurol Sci* 1998; 159:213–218.
93. Connolly AM, Dodson WE, Prensky AL, Rust RS. Course and outcome of acute cerebellar ataxia. *Ann Neurol* 1994; 35:673–679.
94. Dangond F, Engle E, Yessayan L, Sawyer MH. Pre-eruptive varicella cerebellitis confirmed by PCR. *Pediatr Neurol* 1993; 9:491–493.
95. Ratzka P, Schlachetzki JC, Bahr M, Nau R. Varicella zoster virus cerebellitis in a 66-year-old patient without herpes zoster. *Lancet* 2006; 367:182.
96. Funakawa I, Terao A, Koga M. A case of zoster sine herpette with involvement of the unilateral IX, X and XI cranial and upper cervical nerves [in Japanese]. *Rinsho Shinkeigaku* 1999; 39:958–960.
97. Goon P, Wright M, Fink C. Ophthalmic zoster sine herpette. *J R Soc Med* 2000; 93:191–192.
98. Hon C, Au WY, Cheng VC. Ophthalmic zoster sine herpette presenting as oculomotor palsy after marrow transplantation for acute myeloid leukemia. *Haematologica* 2005; 90(12 suppl):EIM04.
99. Noda Y, Nakazawa M, Takahashi D, Tsuruya T, Saito M, Sekine M. Retinal periphlebitis as zoster sine herpette. *Arch Ophthalmol* 2001; 119:1550–1552.
100. Akpek EK, Gottsch JD. Herpes zoster sine herpette presenting with hyphema. *Ocul Immunol Inflamm* 2000; 8:115–118.
101. Yamamoto S, Tada R, Shimomura Y, Pavan-Langston D, Dunkel EC, Tano Y. Detecting varicella-zoster virus DNA in iridocyclitis using polymerase chain reaction: a case of zoster sine herpette. *Arch Ophthalmol* 1995; 113:1358–1359.
102. Silverstein BE, Chandler D, Neger R, Margolis TP. Disciform keratitis: a case of herpes zoster sine herpette. *Am J Ophthalmol* 1997; 123:254–255.
103. Dueland AN, Devlin M, Martin JR, et al. Fatal varicella-zoster virus meningoradiculitis without skin involvement. *Ann Neurol* 1991; 29:569–572.
104. Hevner R, Vilela M, Rostomily R, et al. An unusual cause of trigeminal-distribution pain and tumour. *Lancet Neurol* 2003; 2:567–571.
105. Oxman MN, Levin MJ, Johnson GR, et al; Shingles Prevention Study Group. A vaccine to prevent herpes zoster and postherpetic neuralgia in older adults. *N Engl J Med* 2005; 352:2271–2284.
106. Donahue JG, Choo PW, Manson JE, Platt R. The incidence of herpes zoster. *Arch Intern Med* 1995; 155:1605–1609.
107. U.S. Census Bureau. U.S. Interim Projections by Age, Sex, Race, and Hispanic Origin. U.S. Census Bureau; 2004. <http://www.census.gov/ipc/www/usinterimproj>.

ADDRESS: Donald H. Gilden, MD, Department of Neurology, Mail Stop B182, University of Colorado Health Sciences Center, 4200 East 9th Avenue, Denver, CO 80262; e-mail don.gilden@uchsc.edu.