

DARLENE M. HOLDEN, MD
Department of Radiology, Cleveland ClinicDAVID M. EINSTEIN, MD
Department of Diagnostic Radiology, and
program director, Radiology Residency
Program, Cleveland Clinic

Imaging in Practice

Which imaging test for right lower quadrant pain?

A 36-YEAR-OLD WOMAN PRESENTS to the emergency department with abdominal pain and intermittent nausea. The pain began while she was at work and has been gradually worsening over the past 14 hours.

When it began, the pain centered around her navel, but it has since moved to the right lower quadrant. She has not had emesis or a change in bowel habits. She has no history of gastrointestinal problems, pelvic inflammatory disease, or surgery.

Her temperature is 38°C (100.4°F), and her vital signs are stable. On physical examination, she appears well developed and well nourished and has mild discomfort related to lower abdominal pain. Her abdomen is soft and nondistended but focally tender in the right lower quadrant, without rebound pain. The gynecologic examination is normal. Bowel sounds are diminished.

Her white blood cell count is $11.6 \times 10^9/L$ (normal range 4.0–11.0), her qualitative urine human chorionic gonadotropin test is negative, and all other studies are within normal limits.

You suspect that she has acute appendicitis. Which imaging test should be ordered to further evaluate this patient?

■ APPENDICITIS CAN BE CHALLENGING TO DIAGNOSE

If this patient has acute appendicitis, the longer surgery is delayed, the greater the risk of the appendix perforating, which would increase the risk of postoperative complications and prolong her hospital stay. On the other hand, if she does not have appendicitis, a potentially unnecessary surgery could be prevented.

The incidence of appendicitis in the United States (all age groups) is approximately 1 person out of 1,000 per year, making it one of the most common reasons for surgery for the chief complaint of abdominal pain evaluated in the emergency department.¹ The classic presenting symptoms of acute appendicitis are well described, which in theory should lead to rapid and accurate diagnosis. Yet the diagnosis can be challenging: as many as one third of patients have an atypical presentation, and the classic symptoms can be mimicked by those of other gastrointestinal, genitourinary, and gynecologic conditions.²

Because of these factors, the accuracy of diagnosing acute appendicitis based on the history and physical examination is only 70% to 84% in the general population, and only 60% to 68% in women of childbearing age.³ As a result, rates of “negative” (ie, unnecessary) laparotomy have ranged from 8% to 30%, and the rate generally accepted in the surgical literature is approximately 20%.²

Current imaging techniques can increase the diagnostic accuracy and lower the rates of unnecessary laparotomy for suspected appendicitis.

■ IMAGING HELPS FIND, RULE OUT OTHER CAUSES

Conditions with symptoms that can mimic those of appendicitis include Crohn disease, right-sided diverticulitis, mesenteric adenitis, epiploic appendagitis, right colonic neoplasm, infectious colitis, bowel ischemia, acute pyelonephritis, ureteral calculus, pelvic inflammatory disease, and hemorrhagic ovarian cyst.

**Acute
appendicitis
presents
atypically
in up to 1/3
of cases**

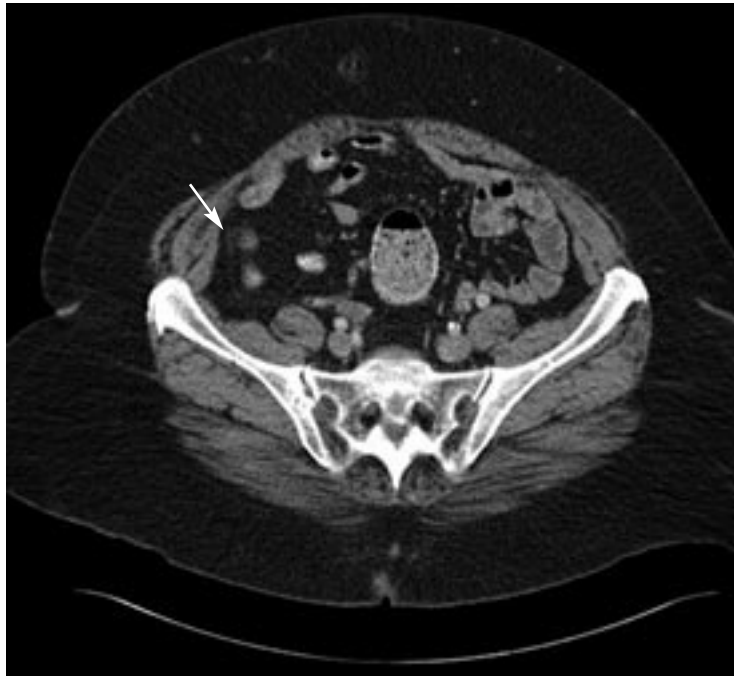


FIGURE 1. Normal appendix (arrow) on CT with contrast.

**Early diagnosis
of appendicitis
is the key
to preventing
perforation**

Computed tomography (CT) and ultrasonography can help differentiate appendicitis from these other conditions and provide valuable information for the medical and surgical management of the patient.⁵

Little or no role for plain films

Plain-film radiography of the abdomen rarely provides useful information in these cases and plays little or no role in directing immediate therapy. A recent study of 871 patients with abdominal pain showed that this examination had a 0% sensitivity for appendicitis, pyelonephritis, pancreatitis, and diverticulitis.⁶

**Ultrasonography may be helpful
in women and children**

Graded-compression ultrasonography is helpful in evaluating thin young children and obstetric patients. This technique involves slowly compressing the right lower abdomen starting in the region of maximum tenderness and using a linear-array transducer of greater than 7 MHz. It may also aid the diagnosis if it is the only imaging test available and a gynecologic condition is the suspected cause of the lower abdominal pain.

Ultrasonography is noninvasive, rapid,

and relatively inexpensive. It requires no patient preparation and uses no ionizing radiation. Its sensitivity and specificity can vary, however, depending on the skill of the examiner and the body habitus of the patient. Its sensitivity in children ranges from 44% to 94% and its specificity ranges from 47% to 95%.² Even in the ideal patient, overlying bowel gas can technically limit the ability of ultrasonography to identify a normal or perforated appendix—and if it cannot definitely show that the appendix is normal, the examination is inconclusive. In this situation, CT can be used for further evaluation.

CT is the test of choice

CT is the imaging test of choice for suspected appendicitis in adults who are not pregnant. It is rapid and has positive predictive values of 92% to 98%, negative predictive values of 95% to 100%, and a high accuracy rate of 94% to 98%.² CT can also detect complications of acute appendicitis and reveal alternative diagnoses.

Since CT uses ionizing radiation, it is relatively contraindicated in obstetric patients and should be used judiciously in young adults and children.

The protocol used varies from institution to institution, with variable use of oral, rectal, and intravenous (IV) contrast material. Most institutions use the triple-contrast technique. But regardless of the technique, high rates of accuracy are uniformly reported.

CT without contrast is used at some institutions to eliminate delay related to the administration of enteric contrast and to avoid the risks associated with the IV injection of contrast. The sensitivity with this approach ranges from 84% to 96%, and the specificity ranges from 92% to 98%.²

The drawback of this technique is a lower sensitivity in thinner patients with little intra-abdominal fat and in patients with early or mild appendicitis. Also, it has limited ability to show inflammatory or neoplastic processes.

Focused CT. Some experts advocate imaging only the lower abdomen and pelvis to minimize the radiation dose to the patient; however, this approach risks missing abnormalities that lie outside the imaging field that may require surgery.⁷ Therefore, we do not recommend focused CT for the evaluation of

suspected appendicitis, and we do not utilize this protocol at our institution.

CT with IV contrast facilitates recognition of appendicitis, especially in subtle cases and in thin patients with little intra-abdominal fat. This approach is also better at characterizing complications of perforation such as abscess formation and phlegmon, as well as other pathologic entities that may cause abdominal pain.

CT with enteric contrast. Oral contrast is given 1.5 to 2 hours before the examination to opacify and distend the distal small bowel and cecum. Adequate visualization of anatomic landmarks helps in identifying the appendix, and opacification of adjacent bowel loops is important because they can otherwise mimic or obscure an abnormal appendix.

If opacification of the terminal ileum is delayed, whether due to patient compliance issues (eg, patient is unable to take all the contrast material) or to slower gastrointestinal transit time, contrast can be given rectally. Rectal contrast is used for cecal opacification and distention, allowing better depiction of relevant appendiceal and cecal changes. Rectal contrast is contraindicated in neutropenic patients.

■ OUR DIAGNOSTIC APPROACH

At Cleveland Clinic, we use CT of the abdomen and pelvis with IV, oral, and rectal contrast for nonpregnant adult patients with suspected appendicitis. This provides the highest sensitivity and specificity for the diagnosis of acute appendicitis, and also allows the diagnosis of other acute conditions that may mimic appendicitis.

For pediatric patients, we tailor the approach to the patient and the clinical presentation. We use ultrasonography in obstetric patients.

■ WHAT CAN CT SHOW?

Normal appendix

The normal appendix (**FIGURE 1**) is a thin-walled tubular structure that arises from the posteromedial aspect of the cecum 2 to 3 cm caudal to the ileocecal valve. The appendix varies in length from 2 to 20 cm, is surrounded by mesenteric fat, and usually does not

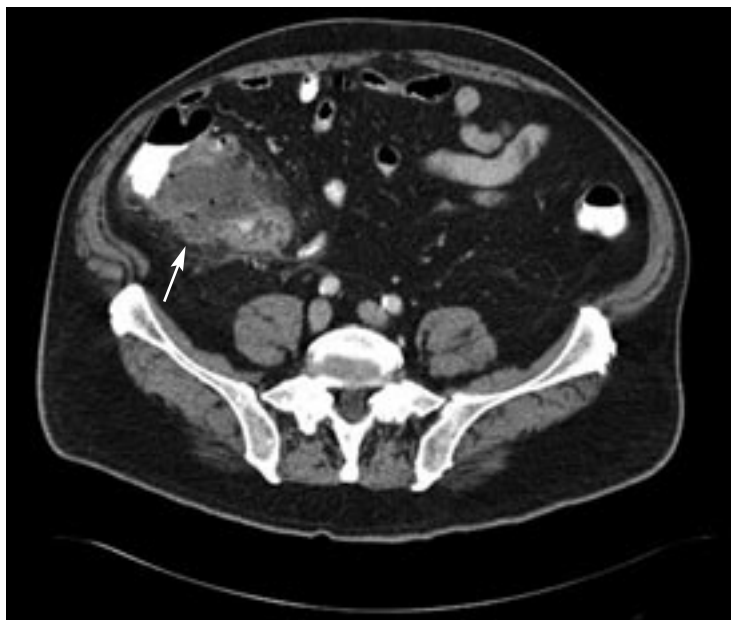


FIGURE 2. This CT image from a patient with pathologically proven perforated appendicitis shows inflammatory stranding with associated fluid, gas, and a small amount of extravasated contrast adjacent to the cecum (arrow). It also shows thickening of the cecum adjacent to the perforation.

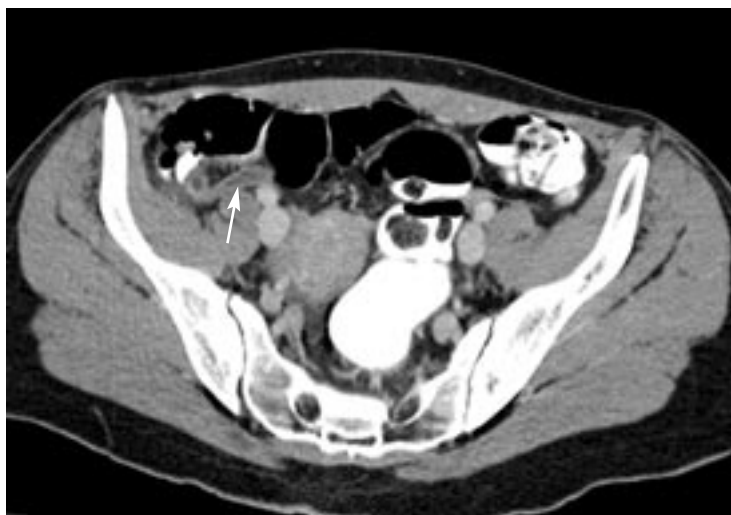

FIGURE 3. Classic image of acute appendicitis (arrow) on CT in our patient.

exceed 6 mm in diameter. The appendix is mobile, having its own mesentery, and its position relative to the cecum can vary.

Acute appendicitis

On CT, the classic signs of acute appendicitis are an appendix that is fluid-filled and dilated (transverse diameter > 6 mm), with a thick-



ened enhancing wall and surrounding periappendiceal inflammatory stranding. The finding of an appendicolith with adjacent stranding is likewise diagnostic. The entire appendix must be evaluated because in some cases inflammatory change can be confined only to the distal portion of the appendix.

A secondary finding that aids in the diagnosis is focal thickening at the tip of the cecum. Periappendiceal inflammatory changes such as fluid collections or stranding without visualization of the appendix or an appendicolith are suspicious but are not diagnostic for acute appendicitis, as they can be caused by other inflammatory conditions in the pelvis, including cecal diverticulitis, perforated cecal carcinoma, Crohn disease, and typhlitis (cecal inflammation).

If a large periappendiceal abscess is present, as in perforated appendicitis (**FIGURE 2**), the surgeon may request drainage of the abscess with CT guidance, either as a temporizing measure to be followed by elective surgery, or as definitive therapy.

An axial image from contrast-enhanced CT of the abdomen and pelvis performed on our patient (**FIGURE 3**) shows the classic signs of acute appendicitis. The appendix is dilated

and fluid-filled, with an enhancing wall and surrounding inflammatory stranding. She underwent surgery, had pathologically proven acute appendicitis, and recovered quickly without complications.

■ TAKE-HOME POINTS

Right lower quadrant pain is a nonspecific but common complaint seen in clinical practice and is also one of the more challenging presentations to accurately assess. CT has become the most reliable imaging method for further evaluation and is the imaging test of choice in nonpregnant adult patients.

Although controversy exists regarding the use of intravenous and enteric contrast, we prefer to use oral, rectal, and intravenous contrast, which we find provides the most complete evaluation of the right lower quadrant and allows detection of other conditions.

Early diagnosis of appendicitis with prompt surgical intervention is the key to preventing complications such as perforation and abscess formation. CT can reliably diagnose appendicitis by recognizing abnormalities in the appendix and inflammatory changes around the appendix.



We prefer CT with oral, rectal, and IV contrast to evaluate for acute appendicitis

■ REFERENCES

1. Marshall MT, Rosen P, Berlin R. Appendicitis masquerading as tumor: a case of two diagnoses. *J Emerg Med* 2001; 21:397–399.
2. Leite NP, Pereira JM, Rui C. CT evaluation of appendicitis and its complications: imaging techniques and key diagnostic findings. *AJR Am J Roentgenol* 2005; 185:406–416.
3. Nikolaidis P, Hwang C, Miller F. The nonvisualized appendix: incidence of acute appendicitis when secondary inflammatory changes are absent. *AJR Am J Roentgenol* 2004; 183:889–892.
4. Birnbaum BA, Wilson SR. Appendicitis at the millennium. *Radiology* 2000; 215:337–348.
5. Yu Jinxing, Fulcher AS, Turner MA. Helical CT evaluation of acute right lower quadrant pain: part 1, common mimics of appendicitis. *AJR Am J Roentgenol* 2005; 184:1136–1142.
6. Macari M, Balthazar EJ. The acute right lower quadrant: CT evaluation. *Radiol Clin North Am* 2003; 41:1117–1136.
7. Jacobs JE, Birnbaum BA, Macari M. Acute appendicitis: comparison of helical CT diagnosis-focused technique with oral contrast material versus nonfocused technique with oral and intravenous contrast material. *Radiology* 2001; 220:683–690.

ADDRESS: David M. Einstein, MD, Department of Diagnostic Radiology, Hb6, Cleveland Clinic, 9500 Euclid Avenue, Cleveland, OH 44195; e-mail einsted@ccf.org.