



The Clinical Picture

An ectopic peripherally inserted central catheter ('ectoPICC')

A 57-YEAR-OLD WOMAN underwent placement of a peripherally inserted central catheter (PICC) to receive treatment for *Providencia stuartii* bacteremia complicating a leg wound infection. Seven days later, the line was disrupted during routine care at the nursing home where she resided. A chest radiograph was obtained (FIGURE 1), which showed the PICC to have fractured and embolized to the left pulmonary artery. The patient had no symptoms.

The ectopic PICC (which we have dubbed an "ectoPICC") was retrieved percutaneously. FIGURE 2 shows the ectoPICC on fluoroscopy before being removed, and FIGURE 3 shows it being snared and withdrawn. The procedure was clinically uneventful.

DISCUSSION

Central venous catheters of all types are commonly used in clinical practice, and knowledge of potential complications and their management is of paramount importance. Extraction of fractured catheters and their fragments should be done as soon as possible to avert life-threatening complications.

PICCs have been used in clinical practice since 1982 in situations in which long-term circulatory access is needed (eg, for chemotherapy or total parenteral nutrition). They are relatively simple to insert, and the procedure is associated with few complications, the most frequent being pneumothorax (2%–6%), infection (2%–16%), thrombosis (2%–16%), catheter occlusion (2%), and leakage (1%–6%).

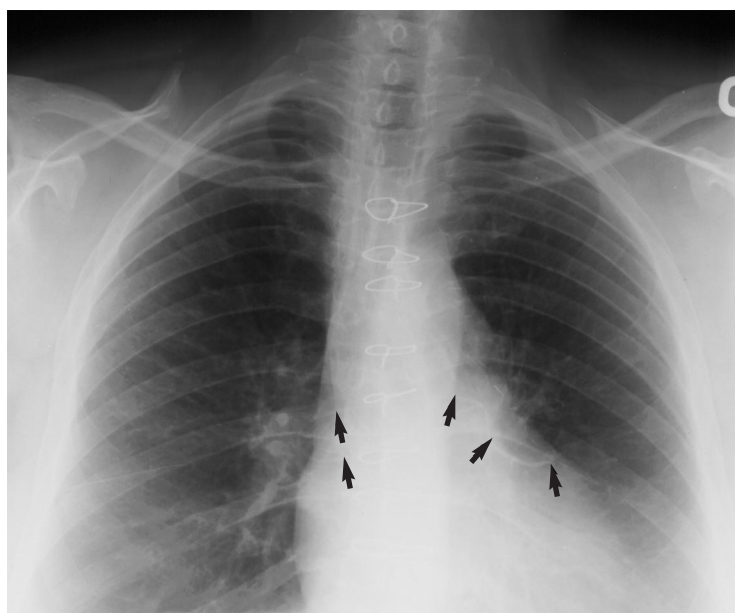


FIGURE 1. Plain chest radiograph, showing the fractured peripherally inserted central catheter (PICC) lodged in the left pulmonary artery (arrows).

PICC fractures have been reported, but they are uncommon. We are aware of 22 cases of fractured PICCs in seven reports, with a frequency estimate of 11 cases in 1,650 placements in one series. Suggested measures to avoid this type of complication are to use careful insertion technique, to obtain a post-procedure radiograph to check for positioning and coiling, and to properly train the inserting operators and physicians and nurses providing ongoing catheter care.

Embolization of a catheter fragment to the heart, pulmonary arteries, or systemic circulation (the latter through existing anatom-

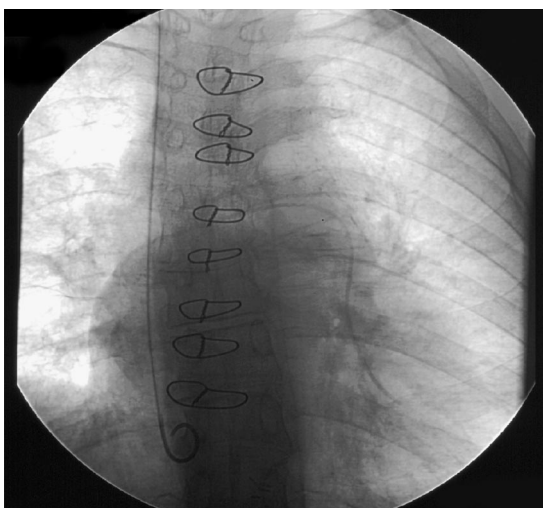


FIGURE 2. Fluoroscopic image before the fragment was extracted.

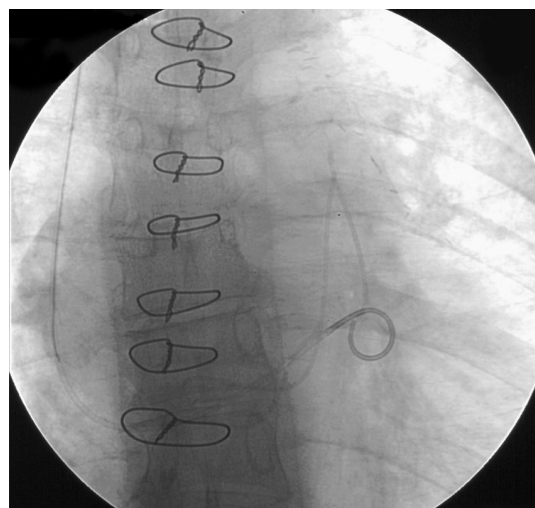


FIGURE 3. Extraction of the fragment.

A fractured central line should be extracted immediately

ic intracardiac or extracardiac shunts) is a serious complication that can cause cardiac dysrhythmias, tamponade, myocardial injury, endocarditis, bloodstream infection, valve perforation, pulmonary or systemic thrombosis, septic emboli with secondary infarcts, and even death.

To diagnose an ectoPICC, chest radiography or direct fluoroscopy can illustrate the broken and embolized fragment (with evident loss of continuity of the catheter) or the more subtle “pinched-off sign,” ie, a narrowing of the catheter at the site of an incomplete fracture. The latter situation poses an approximately 40% risk of subsequent complete fracture. If either of these signs is seen, the device

or the fragment or both should be extracted immediately to avoid immediate complications or long-term complications related to migration of the fractured catheter or foreign body infection.

An experienced radiologist may be able to retrieve the ectoPICC percutaneously using a variety of instruments such as loop snares, Dormia baskets, hooked guidewires (pig-tail catheters), grasping forceps, and Fogarty balloon-tip catheters. If the device cannot be retrieved percutaneously, surgical extraction may be needed. Some advocate pre-extraction angiography to exclude a coexistent thrombus that may predispose to pulmonary embolism.

SUGGESTED READING

- Bessoud B, de Baere T, Kuoch V, et al. Experience at a single institution with endovascular treatment of mechanical complications caused by implanted central venous access devices in pediatric and adult patients. *AJR Am J Roentgenol* 2003; 180:527–532.
- Chow L, Friedman J, MacArthur C, Restrepo R, Temple M, Chait PG, Connolly B. Peripherally inserted central catheter (PICC) fracture and embolization in the pediatric population. *J Pediatr* 2003; 142:141–144.
- Coles CE, Whitear NP, LeVay JH. Spontaneous fracture and embolization of a central venous catheter: prevention and early detection. *Clin Oncol* 1998; 10:412–414.
- Debets JMH, Wils JAMJ, Schlagen JT. A rare complication of implanted central venous devices: catheter fracture and embolization. *Support Care Cancer* 1995; 3:432–434.
- DeGeare VS, Safian RD. Percutaneous retrieval of a large peripherally inserted central catheter remnant from the pulmonary arteries. *Clin Cardiol* 2001; 24:89.
- Di Carlo I, Fischella P, Russello D, Puleo S, Latteri F. Catheter fracture and cardiac migration: a rare complication of totally implantable venous devices. *J Surg Oncol* 2000; 73:172–173.
- Ingle RJ. Rare complications of vascular access devices. *Semin Oncol Nurs* 1995; 11:184–193.
- Kossoff EH, Poirier MP. Peripherally inserted central venous catheter fracture and embolization to the lung. *Pediatr Emerg Care* 1998; 14:403–405.
- Linz DN, Bissett GS, Warner BW. Fracture and embolization of a peripherally inserted central venous catheter. *J Parenteral Enteral Nutr* 1994; 18:79–80.
- Liu JC, Tseng HS, Chen CY, Chern MS, Chang CY. Percutaneous retrieval of 20 centrally dislodged Port-A catheter fragments. *Clin Imaging* 2004; 28:223–229.
- Petit J. Assessment of infants with peripherally inserted central catheters: part 1. Detecting the most frequently occurring complications. *Adv Neonatal Care* 2002; 6:304–315.
- Thanigaraj S, Paneerselvam A, Yanos J. Retrieval of an IV catheter fragment from the pulmonary artery 11 years after embolization. *Chest* 2000; 117:1209–1211.

ADDRESS: Octavian C. Ioachimescu, MD, Department of Pulmonary, Allergy, and Critical Care Medicine, A90, Cleveland Clinic, 9500 Euclid Avenue, Cleveland, OH 44195; e-mail oioac@yahoo.com.