

JOHN A. DUMOT, DODepartment of Gastroenterology and Hepatology,
Cleveland Clinic

ERCP: Current uses and less-invasive options

■ ABSTRACT

Endoscopic retrograde cholangiopancreatography (ERCP) is well suited for the evaluation and treatment of diseases of the bile ducts and pancreas, but it carries the risk of inducing pancreatitis. Magnetic resonance cholangiopancreatography (MRCP) and endoscopic ultrasonography have exceptional value in imaging the gallbladder, common hepatic duct, common bile duct, and pancreas. These imaging studies have replaced ERCP for diagnostic purposes in patients with a low pretest probability of finding lesions amenable to endoscopic therapy, such as bile duct stones.

■ KEY POINTS

ERCP carries a 5% to 7% risk of pancreatitis depending on the patient, the procedure, and operator expertise. Other complications such as bleeding, cholangitis, cholecystitis, cardiopulmonary events, perforation, and death occur far less often.

ERCP is the treatment of choice for bile duct stones and for the immediate relief of extrahepatic biliary obstruction in benign disease. Long-term patency of biliary stents remains a challenge in patients with malignant disease.

In patients with unresectable pancreatic and bile duct tumors, endoscopic placement of a bile duct stent is the treatment of choice for palliation of malignant distal bile duct strictures.

ENDOSCOPIC RETROGRADE cholangiopancreatography (ERCP) is a valuable intervention for patients with known or suspected bile duct stones, bile duct trauma resulting in bile leaks or strictures, and benign or malignant obstruction of the bile duct.

While the complication rate of ERCP is acceptable when compared with other invasive procedures such as biliary bypass surgery or open bile duct exploration, the rate is too high for patients with a low pretest probability of disease if the procedure is to be done purely diagnostically.

Fortunately, newer techniques such as magnetic resonance cholangiopancreatography (MRCP) now offer a noninvasive alternative in the diagnosis of these conditions in many patients.

In this article, we discuss the current indications for ERCP, its potential complications, and alternatives.

■ THE CHALLENGES OF ERCP

ERCP is one of the most technically challenging endoscopic procedures performed by gastroenterologists and surgeons with special training. It is well suited for the evaluation of diseases of the bile ducts and pancreas. In spite of technological advances in ERCP, the rate of complications due to the procedure continues to be relatively high, with pancreatitis and bleeding the most common.

Unfortunately, pancreatitis occurs in 5% to 7% of procedures in spite of numerous efforts to reduce this dreaded complication.¹⁻⁴ Death directly related to the procedure occurs in about 0.4% of cases in large prospective studies.^{3,4}

Patients must be well informed about ERCP and its complications as part of the informed-consent process before the procedure is scheduled.

■ CURRENT INDICATIONS FOR ERCP

In 2002, a National Institutes of Health (NIH) consensus panel made recommendations based on evidence in the medical literature.⁵ These are available at consensus.nih.gov/2002/2002ERCPSos020html.htm.

The panel recommended ERCP for gallstones, biliary obstruction due to cancer, acute and recurrent pancreatitis, pancreatic pseudocyst, and suspected sphincter of Oddi dysfunction. In general, the panel concluded that ERCP carries an acceptable risk for patients who face open procedures that carry a greater morbidity and death, and recommended ERCP over open surgery for common bile duct exploration for the removal of stones or biliary bypass for malignant obstruction of the bile duct.

Among the panel's conclusions:

- Patients with a low pretest probability of having a treatable lesion are at the highest risk for complications related to ERCP.
- Patients should undergo ERCP in a setting that allows for therapeutic interventions during the same procedure.
- Centers that perform a significant volume of ERCP have higher completion rates and lower complication rates.

■ ERCP VS NONINVASIVE IMAGING

Advances in noninvasive imaging have reduced the overall number of diagnostic ERCP procedures. MRCP can produce images remarkably similar to those of ERCP and can help in the selection of patients for more-invasive procedures.

Endoscopic ultrasonography combines the findings of conventional endoscopy with the ability of ultrasound to examine structures adjacent to the stomach and duodenum. The common bile duct and pancreatic duct are readily visualized through the gastric and duodenal walls without interference from subcutaneous fat or bowel gas. The extrahepatic bile duct can be seen coursing from the bifurcation at the hilum through the pancreatic head to the level

of the ampulla with a resolution of less than 1 mm at a frequency of 5, 7, and 12 mHz.

Endoscopic ultrasonography requires sedation similar to that used for ERCP, ie, moderate to deep sedation with analgesics and sedatives, all of which can be performed on an outpatient basis. Patients who may require general anesthesia include those with narcotic tolerance, unstable cardiopulmonary function, or airway problems, and children.

Patients undergoing ERCP need to be informed that they may have to stay overnight for observation if symptoms develop after the procedure or if it is merited due to the inherent risks associated with the therapeutic intervention used.

ERCP is generally safe, even in patients age 90 or older.^{6,7}

■ CHALLENGES THAT RAISE THE RISK OF COMPLICATIONS

The need for cannulation

Although sedation-related problems can occur, complications of ERCP are usually due to cannulation—ie, use of a guide wire or catheter to obtain deep access to the bile duct or pancreatic duct, which is the primary goal in therapeutic ERCP procedures.

Reaching the biliary and pancreatic orifice at the ampulla (major papilla) in the second portion of the duodenum can be difficult, as patients may have altered anatomy due to previous surgery (eg, Billroth II partial gastrectomy, Roux-en-Y anastomosis), or benign or malignant strictures in the esophagus, pylorus, or duodenum. In addition, perampullary duodenal diverticuli can obscure the ampulla, making it difficult to visualize with the endoscope. Access into the desired duct can be difficult due to anatomical variations in the union of the biliary and pancreatic ducts (FIGURE 1), or to an impacted gallstone at the ampulla, and about 5% of procedures are stopped after unsuccessful attempts to gain access.^{4,8}

Sphincterotomy

Freehand needle-knife or “precut” sphincterotomy involves making an incision into the overlying mucosa with an electrified light-gauge wire to unroof the desired orifice so that the ductal epithelium can be visualized. Precut

ERCP centers with high volumes have higher completion rates, lower complication rates

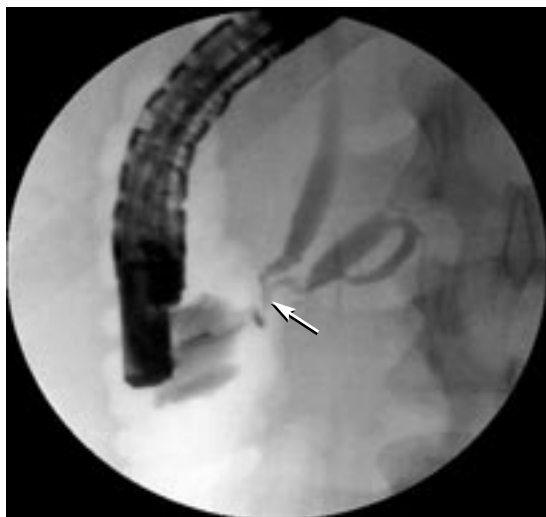

FIGURE 1. A long common channel in the intraduodenal segment of the biliary and pancreatic ducts (arrow).

sphincterotomy is associated with an increased risk of pancreatitis, bleeding, and perforation.

The need for more aggressive measures

In very difficult cases, percutaneous transhepatic external biliary access, laparoscopy, or endoscopic ultrasonography can be a means of guide-wire placement for a rendezvous with the endoscope in the duodenum.⁸

The physician performing the procedure must make decisions during the procedure that balance the risk of more-aggressive interventions to achieve cannulation against the outcome of a failed ERCP.

■ PREVENTION OF ERCP-INDUCED PANCREATITIS

Recent studies show that ERCP-induced pancreatitis occurs in 5% to 7% of cases. The exact mechanism for this remains unknown. However, risk factors include excessive manipulation of the ampulla, as in difficult cannulation, and biliary or pancreatic sphincterotomy.

More experience, higher volume are keys to success

Other factors influencing the complication rate are the experience of the endoscopist and the volume of cases performed at the institu-

tion.^{3,4} An Italian study found striking differences in rates of major complications at small-volume vs large-volume centers: major complication rates of 7.1% vs 2.0%, $P < .0001$, and death rates of 0.75% vs 0.18%, $P < .05$.⁴ Overall, the highest rates of pancreatitis occur in young healthy women with normal bilirubin levels and biliary-type pain suggestive of sphincter dysfunction.

Targeting inflammation

In acute pancreatitis, abrupt rises in inflammatory mediators such as cytokines, prostaglandins, leukotrienes, and platelet-activating factor have been observed,^{9,10} leading to the question of whether blocking the inflammatory cascade may prevent or lessen the complications of ERCP-induced pancreatitis.

Agents studied for this purpose include diclofenac suppositories,¹¹ nitrates,¹² allopurinol,¹³ and ulinastatin (a protease inhibitor that may be effective in acute pancreatitis).¹⁴ Initial results with the anti-inflammatory cytokine interleukin 10 were promising in animal studies^{15,16} and human trials,¹⁷ but others failed to find a consistent treatment effect.¹⁸ Corticosteroids to prevent reactions to injected contrast material were reported to have a benefit in a retrospective analysis,¹⁹ but prospective controlled trials later showed no benefit.^{20,21}

Gabexate is a protease inhibitor shown to reduce ERCP-induced pancreatitis if infused intravenously for at least 13 hours beginning 30 to 90 minutes before the procedure.²² Gabexate is not available in the United States, and the long infusion time has limited the enthusiasm for this treatment. In a recent multicenter Italian study, a 6.5-hour infusion was compared with the 13-hour infusion, with rates of pancreatitis of 2.2% and 1.4%, respectively.²³ The differences were not statistically significant, and both study groups had an exceedingly low rate of ERCP-induced pancreatitis. Gabexate is also expensive because it must be given by infusion.

Temporary stenting

Ensuring pancreatic duct drainage by placing a temporary stent across the pancreatic orifice seems to be a solution to the swelling and temporary obstruction to pancreatic juice flow

ERCP-induced pancreatitis occurs in 5% - 7% of cases

caused by manipulation of the ampulla.²⁴ In a randomized controlled trial of 76 high-risk patients, the incidence of pancreatitis in the control and stent groups was 28% and 5%, respectively.²⁵

This intervention has been studied in only a limited group of patients undergoing high-risk procedures such as pancreatic duct sphincterotomy and difficult cannulation of the bile duct. Placement of a temporary small-caliber pancreatic stent usually entails additional manipulation of the pancreatic orifice and ductal system. Therefore, experts do not recommend widespread adoption of this technique.

Some pancreatic stents are designed to dislodge spontaneously, but many still require a second endoscopic procedure for their removal. In our experience, the reliability of the stent dislodging spontaneously is too low to justify a wait-and-see approach because pancreatic stent placement has been known to induce strictures. Therefore, in our practice we schedule a follow-up endoscopic procedure to ensure that the temporary stent is removed.

■ ALTERNATIVES TO ERCP TO DIAGNOSE BILIARY OR PANCREATIC PAIN

The only foolproof way to prevent complications of ERCP is to not perform the procedure. Noninvasive imaging is now used in most situations in which ERCP was used diagnostically to “rule in” or exclude life-threatening conditions.

Since the inception of MRCP in 1992, advances have made this an excellent tool in patients with suspected biliary or pancreatic disease. MRCP images the fluid in the bile and pancreatic ducts with a high signal intensity compared to the solid or fast-flowing fluid in blood vessels. Software, hardware, and expertise in MRCP interpretation are now more widely available.

MRCP can be very useful in patients who have pain and other subjective symptoms but no objective abnormalities in liver tests or on routine imaging studies. Computed tomography (CT) and ultrasonography may suggest bile duct dilation without an obvious cause, but these findings do not confirm a stone or obstruction. Current MRCP technology, on the other hand, provides images with a strik-

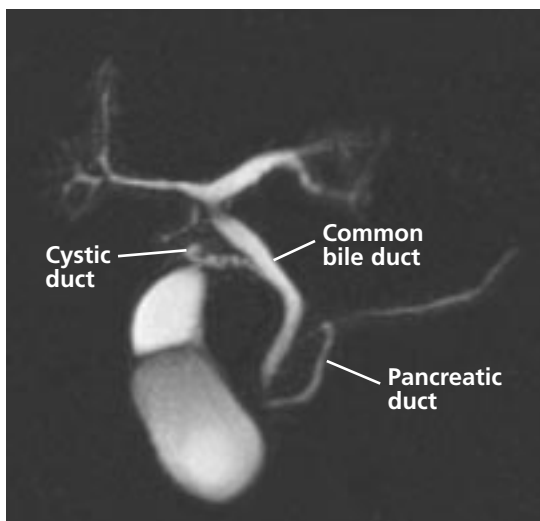


FIGURE 2. Magnetic resonance image of the normal anatomy. This technique provides anatomic detail similar to that of ERCP, but does it noninvasively.

PHOTO COURTESY OF JOSEPH VENIERO, MD, PhD

ing resemblance to those of ERCP fluoroscopy (FIGURE 2) and can exclude a variety of problems. Patients with a low pretest probability of having biliary or pancreatic obstruction and a normal study can be reassured, and no further testing is needed.

A meta-analysis of 67 prospective trials with a total of 4,711 patients undergoing MRCP compared the results to a gold standard such as ERCP, intra-operative cholangiography, or operative findings.²⁶ For example, a patient with right upper-quadrant pain after cholecystectomy may have bile duct dilation, but CT or ultrasonography may not be able to clearly show a common bile duct stone or mass. MRCP can detect a retained stone with a sensitivity of 92% (80–97% ± 1.96 SD) and a specificity of 97% (90–99% ± 1.96 SD).²⁶

Endoscopic ultrasonography is superior to both MRCP and ERCP when a neoplasm of the ampulla or pancreas is suspected.^{27–31}

Which procedure is best for diagnosis of sphincter dysfunction?

ERCP has been suggested as the study of choice for patients with ampullary stenosis or sphincter of Oddi dysfunction, but its use remains controversial in patients without objective laboratory findings because of the lack of long-term studies.³²

The only way to prevent complications of ERCP is to not perform the procedure

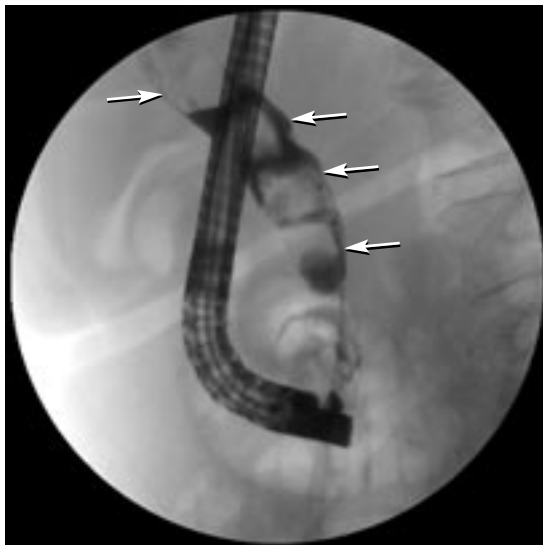


FIGURE 3. Fluoroscopic view during ERCP, with four large stones in the common bile duct (arrows).

Manometry of the sphincter of Oddi—in patients with pain possibly of biliary origin or due to acute recurrent pancreatitis—is associated with an unusually high rate of pancreatitis (20% to 25%).¹ These patients experience episodic epigastric or right upper-quadrant abdominal pain and elevated biliary enzymes or acute recurrent pancreatitis.

Neither endoscopic ultrasonography nor MRCP can reliably diagnose sphincter dysfunction or ampullary stenosis. Therefore, patients with a very high pretest probability of one of these conditions may benefit from ERCP as the first endoscopic test. In fact, in these patients sphincterotomy performed via ERCP may be curative. However, many more patients undergo this intervention only to find that there is no benefit because their pain was caused by adhesions or a functional disorder.³³ Unfortunately, the relief of pain after endoscopic sphincterotomy can be short-lived, even when manometric abnormalities are documented.

■ BILE DUCT STONES AND ACUTE GALLSTONE PANCREATITIS

ERCP is the treatment of choice for bile duct stones (FIGURE 3). The incidence of symptomatic gallstone disease is high, with an estimated 700,000 patients undergoing cholecys-

tectomy (combined estimate of open and laparoscopic procedures) annually in the United States, and 10% to 15% of these patients have concomitant bile duct stones. ERCP is sensitive for the detection of bile duct stones but is not warranted as a screening test for patients with symptomatic cholelithiasis.³⁴

ERCP with endoscopic sphincterotomy

Two randomized trials of urgent ERCP with sphincterotomy in patients with severe pancreatitis due to gallstones showed lower morbidity rates and shorter hospital stays vs conservative treatment.^{35,36} However, a later study by Fölsch et al that excluded patients with biliary obstruction showed that early ERCP in patients with acute biliary pancreatitis was not helpful.³⁷

ERCP with sphincterotomy (FIGURE 4) allows access to the stones for extraction balloons, baskets, and lithotripsy devices, with a success rate over 90%.³⁸ In patients with many stones or large stones, placement of temporary plastic bile duct stents is standard to prevent obstruction by stone fragments, and repeated procedures are often required.

Removing stones

Endoscopic clearance of stones from the bile duct may be performed before or after elective cholecystectomy, although laparoscopic bile duct exploration is also acceptable for clearing bile duct stones. The added benefit of endoscopic sphincterotomy to augment bile drainage for prevention of stone recurrence has not been compared with the laparoscopic approach, which is a relatively recent intervention.

Current uses of intraoperative cholangiography

Intraoperative cholangiography is a safe method of identifying the anatomy of the extrahepatic biliary tree and has become the standard method of determining the presence of bile duct stones in patients undergoing elective laparoscopic cholecystectomy. It has a sensitivity of 87% (95% confidence interval [CI] 86%–88%), a specificity of 98% (95% CI 97%–99%), and a negative predictive value of 98% (97%–99%).³⁹ Once bile duct stones are confirmed, options include open duct explo-

A temporary stent at the pancreatic orifice may help prevent pancreatitis due to ERCP

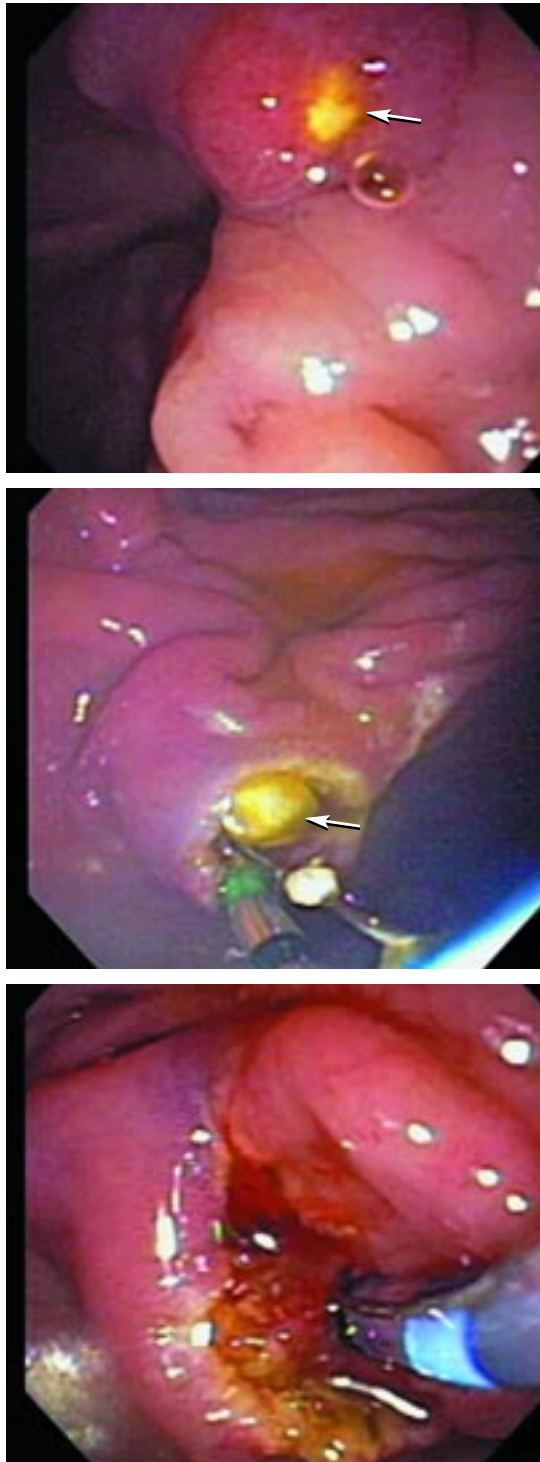


FIGURE 4. Photographs taken during ERCP show an impacted common bile duct stone at the ampulla, which caused acute biliary or gallstone pancreatitis. The cholesterol stone is dislodged via endoscopic sphincterotomy.

PHOTOS COURTESY OF JOHN J. VARGO, MD

ration, laparoscopic duct exploration, or post-operative ERCP.

Noninvasive imaging

For patients with suspected bile duct stones, objective evidence can be found with routine abdominal ultrasonography or CT on occasion, although these are far less sensitive than endoscopic ultrasonography or MRCP.

Endoscopic ultrasonography can exclude a bile duct stone with the same or higher accuracy than ERCP, but without the risk of pancreatitis. In contrast to MRCP, the accuracy of endoscopic ultrasonography is not diminished by stones 4 mm or less and normal bile duct diameter (< 8 mm).^{40,41}

Other limitations of MRCP include artifacts due to surgical clips, pneumobilia, or duodenal diverticuli, and in patients with implantable devices or claustrophobia.

In a decision analysis comparing strategies of MRCP, endoscopic ultrasonography, and selective ERCP for patients suspected of having acute biliary pancreatitis, ultrasonography appeared to be the safest and most cost-effective.⁴²

Factors that increase the likelihood of stones

The probability of common bile duct stones in patients with symptomatic cholelithiasis can be determined from several clinical factors: eg, age over 55, bilirubin greater than 1.8 mg/dL, ultrasound evidence of a dilated bile duct (> 5 mm) or a stone, and cholangitis make finding common bile duct stones more likely.

Deciding which procedure to use

Algorithms are useful in guiding clinic care, but limited expertise with and availability of ERCP, MRCP, and intraoperative cholangiography impede widespread applicability. In a prospective study, Liu et al⁴³ selected ERCP, MRCP, or intraoperative cholangiography based on risk as determined by both the clinical “tempo” of liver and pancreatic enzyme abnormalities (ie, persistent cholestasis vs resolving cholestasis or pancreatitis) and the degree of bile duct dilation. They successfully identified 92.3% of patients with bile duct stones.

Risk factors for stones:

Age > 55

Bilirubin > 1.8

Dilated bile duct
Cholangitis

Algorithm for patients with suspected common bile duct stones based on clinical features

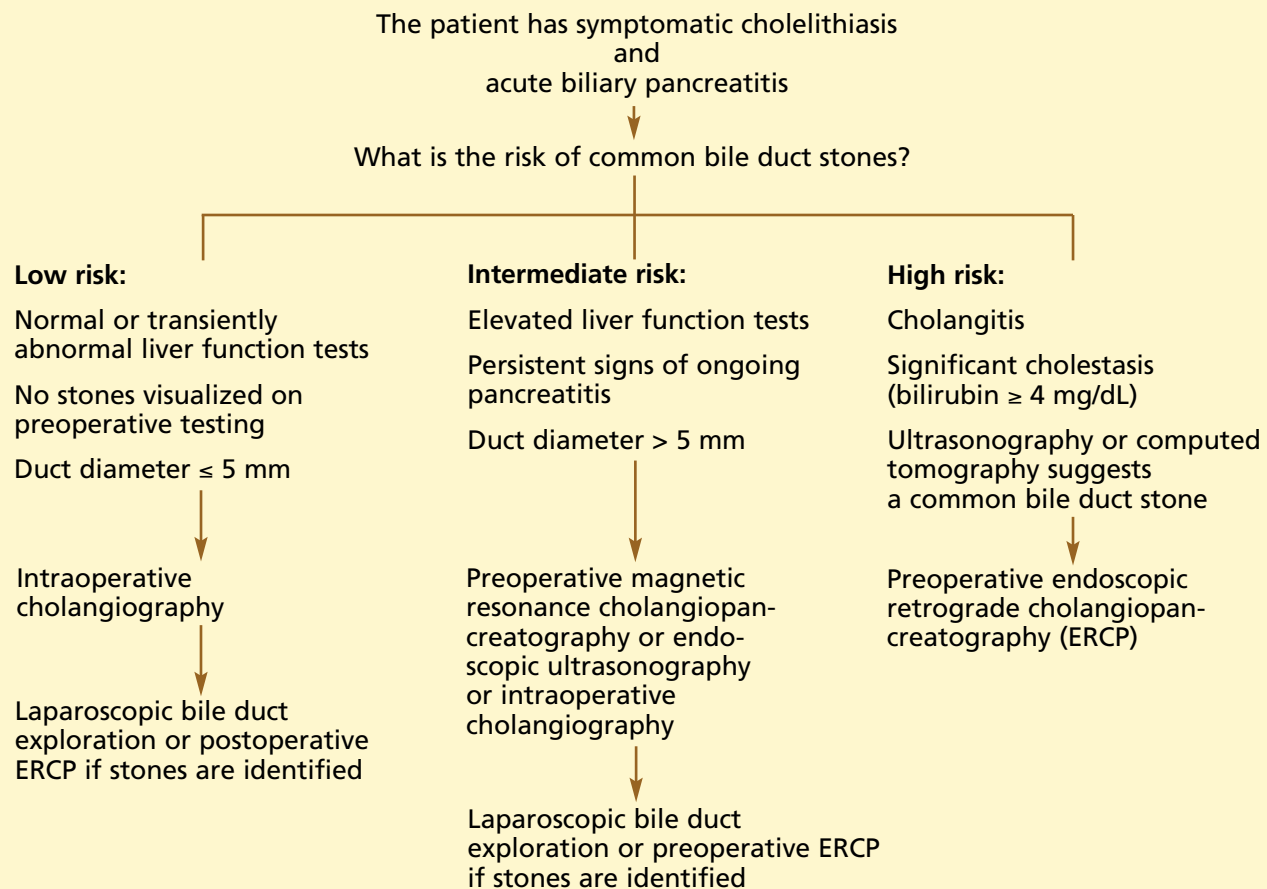


FIGURE 5.

The decision to go with ERCP when bile duct stones are suspected is best made by an experienced endoscopist, a surgeon, and a well-informed patient. FIGURE 5 presents an algorithm for the management of patients with symptomatic cholelithiasis presenting with acute biliary pancreatitis.

■ ERCP TO TREAT COMPLICATIONS OF OPEN SURGERY, LAPAROSCOPY

ERCP is well suited to evaluate for and to treat bile duct leaks and biliary tract injury after open or laparoscopic biliary surgery. As the use of laparoscopic cholecystectomy

rapidly expanded, ERCP became an important tool in managing its complications.

Treating bile duct leaks

Bile duct leaks are quite amenable to endoscopic biliary sphincterotomy and stent placement. The most common signs and symptoms of a leak are drainage of bile via an abdominal drain and collection of bile in the peritoneum, resulting in pain and fever. Success rates for correcting bile duct leaks via ERCP are more than 90%.⁴⁴⁻⁴⁷ Liver transplant patients are candidates for ERCP with stent placement when a leak occurs early after transplantation, or later with removal of a biliary T-tube.⁴⁸

Patients with bile leaks are routinely scheduled for plastic stent exchange every 2 to 3 months until the leak resolves.

Correcting strictures

Injury to the common bile duct, common hepatic duct, or an accessory right bile duct that results in a stricture may occur as a result of cholecystectomy (both open and laparoscopic). Generally, stricture presents as jaundice or as a rise in levels of alkaline phosphatase and gamma-glutamyl transpeptidase. Endoscopic correction of strictures is usually done via dilation—with tapered rigid dilators or high-pressure balloon catheters—and then placement of multiple stents. This approach is effective and can make surgical intervention unnecessary in many cases. The short-term success rate in anastomotic strictures following liver transplantation approaches 80% to 90%.^{49,50}

Patients with biliary strictures are scheduled for exchange of plastic stents and progressive biliary dilations every 1 to 2 months until the stricture resolves.

■ ERCP IN THE MANAGEMENT OF PANCREATIC AND BILIARY CANCER

ERCP allows access to obstructed bile and pancreatic ducts for collecting tissue samples and placement of stents to temporarily relieve the obstruction.

Diagnostic procedures

The sensitivity of routine brush cytologic study to yield a diagnosis of cancer for malignant strictures is generally low (30%–50%) and may be improved when combined with other techniques such as intraductal biopsy and fine-needle aspiration.⁵¹ In pancreatic cancer, the malignancy may be adjacent to the bile duct, which results in compression without invasion of malignant cells into the region being sampled. In cholangiocarcinoma, the yield is likely to be poor due to the low cellularity and the highly fibrotic nature of this tumor.

The sensitivity of fine-needle aspiration guided by endoscopic ultrasonography is far superior to that of ERCP with brush cytologic or biopsy sampling and is safer.^{52,53}

Stent placement

In patients with unresectable pancreatic and bile duct tumors, endoscopic placement of a bile duct stent is the treatment of choice for palliation of malignant distal bile duct strictures. Proper staging and planning before the procedure may require a multidisciplinary approach, with expertise in radiology and surgery to determine resectability.

The value of endoscopic stent placement in patients undergoing pancreaticoduodenectomy remains controversial, with some speculating that contamination of the obstructed biliary tree results in a higher postoperative infection rate.

Surgical bypass vs endoscopic drainage

Comparisons of surgical bypass vs endoscopic drainage have shown ERCP to be cost-effective and associated with a higher quality of life.^{54,55} Self-expanding metal stents were later proven to have a longer patency than their plastic counterparts (polyethylene or Teflon, 7–10 Fr) due to their larger diameter (8–10 mm).⁵⁶ In a prospective, nonrandomized, multicenter study, the patency rate with metal stents was a median of 231 days (range 27–379), and the overall occlusion rate was 41%.⁵⁷ Early expansion of the metal stent and ease of passage of large-caliber instruments through the tumor strictures were predictors of long-term patency.

Metal stent vs plastic stent

The decision to place a metal vs a plastic biliary stent arises frequently in the care of patients with malignant obstructions. A randomized trial by Prat et al⁵⁸ compared metal stents, plastic stents changed every 3 months, and plastic stents changed only when stent dysfunction was clinically evident. The study found relief of jaundice to be comparable among the three groups. Complication-free survival was longer in those with metal stents and in those with plastic stents that were exchanged every 3 months. Cost analysis showed an advantage to metal stents in patients surviving longer than 6 months, and to plastic stents exchanged every 3 months in those surviving less than 6 months.

Occlusion of plastic and metal stents causes recurrent jaundice, pruritus, and cholangi-

ERCP allows access to obstructed bile and pancreatic ducts due to cancer

tis. Unfortunately, the only option for metal stent occlusion is to place another stent (plastic or metal) within the failed metal stent, because it cannot be removed once the patient's normal or neoplastic tissue has grown into the fine wire braids. Partial coverings on metal stents did not seem to improve the overall patency rate.⁵⁶ Metal stents with a complete covering are expected in the future in the hope of making a large-diameter stent that can be removed.

Biliary obstruction due to hilar tumor. Endoscopic drainage to relieve biliary obstruction due to a hilar tumor is a particular challenge, whether via ERCP or percutaneous transhepatic access. Whether the best stent material is plastic or metal is still a hotly debated issue. Also, contrast injected during ERCP often enters both lobes of the liver, and leaving undrained contrast material in any segment of the liver is believed to increase the risk of cholangitis.

Unilateral or bilateral stent placement?

The design of uncovered metal stents may afford advantages over plastic stents because it allows drainage of multiple segments through the numerous interstices between the metal wires. MRCP and CT are routinely used to guide percutaneous stent placement, but in one study, some investigators used cross-sectional imaging to guide placement of a unilateral metal stent at the first ERCP procedure in patients who were deemed poor candidates for surgery based on the location of the tumor.⁵⁹ The concern about draining all contrast seemed to be unfounded, as routine antibiotic therapy prevented any episodes of ERCP-induced cholangitis.

Although this was a single-center study, the authors made a convincing argument for use of a unilateral metal stent even in the most complicated cases of hilar cholangiocarcinoma. In a similar patient population, the authors guided their catheter into the intrahepatic ducts via the portion of the biliary tree that was most accessible using a guide


wire from below the tumor.⁶⁰ The early complication rates were low, and jaundice resolved completely in 86% of patients. The overall success rate and low complication rate in these patients suggest that stent placement into both the right and left lobes is not necessary. Previously, retrospective data suggested bilateral placement of plastic stents was associated with a better rate of survival and fewer procedural complications.⁶¹ However, a randomized trial of bilateral vs unilateral stent placement failed to show any advantage to bilateral stent placement.⁶²

Percutaneous stent placement

Patients whose symptoms are not adequately relieved by ERCP stents may benefit from the percutaneous approach, since these catheters have multiple side holes that allow flow of bile into the lumen from multiple levels. The risks of the percutaneous approach include peritonitis and pain at the insertion site, while the advantages include ease of access to the stent in times of malfunction to assess patency and stent exchange without the need for endoscopic intervention.

MISCELLANEOUS INDICATIONS FOR ERCP

ERCP is also used in selective cases of pancreatic pseudocyst drainage, pancreatic duct leaks due to trauma or pancreatitis, chronic pancreatitis with stone extraction or stricture dilation, and assessment of the biliary and pancreatic orifices during endoscopic removal of adenomas of the duodenum involving the ampulla (ampullectomy).

ERCP is occasionally used for diagnostic purposes when MRCP and other imaging studies are inconclusive or when there is a concern that they would be unreliable. Examples include suspected cases of primary sclerosing cholangitis early in the disease, when the changes in duct morphology are subtle, or in a patient with a nondilated bile duct and clinical signs and symptoms highly suggestive of a gallstone or biliary sludge (microlithiasis). 

Despite advances in ERCP, the risk of pancreatitis and bleeding still need to be considered

REFERENCES

1. ASGE Standards of Practice Committee. Complications of ERCP. *Gastrointest Endosc* 2003; 57:633–638.
2. Cotton PB, Lehman G, Vennes J, et al. Endoscopic sphincterotomy complications and their management: an attempt at consensus. *Gastrointest Endosc* 1991; 37:383–393.
3. Freeman ML, Nelson DB, Sherman S, et al. Complications of endoscopic biliary sphincterotomy. *N Engl J Med* 1996; 335:909–918.
4. Loperfido S, Angelini G, Benedetti G, et al. Major early complications

- from diagnostic and therapeutic ERCP: a prospective multicenter study. *Gastrointest Endosc* 1998; 48:1–10.
5. Cohen S, Bacon BR, Berlin JA, et al. National Institutes of Health State-of-the-Science Conference Statement: ERCP for diagnosis and therapy, January 14–16, 2002. *Gastrointest Endosc* 2002; 56:803–809.
 6. Mitchell RM, O'Connor F, Dickey W. Endoscopic retrograde cholangiopancreatography is safe and effective in patients over 90 years of age and older. *J Clin Gastroenterol* 2003; 36:72–74.
 7. Rodriguez-Gonzalez FJ, Naranjo-Rodriguez A, Mata-Tapia I, et al. ERCP in patients 90 years of age and older. *Gastrointest Endosc* 2003; 58:220–225.
 8. Freeman ML, Guda NM. ERCP cannulation: a review of reported techniques. *Gastrointest Endosc* 2005; 61:112–125.
 9. Messmann H, Vogt W, Holstege A, et al. Post-ERCP pancreatitis as a model for cytokine induced acute phase response in acute pancreatitis. *Gut* 1997; 40:80–85.
 10. Norman J, Franz M, Messina J, et al. Interleukin-1 receptor antagonist decreases severity of experimental acute pancreatitis. *Surgery* 1995; 117:648–655.
 11. Murray B, Carter R, Imrie C, Evans S, O'Suilleabhain C. Diclofenac reduces the incidence of acute pancreatitis after endoscopic retrograde cholangiopancreatography. *Gastroenterol* 2003; 124:1786–1791.
 12. Moretto M, Zaballa M, Casado I, et al. Transdermal glyceryl trinitrate for prevention of post-ERCP pancreatitis: a randomized double blind trial. *Gastrointest Endosc* 2003; 57:1–7.
 13. Katsinelos P, Kountouras J, Chatzis J, et al. High-dose allopurinol for prevention of post-ERCP pancreatitis: a prospective randomized double-blind controlled trial. *Gastrointest Endosc* 2005; 61:407–415.
 14. Tsujino T, Komatsu Y, Isayama H, et al. Ulinastatin for pancreatitis after endoscopic retrograde cholangiopancreatography: a randomized controlled trial. *Clin Gastroenterol Hepatol* 2005; 3:376–383.
 15. Van Laethem J, Marchant A, Delvaux A, et al. Interleukin 10 prevents necrosis in murine experimental acute pancreatitis. *Gastroenterol* 1995; 108:1917–1922.
 16. Rongione AJ, Kusske AM, Kwan K, Ashley SW, Reber HA, McFadden DW. Interleukin 10 reduces the severity of acute pancreatitis in rats. *Gastroenterol* 1997; 112:960–967.
 17. Diviere J, Le Moine O, Van Laethem JL, et al. Interleukin 10 reduces the incidence of pancreatitis after therapeutic endoscopic retrograde cholangiopancreatography. *Gastroenterol* 2001; 120:498–505.
 18. Dumot JA, Conwell DL, Zuccaro G, et al. A randomized, double blind study of interleukin-10 for the prevention of ERCP-induced pancreatitis. *Am J Gastroenterol* 2001; 96:2098–2102.
 19. Weiner GR, Geenen JE, Hogan WJ, Catalano MF. Use of corticosteroids in the prevention of post-ERCP pancreatitis. *Gastrointest Endosc* 1995; 42:579–583.
 20. Dumot JA, Conwell DL, O'Connor JB, et al. Pretreatment with methylprednisolone to prevent ERCP-induced pancreatitis: a randomized, multicenter, placebo-controlled clinical trial. *Am J Gastroenterol* 1998; 93:61–65.
 21. Sherman S, Blaut U, Watkins JL, et al. Does prophylactic administration of corticosteroids reduce the risk and severity of post-ERCP pancreatitis: a randomized, prospective, multicenter study. *Gastrointest Endosc* 2003; 58:23–29.
 22. Cavallini G, Tittobello A, Frulloni L, Masci E, Mariani A, Di Francesco V. Gabexate for the prevention of pancreatic damage related to endoscopic retrograde cholangiopancreatography. *N Engl J Med* 1996; 335:919–923.
 23. Masci E, Cavallini G, Mariani A, et al. Comparison of two dosing regimes of gabexate in the prophylaxis of post-ERCP pancreatitis. *Am J Gastroenterol* 2003; 98:2182–2186.
 24. Tarnasky P, Palesch Y, Cunningham J, et al. Pancreatic stenting prevents pancreatitis after biliary sphincterotomy in patients with sphincter of Oddi dysfunction. *Gastroenterology* 1998; 115:1518–1524.
 25. Fazel A, Quadri A, Catalano MF, Meyerson SM, Geenen JE. Does a pancreatic duct stent prevent post-ERCP pancreatitis? A prospective randomized study. *Gastrointest Endosc* 2003; 57:291–294.
 26. Romagnuolo J, Bardou M, Rahme E, Joseph L, Reinhold C, Barkun AN. Magnetic resonance cholangiopancreatography: a meta-analysis of test performance in suspected biliary disease. *Ann Intern Med* 2003; 139:547–558.
 27. Canto MI, Chak A, Stellato T, et al. Endoscopic ultrasonography versus cholangiography for the diagnosis of choledocholithiasis. *Gastrointest Endosc* 1998; 47:439–448.
 28. Norton SA, Alderson D. Prospective comparison of endoscopic ultrasonography and endoscopic retrograde cholangiopancreatography in the detection of bile duct stones. *Br J Surg* 1997; 84:1366–1369.
 29. Palazzo L, Girollet PP, Salmeron M, et al. Value of endoscopic ultrasonography in the diagnosis of common bile duct stones: comparison with surgical exploration and ERCP. *Gastrointest Endosc* 1995; 42:225–231.
 30. Erickson RA, Garza AA. EUS with EUS-guided fine needle aspiration as the first endoscopic test for the evaluation of obstructive jaundice. *Gastrointest Endosc* 2001; 53:475–484.
 31. Sandy H, Cooperman A, Siegel J. Endoscopic ultrasonography compared with computer tomography with ERCP in patients with obstructive jaundice or small peri-pancreatic mass. *Gastrointest Endosc* 1992; 38:27–34.
 32. ASGE guideline: the role of ERCP in diseases of the biliary tract and the pancreas. *Gastrointest Endosc* 2005; 62:1–8.
 33. Desautels SG, Slivka A, Hutson W, et al. Postcholecystectomy pain syndrome: pathophysiology of abdominal pain in sphincter of Oddi type III. *Gastroenterology* 1999; 116:900–905.
 34. Chang L, Lo S, Stabile BE, Lewis RJ, Toosie K, de Virgilio C. Preoperative versus postoperative endoscopic retrograde cholangiopancreatography. *Ann Surg* 2000; 231:82–87.
 35. Fan ST, Lai EC, Mok FP, Lo CM, Zheng SS, Wong J. Early treatment of acute biliary pancreatitis by endoscopic papillotomy. *N Engl J Med* 1993; 328:228–232.
 36. Neoptolemos JP, Carr-Locke DL, London NJ, Bailey IA, James D, Fossard DP. Controlled trial of urgent endoscopic retrograde cholangiopancreatography and endoscopic sphincterotomy versus conservative treatment for acute pancreatitis due to gallstones. *Lancet* 1988; 2:979–983.
 37. Fölsch UR, Nitsche R, Lüdtkke R, Hilgers RA, Creutzfeldt W. Early ERCP and papillotomy compared with conservative treatment for acute biliary pancreatitis. *N Engl J Med* 1997; 336:237–242.
 38. Leung JW, Neuhaus H, Chopita N. Mechanical lithotripsy in the common bile duct. *Endoscopy* 2001; 33:800–804.
 39. Tse F, Barkun JS, Barkun AN. The evaluation of patients with suspected choledocholithiasis undergoing laparoscopic cholecystectomy. *Gastrointest Endosc* 2004; 60:437–448.
 40. David V, Reinhold C, Hochman M, et al. Pitfalls in the interpretation of MR cholangiopancreatography. *AJR* 1998; 170:1055–1059.
 41. Sugiyama M, Atomi Y. Endoscopic ultrasonography for diagnosing choledocholithiasis: a prospective comparative study with ultrasonography and computed tomography. *Gastrointest Endosc* 1997; 45:143–146.
 42. Romagnuolo J, Currie G. Noninvasive vs selective invasive biliary imaging for acute biliary pancreatitis: an economic evaluation by using decision tree analysis. *Gastrointest Endosc* 2005; 61:86–97.
 43. Liu TH, Consorti ET, Kawashima A, et al. Patient evaluation and management with selective use of magnetic resonance cholangiography and endoscopic retrograde cholangiopancreatography before laparoscopic cholecystectomy. *Ann Surg* 2001; 234:33–40.
 44. De Palma GD, Galloro G, Iuliano G, et al. Leaks from laparoscopic cholecystectomy. *Hepatogastroenterology* 2002; 49:924–925.
 45. Kaffes AJ, Hourigan L, De Luca N, Byth K, Williams SJ, Bourke MJ. Impact of endoscopic intervention in 100 patients with suspected postcholecystectomy bile leak. *Gastrointest Endosc* 2005; 61:269–275.
 46. Mergener K, Strobel JC, Suhocki P, et al. The role of ERCP in the diagnosis and management of accessory bile duct leaks after chole-



- cystectomy. *Gastrointest Endosc* 1999; 50:527–531.
47. Sugiyama M, Mori T, Atomi Y. Endoscopic nasobiliary drainage for treating bile leak after laparoscopic cholecystectomy. *Hepatogastroenterology* 1999; 46:762–765.
48. Morelli J, Mulcahy HE, Willner IR, et al. Endoscopic treatment of post-liver transplantation biliary leaks with stent placement across the leak site. *Gastrointest Endosc* 2001; 54:471–475.
49. Rerknimitr R, Sherman S, Fogel EL, et al. Biliary tract complications after orthotopic liver transplantation with choledochocholedochostomy anastomosis: endoscopic findings and results of therapy. *Gastrointest Endosc* 2002; 55:224–231.
50. Draganov P, Hoffman B, Marsh W, Cotton P, Cunningham J. Long-term outcome in patients with benign biliary strictures treated endoscopically with multiple stents. *Gastrointest Endosc* 2002; 55:680–686.
51. Jaiiwala J, Fogel EL, Sherman S, et al. Triple-tissue sampling at ERCP in malignant biliary obstruction. *Gastrointest Endosc* 2000; 51:383–390.
52. Wiersema MJ, Vilman P, Giovannini M, Chang KJ, Wiersema LM. Endosonography-guided fine-needle aspiration biopsy: diagnostic accuracy and complication assessment. *Gastroenterology* 1997; 112:1087–1095.
53. Wiersema MJ, Wiersema LM, Khusro Q, et al. Combined endosonography and fine-needle aspiration cytology in the evaluation of gastrointestinal lesions. *Gastrointest Endosc* 1994; 40:199–206.
54. Smith AC, Dowsett JF, Rissell RCG, et al. Randomized trial of endoscopic stenting versus surgical bypass in malignant low bile duct obstruction. *Lancet* 1994; 344:1655–1660.
55. Raikar GV, Melin MM, Ressa A, et al. Cost-effective analysis of surgical palliation versus endoscopic stenting in the management of unresectable pancreatic cancer. *Ann Surg Oncol* 1996; 3:470–475.
56. Isayama H, Komatsu Y, Tsujino T, et al. Polyurethane-covered metal stent for management of distal malignant biliary obstruction. *Gastrointest Endosc* 2002; 55:366–370.
57. Kim HS, Lee DK, Kim HG, et al. Features of malignant biliary obstruction affecting the patency of metallic stents: a multicenter study. *Gastrointest Endosc* 2002; 55:359–365.
58. Prat F, Chapat O, Ducot B, et al. A randomized trial of endoscopic drainage methods for inoperable malignant strictures of the common bile duct. *Gastrointest Endosc* 1998; 47:1–7.
59. Freeman ML, Overby C. Selective MRCP and CT targeted drainage of malignant hilar biliary obstruction with self-expanding metallic stents. *Gastrointest Endosc* 2004; 58:41–49.
60. De Palma GD, Pezzullo A, Rega M, et al. Unilateral placement of metallic stents for malignant hilar obstruction: a prospective study. *Gastrointest Endosc* 2004; 58:50–53.
61. Chang WH, Kortan P, Haber GB. Outcome in patients with bifurcation tumors who undergo unilateral versus bilateral hepatic duct drainage. *Gastrointest Endosc* 1998; 47:354–362.
62. De Palma GD, Galloro G, Lovino P, Catanzano C. Unilateral versus bilateral endoscopic hepatic duct drainage in patients with malignant hilar biliary obstruction: results of a prospective, randomized and controlled study. *Gastrointest Endosc* 2001; 53:547–553.

ADDRESS: John A. Dumot, DO, Department of Gastroenterology and Hepatology, A30, Cleveland Clinic, 9500 Euclid Avenue, Cleveland, OH 44195; e-mail dumotj@ccf.org.