



OCTAVIAN C. IOACHIMESCU, MD

Department of Pulmonary, Allergy, and Critical Care
Medicine, Cleveland Clinic

JAMES K. STOLLER, MD, MS

Department of Pulmonary, Allergy, and Critical Care
Medicine, Cleveland Clinic

A middle-aged woman with chronic liver disease and shortness of breath

A 48-YEAR-OLD WOMAN with a history of primary biliary cirrhosis presents with dyspnea that has worsened over the past 3 months. She says she has difficulty breathing when she assumes an upright position, even if she does not walk. The shortness of breath gets worse with walking and is not paroxysmal.

She has never smoked and is in good health despite the diagnosis of primary biliary cirrhosis, made on the basis of a liver biopsy 2 years before. She has no history of coronary artery disease or significant risk factors, alcohol consumption, hepatitis, or CREST syndrome (calcinosis cutis, Raynaud phenomenon, esophageal dysfunction, sclerodactyly, and telangiectasia), and she has never been hospitalized. She has no family history of liver or lung disease. Current medications include calcium, aspirin 81 mg daily, and furosemide 20 mg once daily as needed for pedal edema.

■ PHYSICAL EXAMINATION

The patient is awake and alert.

Vital signs: Oral temperature 37.4°C (99.3°F), pulse 110 beats per minute, blood pressure 124/86 mm Hg (sitting and standing), respiratory rate 18 per minute, oxygen saturation by pulse oximetry while breathing room air 86% in the sitting position and 90% supine.

Head: Normocephalic, and no trauma is noted. Examination of the eyes shows xanthelasmata over the eyelids and mild icterus. Examination of the head, eyes, ears, nose, and throat is otherwise normal.

Neck: No stridor is heard.

Lung auscultation: Bilateral rales are

noted approximately one quarter of the way up both lungs; no bruits or wheezes.

Cardiac examination: Tachycardia is noted, but no hepatojugular reflux or jugular venous distention. Heart tones are normal without an increased P₂. No heaves, rubs, thrills, or murmurs are noted.

Abdominal examination: Mild ascites; the liver spans 15 cm, is palpable approximately 2 cm below the right costal margin, and is not pulsatile; a spleen tip is palpable below the left costal margin; no caput medusa.

Extremities: Traces of bilateral pedal edema and noteworthy clubbing of all digits.

Skin: Mild icterus, xanthelasma over the eyes, and spider telangiectasia on the trunk and chest. Multiple excoriations are noted, which are thought to be due to scratching.

Neurologic status: The patient is oriented to person, place, and time. There is no asterixis. The neurologic examination is nonfocal.

Laboratory tests

- White blood cell count $7.5 \times 10^9/L$ (normal 4–11)
- Hemoglobin concentration 13.8 g/dL (normal 13.5–17.5)
- Platelet count $40 \times 10^9/L$ (normal 150–400)
- Total bilirubin 3.2 mg/dL (normal 0.3–1.2)
- Aspartate aminotransferase 58 IU/L (normal 7–45)
- Alanine aminotransferase 62 IU/L (normal 0–40)
- Blood urea nitrogen, creatinine, and electrolyte concentrations: normal.

She has difficulty breathing when she assumes an upright position, even without walking

TABLE 1

Mechanisms of hypoxemia and examples

| MECHANISM | EXAMPLE |
|---|--|
| Ventilation-perfusion mismatch | Pneumonia |
| Anatomic right-to-left shunt | Ventricular septal defect, atrial septal defect with right-to-left flow |
| Diffusion impairment | Idiopathic pulmonary fibrosis |
| Hypoventilation | Amyotrophic lateral sclerosis |
| Inhalation of gas with a decreased partial pressure of oxygen | Travel to high altitude without supplemental oxygen, breathing a hypoxic gas mixture |
| Diffusion-perfusion impairment | Hepatopulmonary syndrome |

Additional studies

Plain chest (posteroanterior) radiography shows a normal cardiac silhouette, subtly increased interstitial markings in both lung bases, no pulmonary nodules, and clear costophrenic angles.

Arterial blood gasses on room air (supine at rest):

- Partial pressure of arterial oxygen (PaO_2) 56 mm Hg (normal 85–95)
- Partial pressure of arterial carbon dioxide (PaCO_2) 32 mm Hg (normal 22–28)
- pH 7.47 (normal 7.35–7.45)
- Alveolar-arterial oxygen gradient 43 mm Hg (normal <16).

DIFFERENTIAL DIAGNOSIS

1 Which of the following is the most likely cause of this patient's hypoxemia?

- ☐ Congestive heart failure
- ☐ Pulmonary embolism
- ☐ Drug toxicity
- ☐ Hepatopulmonary syndrome
- ☐ Hereditary hemorrhagic telangiectasia with pulmonary arteriovenous malformations

The correct answer is hepatopulmonary syndrome. The differential diagnosis for hypoxemia, generally defined as a widened alveolar-arterial

gradient for age, is extensive, and only some of the possibilities are included in the list of answer choices above. Broadly, six mechanisms of hypoxemia must be considered. **TABLE 1** presents these mechanisms and several examples.

In the evaluation of hypoxemia, calculation of the alveolar-arterial oxygen gradient is important, because it helps to distinguish two of the mechanisms of hypoxemia associated with the normal alveolar-arterial oxygen gradient when adjusted for age (ie, hypoventilation and inhalation of gas with decreased FiO_2) from the other four causes, all of which are associated with an elevated age-specific alveolar-arterial oxygen gradient.

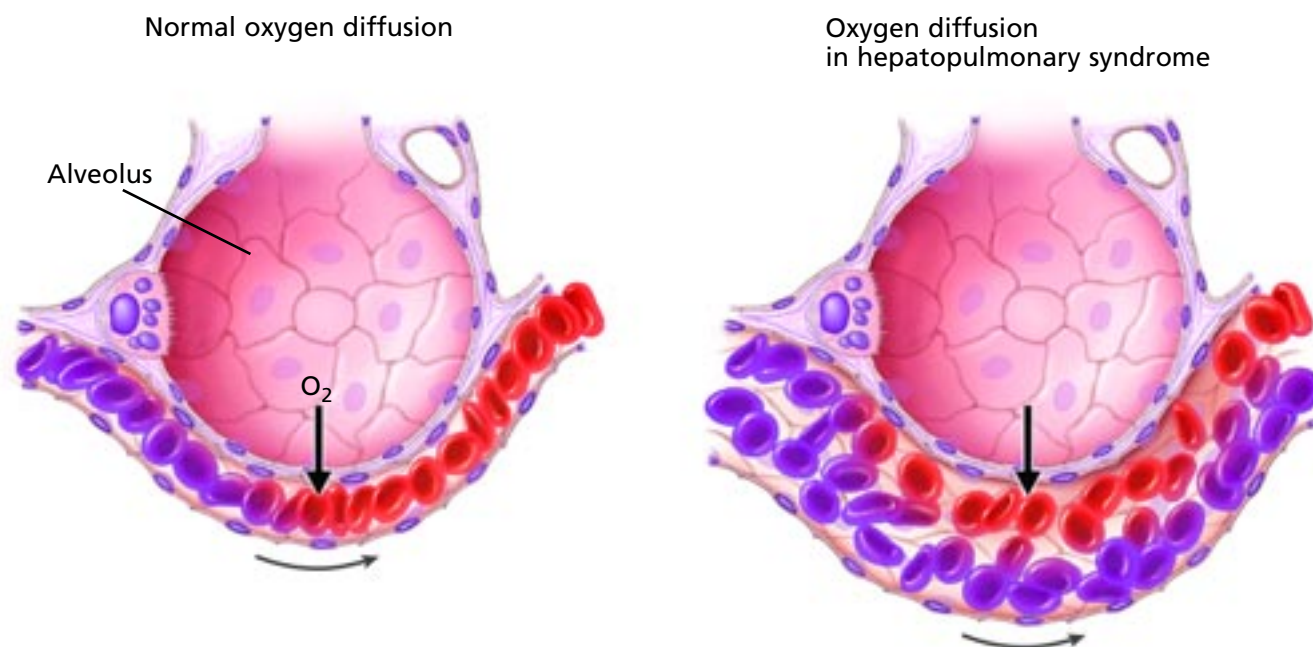
Our patient has the constellation of chronic liver disease, an elevated alveolar-arterial oxygen gradient (43 mm Hg, normal < 16 mm Hg for a 48-year-old), bilateral interstitial lung markings, and digital clubbing. Furthermore, she experiences dyspnea simply by standing upright (ie, platypnea). Given her presentation, this unusual symptom should cause the clinician to suspect a cause of worsened oxygenation due to assuming the upright posture.

Though the interstitial infiltrates in the setting of primary biliary cirrhosis raise the specter of interstitial lung disease (which can in fact complicate primary biliary cirrhosis and which is supported by the presence of rales), interstitial fibrosis would not be expected to cause platypnea. Rather, in the face of chronic liver disease and hypoxemia, platypnea should strongly suggest hepatopulmonary syn-

The differential diagnosis of hypoxemia is extensive



■ Hypoxemia in hepatopulmonary syndrome



Medical Illustrator: Joseph Pangrace CCF ©2006

FIGURE 1. The normal pulmonary capillary (left) has a diameter of about 8 μm . The dilated capillary of hepatopulmonary syndrome (right) may have a diameter of up to 100 μm , which means that red blood cells traversing the pulmonary capillary bed may not contact oxygen molecules, thus contributing to so-called diffusion-perfusion impairment and, eventually, hypoxemia.

drome.^{1,2} At the same time, platypnea occurs in only a minority of these patients and is not pathognomonic for the syndrome, as it may accompany other conditions characterized by positional right-to-left shunting (eg, pulmonary arteriovenous malformations, patent foramen ovale with interatrial streaming of blood).

■ KEY FEATURES

Hepatopulmonary syndrome is characterized by the triad of liver disease, hypoxemia (defined by either an alveolar-arterial oxygen gradient exceeding 20 mm Hg or a PaO_2 on room air less than 70 mm Hg), and intrapulmonary vascular dilatations, which represent dilated pulmonary capillaries.^{1,2} These dilatations are responsible for hypoxemia, proposed to be mediated by “diffusion-perfusion impair-

ment,” a combination of diffusion impairment and anatomic right-to-left shunt. Diffusion-perfusion impairment shares features of anatomic right-to-left shunt and diffusion impairment in that inhalation of 100% oxygen causes a partial but incomplete normalization of the PaO_2 . In contrast, in pure anatomic right-to-left shunt, inhalation of 100% oxygen would not be expected to raise the PaO_2 , and in pure diffusion impairment, inhalation of pure oxygen might be expected to normalize the PaO_2 , at least at rest.

The intrapulmonary vascular dilatations are engorged pulmonary capillaries. In contrast to the normal capillary diameter of approximately 8 μm , the pulmonary capillaries in hepatopulmonary syndrome have an enlarged diameter of up to approximately 100 μm . The result is that a red blood cell traversing the pulmonary capillary bed may transit

the pulmonary circulation without contacting oxygen molecules, thereby contributing to the anatomic right-to-left shunt component of diffusion-perfusion impairment (FIGURE 1). This phenomenon is worsened by the increased cardiac output that is characteristic of chronic liver disease,³ which causes red cells to move through the pulmonary capillary bed more quickly than normal, allowing less time to equilibrate with any available oxygen.

The other answer choices above do not explain our patient's hypoxemia. Specifically, the increased interstitial markings on the chest radiograph could represent intrapulmonary vascular dilatations or interstitial fibrosis that accompanies primary biliary cirrhosis. The presence of rales on auscultation favors the latter. There is no history of an acute event to suggest pulmonary embolism. None of the drugs she is taking is likely to cause the subtle interstitial infiltrates found on her chest radiograph. The overall picture does not suggest congestive heart failure.

CASE CONTINUED

The patient undergoes measurement of arterial blood gases while standing and at rest, breathing room air, with the following results: PaO₂ 43 mm Hg, PaCO₂ 30 mm Hg, and pH 7.48.

WHAT CAN SHORTNESS OF BREATH UPON STANDING INDICATE?

2 Which condition can predispose to platypnea and a decrease in PaO₂ upon standing?

- ☐ Patent foramen ovale
- ☐ Pulmonary arteriovenous malformation
- ☐ Interatrial streaming of blood from the right to the left side of the heart
- ☐ All of the above
- ☐ None of the above

The correct answer is all of the above. As noted before, shortness of breath on standing is called platypnea. Worsening of hypoxemia on standing up is called orthodeoxia, some-

times defined as either a 4-mm Hg fall in the PaO₂ on going from supine to standing or a 5% or greater fall in the PaO₂.

Notably, orthodeoxia is opposite to the normal physiologic changes in oxygenation on standing. Specifically, in normal people, oxygenation improves slightly on standing as ventilation-perfusion matching improves; perfusion to the better ventilated lung bases increases with gravity on standing up. In hepatopulmonary syndrome, pulmonary arteriovenous malformation, right-to-left interatrial streaming (eg, through a patent foramen ovale⁴ or atrial septal defect, or via anomalous venous drainage), and anatomic right-to-left shunt can sometimes increase with upright posture. In hepatopulmonary syndrome, this occurs because the intrapulmonary vascular dilatations are characteristically more prominent at the lung bases. Standing up increases perfusion in the lung bases where the dilatations predominate, thereby worsening the anatomic shunt with a resultant widened alveolar-arterial oxygen gradient and decreased PaO₂.

CONFIRMING THE DIAGNOSIS

3 Which additional test can be used to confirm hepatopulmonary syndrome?

- ☐ Contrast-enhanced echocardiography (eg, with saline, indocyanine, or a modified gelatin contrast agent)
- ☐ Technetium Tc 99m pyrophosphate lung scan with detection over brain or abdominal organs
- ☐ Sampling arterial blood gas after the patient breathes 100% oxygen (shunt study)
- ☐ All of the above
- ☐ None of the above

The answer is all of the above. Each of these tests helps support the diagnosis of hepatopulmonary syndrome by demonstrating right-to-left anatomic shunt through the intrapulmonary vascular dilatations that characterize the syndrome.

Chronic liver disease, lung signs, digital clubbing, and platypnea point to hepatopulmonary syndrome



Saline-enhanced echocardiography is the most sensitive of these tests and is considered necessary for diagnosing hepatopulmonary syndrome. In this test, agitated saline is injected intravenously during echocardiography. The appearance of microbubbles in the left atrium or left ventricle is abnormal and is a sign of right-to-left shunt.

The timing of bubbles appearing in the left-sided chambers indicates whether the anatomic shunt is intracardiac (ie, due to an atrial septal defect or a ventricular septal defect) or intrapulmonary (eg, due to intrapulmonary vascular dilatations or arteriovenous malformations, as may be observed in hereditary hemorrhagic telangiectasia). Bubbles appearing within three cardiac cycles of the injection suggest intracardiac right-to-left shunt. Bubbles appearing four or more systoles after injection suggest intrapulmonary shunt, since the delayed appearance of bubbles reflects the time necessary for blood to transit through the pulmonary arteries.³

The newest echocardiographic contrast agents (eg, perflutren) serve similar purposes, although they still have not been fully evaluated in this setting.

Technetium Tc 99m testing

Saline-enhanced echocardiography is highly sensitive for hepatopulmonary syndrome but lacks specificity because it can be abnormal in the absence of hypoxemia (which is one of the diagnostic criteria for the syndrome). Technetium Tc 99m lung scanning is more specific but less sensitive in detecting this syndrome.

In this test, the technetium Tc 99m macroaggregated albumin particles, which are normally trapped within the lung during a conventional lung scan and therefore are visualized within the lung parenchyma, can pass through the pulmonary circulation and be trapped in organs such as the brain, liver, kidney, and spleen. By counting the particles detected outside the chest, one can calculate the percent of shunt present.

Other options

Finally, a shunt study done with the patient breathing pure oxygen can be useful in detecting anatomic right-to-left shunt; however, as

with the lung scan, it does not indicate if the site is intracardiac or intrapulmonary. Thus, this test is perhaps the least useful of the three in evaluating patients with hepatopulmonary syndrome. Furthermore, shunt studies can underestimate the degree of anatomic shunt in patients with the hyperdynamic circulation (and narrowed arteriovenous oxygen content difference) of chronic liver disease.⁵

Hepatopulmonary syndrome is characterized hemodynamically by a state of low vascular resistance and high cardiac output. Invasive functional evaluation such as right-heart catheterization is generally not needed in the evaluation of this condition.

Pulmonary angiography is also rarely needed in these patients and should be reserved only for those with so-called type II hepatopulmonary syndrome, characterized by large intrapulmonary vascular dilatations. These patients may benefit from catheterization and selective embolization therapy of the markedly dilated vessels, which account for most of the anatomic shunt.^{6,7}

Overall, the diagnostic evaluation of a patient with hepatopulmonary syndrome must begin with clinical suspicion based on the setting of chronic liver disease and symptoms, most commonly dyspnea, followed by measuring the room-air arterial blood gases (perhaps ideally with the patient standing, to maximize any anatomic shunt). If the alveolar-arterial oxygen gradient is widened, confirmation of the diagnosis of the syndrome can be sought with saline-enhanced echocardiography.

TREATMENT AND RESOLUTION

4 Which is the treatment for hepatopulmonary syndrome?

- ☐ Surgery to resect intrapulmonary vascular dilatations
- ☐ Ursodeoxycholic acid
- ☐ Liver transplantation
- ☐ All of the above
- ☐ None of the above

The correct answer is liver transplantation.

Lung scanning is more specific but less sensitive than saline echocardiography for hepatopulmonary syndrome

**Hepato-
pulmonary
syndrome has
completely
resolved in
many patients
after liver
transplantation**

As recently as 1988, severe hypoxemia was considered a strong contraindication to orthotopic liver transplantation, because of the risks of surgery for hypoxemic patients and early observations that hepatopulmonary syndrome and hypoxemia persisted after transplantation. However, subsequent observations discounted these concerns and showed that oxygenation could normalize and that shunt could reverse following orthotopic transplantation in patients with this syndrome.^{2,8,9} Another argument in favor of transplantation was that oxygenation could worsen over time in untreated patients, even if liver dysfunction was stable.

Although no randomized controlled studies have evaluated the role of orthotopic liver transplantation in hepatopulmonary syndrome, several observational studies have reported postoperative improvements in oxygenation, albeit with persistently impaired diffusing capacity. In a recent study¹⁰ that compared the long-term outcomes of 61 patients with the syndrome who underwent transplantation vs 77 control patients who did not undergo transplantation, transplant recipients had a significant survival benefit overall, although the death rate was higher in those with a preoperative PaO₂ of less than 50 mm Hg.

Overall, complete resolution of the syndrome has been noted in a large number of patients who have undergone orthotopic liver transplantation. Thus, in contrast to earlier views, transplantation is considered the therapy of choice for severe hepatopulmonary syndrome, especially in pediatric patients. Moreover, in children, living hepatic lobar transplantation has been shown to be successful.

Prognostic indicators

While we still lack a specific predictor of post-transplantation response, post-transplantation morbidity has been higher in patients whose preoperative hypoxemia and shunt fraction (on technetium Tc 99m lung scanning) were worse.^{11,12}

Considering the available data about response of this syndrome to liver transplantation, the European Respiratory Society Task Force on Pulmonary-Hepatic Vascular

Diseases has strongly recommended transplantation if the patient's PaO₂ is between 50 and 60 mm Hg. For those with a PaO₂ less than 50 mm Hg, the recommendation is to individualize therapy.¹³

■ MANY TREATMENTS INEFFECTIVE; SOME MAY ALLEVIATE SYMPTOMS

Drugs

Besides liver transplantation, many drug treatments for this syndrome have been explored, most without proof of clinical effectiveness.^{14–17} Nonsteroidal anti-inflammatory drugs,¹⁸ beta blockers, and corticosteroids have been tried without significant clinical impact.

Nondrug treatments

Nonpharmacologic treatments other than liver transplantation have included transjugular intrahepatic portosystemic shunts,^{19–24} venacavoplasty,^{25,26} and, in patients with discrete and large intrapulmonary dilatations, coil embolization of the dilatations.^{7,27,28} Though anecdotal reports suggest these interventions might be effective, the sparse experience precludes firm recommendations.

Garlic (*allium sativum*) has been anecdotally reported to improve gas exchange in these patients.²⁹

Nitric oxide inhibitors have been shown to improve gas exchange in these patients. Increasing evidence suggests that nitric oxide mediates the characteristic intrapulmonary vasodilatation.^{30–32} Schenk et al³³ showed that methylene blue, a nitric oxide synthase inhibitor, is associated with short-lived improvement in oxygenation in these patients. Although this study offers pathophysiologic insights, it has limited clinical impact in that methylene blue is available for short-lived intravenous infusion but is not a long-term therapy.^{33,34}

Overall, practical clinical management of these patients involves serial assessment of clinical symptoms and oxygenation, consideration of coil embolization in selected patients, and forthright discussion and consideration of liver transplantation for appropriate patients wishing to undertake this option.



■ CONCLUSIONS

Our patient's syndrome was a complication of primary biliary cirrhosis. Interstitial lung disease accompanying primary biliary cirrhosis likely exacerbated her dyspnea and, possibly, her hypoxemia. The astute clinician must consider hepatopulmonary syndrome in

patients with hypoxemia complicating chronic or even acute liver disease, with a workup that includes an assessment of gas exchange and contrast-enhanced echocardiography. Though drug therapy is generally disappointing, liver transplantation can normalize oxygenation in patients with hepatopulmonary syndrome and severe hypoxemia. ■

■ REFERENCES

1. Lange PA, Stoller JK. The hepatopulmonary syndrome. *Ann Intern Med* 1995; 122:521–529.
2. Aboussouan LS, Stoller JK. The hepatopulmonary syndrome. *Baillieres Best Pract Res Clin Gastroenterol* 2000; 14:1033–1048.
3. Kowalski HJ, Abelmann W. The cardiac output at rest in Laennec's cirrhosis. *J Clin Invest* 1953; 32:1025–1033.
4. Mercho N, Stoller JK, White RD, Mehta AC. Right-to-left interatrial shunt causing platypnea after pneumonectomy. A recent experience and diagnostic value of dynamic magnetic resonance imaging. *Chest* 1994; 105:931–933.
5. McCarthy K, Stoller JK. Possible underestimation of shunt fraction in the hepatopulmonary syndrome. *Respir Care* 1999; 44:1486–1488.
6. Krowka MJ. Hepatopulmonary syndromes. *Gut* 2000; 46:1–4.
7. Poterucha JJ, Krowka MJ, Dickson ER, Cortese DA, Stanson AW, Krom RA. Failure of hepatopulmonary syndrome to resolve after liver transplantation and successful treatment with embolotherapy. *Hepatology* 1995; 21:96–100.
8. Krowka MJ, Porayko MK, Plevak DJ, et al. Hepatopulmonary syndrome with progressive hypoxemia as an indication for liver transplantation: case reports and literature review. *Mayo Clin Proc* 1997; 72:44–53.
9. Stoller JK, Lange PA, Westveer MK, Carey WD, Vogt D, Henderson JM. Prevalence and reversibility of the hepatopulmonary syndrome after liver transplantation. The Cleveland Clinic experience. *West J Med* 1995; 163:133–138.
10. Swanson KL, Wiesner RH, Krowka MJ. Natural history of hepatopulmonary syndrome: impact of liver transplantation. *Hepatology* 2005; 41:1122–1129.
11. Krowka MJ, Wiseman GA, Burnett OL, et al. Hepatopulmonary syndrome: a prospective study of relationships between severity of liver disease, PaO₂ response to 100% oxygen, and brain uptake after (99m)Tc MAA lung scanning. *Chest* 2000; 118:615–624.
12. Schenk P, Fuhrmann V, Madl C, et al. Hepatopulmonary syndrome: prevalence and predictive value of various cut offs for arterial oxygenation and their clinical consequences. *Gut* 2002; 51:853–859.
13. Rodriguez-Roisin R, Krowka MJ, Herve P, Fallon MB; ERS Task Force Pulmonary-Hepatic Vascular Disorders (PHD) Scientific Committee. Pulmonary-hepatic vascular disorders (PHD). *Eur Respir J* 2004; 24:861–880.
14. Krowka MJ, Dickson ER, Cortese DA. Hepatopulmonary syndrome. Clinical observations and lack of therapeutic response to somatostatin analogue. *Chest* 1993; 104:515–521.
15. Akyuz F, Kaymakoglu S, Demir K, Aksoy N, Adalet I, Okten A. Is there any medical therapeutic option in hepatopulmonary syndrome? A case report. *Eur J Intern Med* 2005; 16:126–128.
16. Alexander J, Greenough A, Baker A, Rela M, Heaton N, Potter D. Nitric oxide treatment of severe hypoxemia after liver transplantation in hepatopulmonary syndrome: case report. *Liver Transpl Surg* 1997; 3:54–55.
17. Altschuler EL, Kast RE. Paroxetine for hepatopulmonary syndrome? *Med Hypotheses* 2004; 62:446–447.
18. Song JY, Choi JY, Ko JT, et al. Long-term aspirin therapy for hepatopulmonary syndrome. *Pediatrics* 1996; 97:917–920.
19. Paramesh AS, Husain SZ, Shneider B, et al. Improvement of hepatopulmonary syndrome after transjugular intrahepatic portosystemic shunting: case report and review of literature. *Pediatr Transplant* 2003; 7:157–162.
20. Riegler JL, Lang KA, Johnson SP, Westerman JH. Transjugular intrahepatic portosystemic shunt improves oxygenation in hepatopulmonary syndrome. *Gastroenterology* 1995; 109:978–983.
21. Zhao Z, Yan T, Tao K, et al. [TIPSS for the treatment of hepatopulmonary syndrome]. *Zhonghua Gan Zang Bing Za Zhi* 2002; 10:69.
22. Selim KM, Akriviadis EA, Zuckerman E, Chen D, Reynolds TB. Transjugular intrahepatic portosystemic shunt: a successful treatment for hepatopulmonary syndrome. *Am J Gastroenterol* 1998; 93:455–458.
23. Sanyal AJ. The use and misuse of transjugular intrahepatic portosystemic shunts. *Curr Gastroenterol Rep* 2000; 2:61–71.
24. Ong JP, Sands M, Younossi ZM. Transjugular intrahepatic portosystemic shunts (TIPS): a decade later. *J Clin Gastroenterol* 2000; 30:14–28.
25. De BK, Sen S, Biswas PK, Sanyal R, Jumdar DM, Biswas J. Hepatopulmonary syndrome in inferior vena cava obstruction responding to cavoplasty. *Gastroenterology* 2000; 118:192–196.
26. De BK, Sen S, Biswas PK, et al. Occurrence of hepatopulmonary syndrome in Budd-Chiari syndrome and the role of venous decompression. *Gastroenterology* 2002; 122:897–903.
27. Yoshimi M, Takayama K, Aizawa H, et al. [Pulmonary arteriovenous fistula treated by embolization with steel coils]. *Nihon Kyobu Shikkan Gakkai Zasshi* 1996; 34:569–574.
28. Ryu JK, Oh JH. Hepatopulmonary syndrome: angiography and therapeutic embolization. *Clin Imaging* 2003; 27:97–100.
29. Abrams GA, Fallon MB. Treatment of hepatopulmonary syndrome with *Allium sativum* L (garlic): a pilot trial. *J Clin Gastroenterol* 1998; 27:232–235.
30. Rolla G. Hepatopulmonary syndrome: role of nitric oxide and clinical aspects. *Dig Liver Dis* 2004; 36:303–308.
31. Rolla G, Brussino L, Colagrande P, et al. Exhaled nitric oxide and impaired oxygenation in cirrhotic patients before and after liver transplantation. *Ann Intern Med* 1998; 129:375–378.
32. Vallance P, Moncada S. Hyperdynamic circulation in cirrhosis: a role for nitric oxide? *Lancet* 1991; 337:776–778.
33. Schenk P, Madl C, Rezaie-Majd S, Lehr S, Muller C. Methylene blue improves the hepatopulmonary syndrome. *Ann Intern Med* 2000; 133:701–706.
34. Rolla G, Bucca C, Brussino L. Methylene blue in the hepatopulmonary syndrome. *N Engl J Med* 1994; 331:1098.

ADDRESS: Octavian C. Ioachimescu, MD, Department of Pulmonary, Allergy, and Critical Care Medicine, A90, Cleveland Clinic, 9500 Euclid Avenue, Cleveland, OH 44195; email oioac@yahoo.com.