



RAVINDRAN A. PADMANABHAN, MD, MRCP (UK)

Department of Infectious Diseases,
The Cleveland Clinic Foundation

LEONARD H. CALABRESE, DO

R.J. Fasnmyer Chair of Clinical Immunology,
Vice Chairman, Department of Rheumatic and
Immunologic Diseases, The Cleveland Clinic
Foundation; Professor of Medicine, Cleveland
Clinic Lerner College of Medicine of Case
Western Reserve University

STEVEN M. GORDON, MD

Chairman, Department of Infectious Diseases,
The Cleveland Clinic Foundation; Professor of
Medicine, Cleveland Clinic Lerner College of
Medicine of Case Western Reserve University

The Clinical Picture

An expanding skin lesion in a patient on immunosuppressive therapy

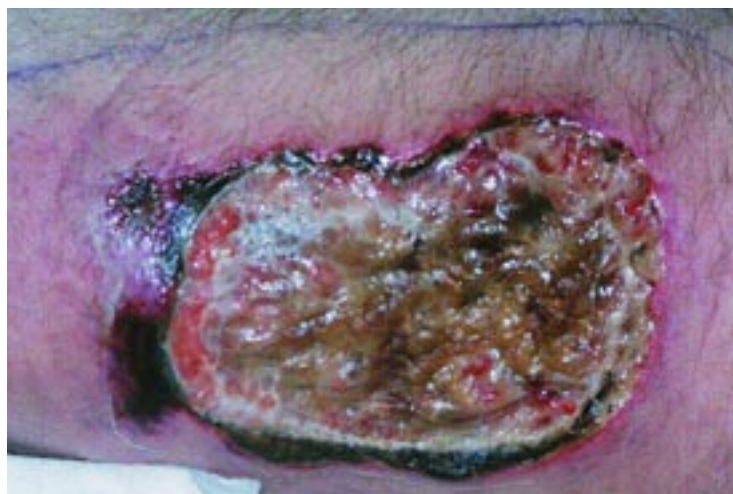

FIGURE 1

A 61-YEAR-OLD CONSTRUCTION WORKER presents with the lesion shown in **FIGURE 1**. The lesion measures 15 cm x 6 cm.

Several months ago, the patient was found to have polymyositis, which was proven by biopsy. His condition improved with treatment with oral steroids (20 mg–40 mg/day). Soon after, he developed pneumonia that resolved with intravenous antibiotics.

Two months later, a “pimple” appeared on his right thigh and steadily grew. He had no fevers, pain, or pathergy. The lesion was diagnosed as pyoderma gangrenosum and was treated with corticosteroids, both orally (50 mg/day) and by intralesional injections. The lesion initially responded but then grew again. Mycophenolate 1,000 mg twice daily was added to the steroid treatment, but the lesion has continued to grow.

Q: What should the next step in management be?

- ☐ Add cyclosporine
- ☐ Add infliximab
- ☐ Recommend surgical intervention
- ☐ Perform a biopsy of the lesion
- ☐ Add minocycline

A: A biopsy of the lesion should be performed.

Cyclosporine, infliximab, minocycline, and surgery are all treatment options in severe or refractory pyoderma gangrenosum. However, pyoderma gangrenosum should not be diagnosed without excluding other conditions first.

In a review of 240 patients who had received a diagnosis of pyoderma gangrenosum, 95 ultimately were found to have a different condition such as vascular occlusive or venous disease, vasculitis, cancer, drug-induced injury, other inflammatory disorders, or primary infection. Primary infections included sporotrichosis, aspergillosis, cryptococcosis, zygomycosis, cutaneous tuberculosis, and infections due to *Penicillium marneffei*, herpes simplex virus 2, and *Amebiasis cutis*.¹

Any immunosuppressed patient in whom a new skin lesion develops should have a biopsy of the lesion with routine, fungal, and acid-fast bacillus stains, culture, and histopathological investigation.²

Case continued

Gomori methenamine silver staining (100 X) of the biopsy specimen reveals multiple yeast-



like organisms within the dermis and subcutaneous tissues. There are also abundant narrow-based buds (FIGURE 2).

A diagnosis of cryptococcosis is made.

Cryptococcus neoformans is frequently associated with droppings from pigeons or other birds, as well as barnyard soil and manure. The patient lives on a farm that occasionally is visited by wild turkeys, but he was not directly exposed to pigeon droppings or rotting vegetation. He has no pets, has not traveled recently, and has no risk factors for human immunodeficiency virus.

On further testing, the patient's serum cryptococcal antigen titer is 1:512. He also undergoes a lumbar puncture, but no cryptococcal antigen is detected in the cerebrospinal fluid. Computed tomography shows no nodular lesions, cavities, lymphadenopathy, or milary disease.

The patient is treated in the hospital with intravenous amphotericin B, which is continued at home. Two weeks later, the ulcer is considerably smaller.

TEACHING POINTS

- A biopsy should be obtained in any immunosuppressed patient with a new skin lesion.
- The tissue should be sent for histopatho-

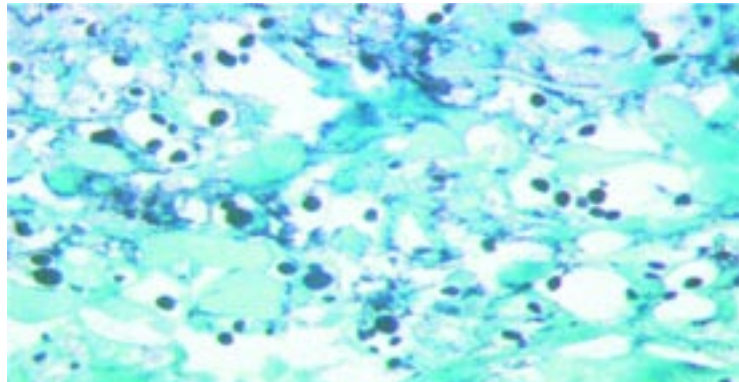


FIGURE 2

logical examination with routine, fungal, and acid-fast bacillus stains and cultures.

- Pyoderma gangrenosum should be a diagnosis of exclusion.
- Close, continuous follow-up of patients is necessary. If there is no response to treatment, the diagnosis must be reconsidered and a biopsy must be repeated.

REFERENCES

1. Weenig RH, Davis MD, Dahl PR, Su WP. Skin ulcers misdiagnosed as pyoderma gangrenosum. *N Engl J Med* 2002; 347:1412-1418.
2. Perfect JR, Casadevall A. Cryptococcosis. *Infect Dis Clin North Am* 2002; 16:837-874, v-vi.

ADDRESS: Steven M. Gordon, MD, Department of Infectious Diseases, S32, The Cleveland Clinic Foundation, 9500 Euclid Avenue, Cleveland, OH 44195; e-mail gordons@ccf.org.