

**AHMED AL-HAZZOURI, MD**Department of Internal Medicine,
Cleveland Clinic**PETER MAZZONE, MD, MPH**Department of Pulmonary, Allergy, and Critical
Care Medicine, Cleveland Clinic

Hypotension in the intensive care unit

A 57-YEAR-OLD MAN is transferred to the intensive care unit from a regular nursing unit after an episode in which he stopped breathing. In fact, he has had several episodes of respiratory arrest due to recurrent mucus plugging in his right lung, for which a tracheostomy tube was recently placed.

He has many other medical problems: paraplegia from a motor vehicle accident, chronic renal failure due to diabetes mellitus, deep venous thrombosis in both legs, recurrent pneumothoraces, and a recent perinephric abscess. His medications include intravenous unfractionated heparin at therapeutic levels for the deep vein thrombosis and antibiotics for the perinephric abscess.

His physicians stabilize his condition by bronchoscopically removing the mucus plug and placing him on mechanical ventilation. A central venous catheter is inserted: his central venous pressure (CVP) is 15 mm Hg.

Hypotension develops

On his second day in the intensive care unit, the patient's blood pressure drops, and intravenous fluids and vasopressor agents fail to bring it back up. His oxygen saturation has not changed.

Vital signs. Temperature 98.4°F (36.9°C), respiratory rate 23 breaths/minute, blood pressure 76/44 mm Hg, heart rate 96 beats/minute, with normal sinus rhythm on telemetry. His CVP is 21 mm Hg. His airway pressures have not changed.

Physical examination. He is in mild respiratory distress, with diminished breath sounds in the base of the right lung, unchanged from the day of admission. On cardiac examination there are no murmurs or rubs, but his heart sounds are distant, and his jugular veins are distended up to nearly 5 cm above the sternal angle. His abdomen is normal. He has pitting edema, which has not changed from admission.

■ DIFFERENTIAL DIAGNOSIS

1 Of the following possible causes of the hypotension in this patient, which is the most likely?

- ☐ Pulmonary embolism
- ☐ Tension pneumothorax
- ☐ Acute arrhythmia
- ☐ Myocardial infarction
- ☐ Fulminant sepsis
- ☐ Cardiac tamponade

Pulmonary embolism is unlikely in this patient, as he was receiving heparin at therapeutic levels and has had no change in oxygenation.

Tension pneumothorax is a complication of mechanical ventilation, but this patient's oxygen requirements have not changed and his airway pressures remain stable, suggesting this is not the diagnosis.

Acute arrhythmias can cause hypotension; however, our patient has a normal rhythm on telemetry and 12-lead electrocardiography.

Myocardial infarction can present as hypotension; however, our patient does not have electrocardiographic changes to support this. His physicians request that his cardiac enzymes be measured to help rule out this diagnosis.

Fulminant sepsis is possible, but the acute onset and absence of fever or new culture results while receiving antibiotics places this lower on our list.

Cardiac tamponade is a cause of hypotension in intensive care. Many things can cause it, including uremia and bleeding into the pericardial space. Our patient is at risk of both of these. Thus, although it is not common, it is the most likely cause his hypotension.

His vital signs:
temp 98.4°F,
pulse 96 and
regular,
respirations 23,
BP 76/44,
CVP 21

A normal CVP tracing

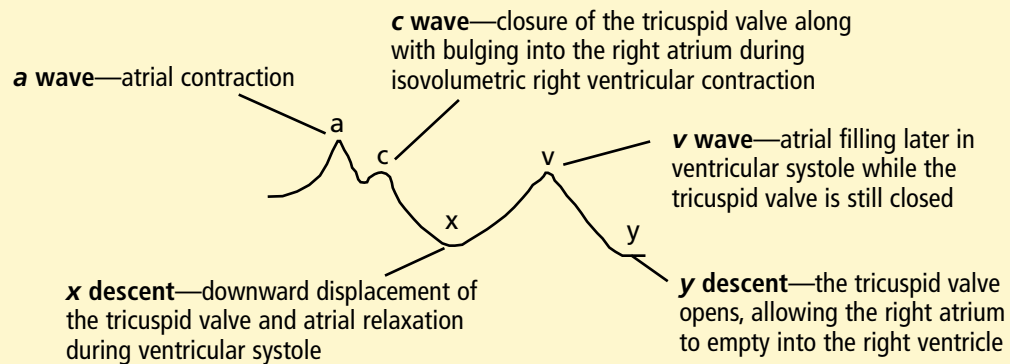


FIGURE 1

The patient's CVP tracing

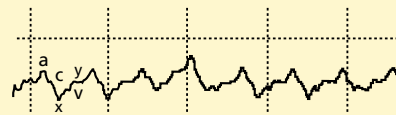

FIGURE 2

■ USING THE CVP TRACING AS A DIAGNOSTIC TOOL

When narrowing these diagnoses in an acutely ill patient, time is of the essence. Although not always specific, a CVP tracing provides readily available information and helps to establish a presumptive diagnosis while more definitive tests are performed. A normal CVP tracing is shown in **FIGURE 1**.

■ CVP EVIDENCE OF TAMPONADE

2 Our patient's CVP tracing during his hypotensive episode is shown in **FIGURE 2**. Which feature or features in his tracing most support the diagnosis of cardiac tamponade?

- ☐ A prominent x descent
- ☐ A prominent a wave
- ☐ An attenuated y descent
- ☐ A blunted c wave

This tracing shows a prominent x descent with attenuation of the y descent, which are consistent with cardiac tamponade.

By definition, during tamponade the right

atrial pressure mirrors the pressure within the pericardium, which changes with the size of the heart during the cardiac cycle. During systole, as blood is ejected from the ventricles, the heart decreases in size. Thus, the intrapericardial pressure falls, reflected by a prominent x descent.

The y descent, on the other hand, occurs during diastole, when blood moves from the atria to the ventricles. In a patient with cardiac tamponade, little blood is entering or leaving the heart during this phase. Its overall size is relatively constant, and thus the intrapericardial pressure changes little. This is reflected by attenuation of the y descent.¹

■ CVP IN OTHER CONDITIONS

3 The CVP tracing can help in diagnosing a variety of other cardiac conditions.² Match the CVP tracings in **FIGURE 3** to the correct diagnoses listed in the figure and below.

- ☐ Constrictive pericarditis
- ☐ Complete atrioventricular node block (AV block)
- ☐ Atrial fibrillation
- ☐ Tricuspid regurgitation
- ☐ Tricuspid stenosis

Constrictive pericarditis is reflected in prominent x and y descents (M contour), with the y descent being the most prominent. It is caused by limited ventricular filling due to a rigid pericardium. Answer: tracing B.

Complete AV block produces asynchrony between atrial and ventricular systole. Occasionally, the right atrium contracts while

In acute hypotension, CVP tracing helps establish a presumptive diagnosis quickly

the tricuspid valve is still closed, producing large *a* waves. Answer: tracing D.

Atrial fibrillation classically causes loss of the *a* wave and blunting of the *x* descent due to a loss of atrial relaxation. Answer: tracing E.

Tricuspid regurgitation presents as a large *v* wave, as blood flows into the atria during ventricular systole and atrial diastole. Answer: tracing C.

Tricuspid stenosis leads to an increase in the right atrial pressure with a prominent *a* wave that is consistent throughout the cardiac cycle. Answer: tracing A.

Case continued

In view of the information obtained from the patient's CVP tracing, his physicians suspect he has cardiac tamponade. His chronic renal failure and heparin use put him at risk for pericardial bleeding. Echocardiography reveals a pericardial effusion with features compatible with cardiac tamponade. Emergency pericardiocentesis is performed and reveals a bloody effusion. When the effusion is drained, the patient's blood pressure improves dramatically, and the vasopressor agents are discontinued. The *y* descent returns to normal on the CVP tracing (FIGURE 4).

■ HOW TAMPONADE DECREASES CARDIAC OUTPUT

Cardiac tamponade has many pathophysiologic effects that decrease systemic blood flow.³

Hemodynamic changes become apparent only after so much fluid has accumulated that the pericardial membrane can stretch no further.⁴ It can stretch more if the fluid accumulates slowly rather than rapidly.

When the pericardium cannot stretch, the heart must compete with the increased pericardial contents for the fixed intrapericardial volume.^{4,5} The intrapericardial pressure increases until it is the same as the right ventricular filling pressure. This can lead to a decrease in cardiac output, depending on the compensatory venous filling mechanisms. At this point, the arterial blood pressure declines sharply during inspiration, but usually not enough to qualify as pulsus paradoxus (ie, at least 10 mm Hg; see below).

FIGURE 3

Not available for online publication.

**See print version of the
*Cleveland Clinic
Journal of Medicine***

In severe tamponade, stroke volume and cardiac output can fall to nearly zero

The patient's tamponade resolves

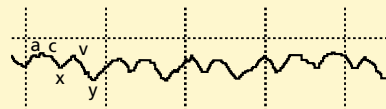


FIGURE 4

The function of one ventricle depends to some degree on the function of the other, a phenomenon called *ventricular interdependence*. An increase in pressure in one ventricle will cause an increase in pressure in the

TABLE 1

When to suspect tamponade as the cause of hypotension

Cardiac interventions

Aortic interventions, cardiac catheterization, open-heart surgery, pacemaker placement

Inflammatory conditions

Rheumatoid arthritis, systemic lupus erythematosus, Wegener granulomatosis

Malignancies

Hodgkin lymphoma, lung cancer, metastatic breast cancer

Metabolic disorders

Hypothyroidism, uremia

Myocardial infarction

With a ruptured ventricle

Trauma

Penetrating or blunt trauma to the chest or upper abdomen

The classic signs of tamponade (Beck triad): Distant heart sounds, Elevated jugular venous pressure, Hypotension

other ventricle. This relationship is exaggerated when pericardial and right-sided pressures are elevated.⁵

Squeezed by the excess fluid within the pericardium, the heart cannot receive as much blood during diastole or expel as much blood during systole. Ultimately, the pericardial and diastolic cardiac chamber pressures all equalize,^{6,7} leading to a further decline in cardiac output. With this, the decline in arterial blood pressure during inspiration usually reaches 10 mm Hg—true pulsus paradoxus. In severe cases of cardiac tamponade, the intrapericardial pressure may be high enough to cause the stroke volume and arterial pressure to fall to nearly zero.⁷

Suspect tamponade if the patient is in shock

Tamponade is a form of cardiogenic shock. Nonspecific symptoms such as dyspnea and chest pain are frequently reported. One should therefore keep this diagnosis in mind if certain types of patients develop hypotension (TABLE 1).⁸ The initial presentation may also include complications of a shock-like state, such as renal failure.⁹

Patients undergoing major cardiac surgery have an increased incidence of postoperative

cardiac tamponade, especially those receiving anticoagulation after valvular surgery.¹⁰ Physicians need to be especially suspicious of cardiac tamponade in such cases because stiffness of the postoperative myocardium, electrolyte and fluid imbalances, and postoperative bleeding tend to mask the classic presentation of cardiac tamponade.

Physical findings are often nonspecific

Physical findings in patients with cardiac tamponade are often nonspecific.⁹

The Beck triad of distant heart sounds, elevated jugular venous pressure, and hypotension are the classic signs. Heart sounds may be dampened by the pericardial fluid surrounding the heart. The precordium is often quiet except in patients with preexisting cardiomegaly, in whom an active precordium may be the rule.¹¹ The jugular veins are distended unless the patient has hypovolemia, and Kussmaul sign (lack of an inspiratory decline in jugular pressure) is seen in 26% of patients.⁹ Hypotension is the major consequence of clinically significant cardiac tamponade.

Tachycardia is almost universally present.

A triphasic pericardial rub may be present in patients with cardiac tamponade arising from pericarditis.¹²

Pulsus paradoxus is a more specific finding.¹¹ Defined as an inspiratory fall in systolic arterial pressure of 10 mm Hg or more during inspiration while the patient is breathing normally, it can be detected by palpating the peripheral pulses while measuring the blood pressure. An intra-arterial catheter may be required to detect pulsus paradoxus in severe cardiac tamponade, owing to the very low blood pressure.

Pulsus paradoxus is due to an increase in venous return to the right ventricle during inspiration, leading to a decrease in left ventricular chamber size. The forces responsible for this include bulging of the ventricular septum into the left ventricle and an increase in pericardial pressure on the free left ventricular wall.

Conditions other than pericardial tamponade that can cause pulsus paradoxus are massive pulmonary embolus, obstructive lung disease, and shock states. It can be masked by pericardial adhesions, right ventricular hypertrophy, and atrial septal defects.^{11,13–15}

Electrical alternans in pericardial tamponade

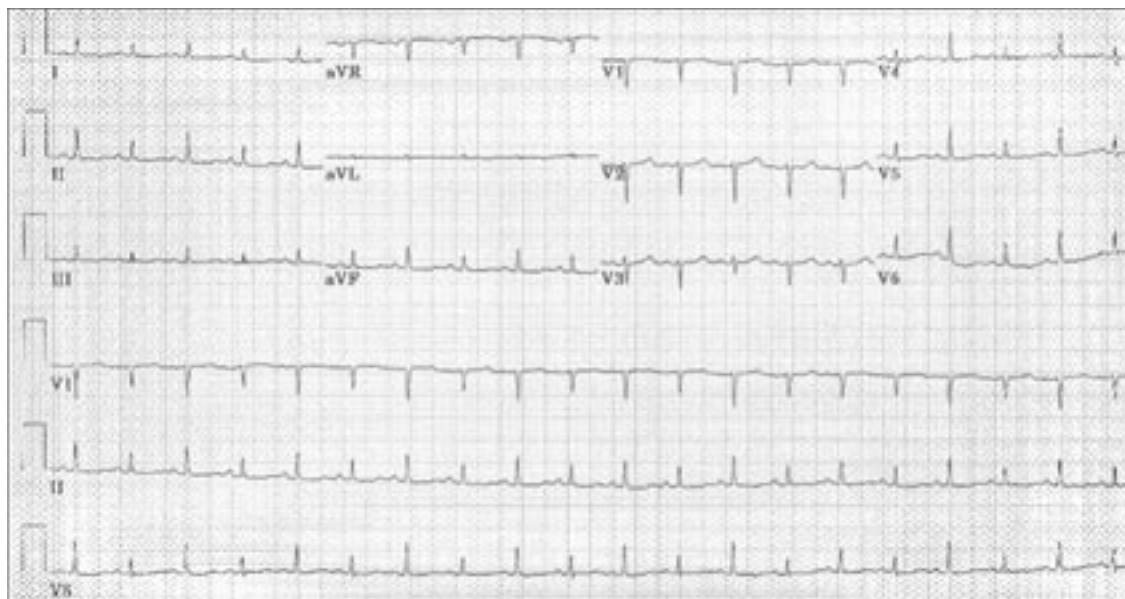

FIGURE 5. Electrocardiogram showing electrical alternans. The amplitude of the QRS complex alternates from beat to beat (especially visible in lead V₆).

Tests support the clinical diagnosis

The diagnosis of cardiac tamponade is made clinically, and diagnostic testing is used to confirm it.

Chest radiography is not sensitive at detecting pericardial effusions when the fluid accumulates slowly. At least 200 mL of fluid needs to accumulate before a change in the cardiac silhouette can be noticed.

Electrocardiography usually shows non-specific changes. Diffuse ST-segment elevation may be present if the tamponade was preceded by pericarditis. The only specific sign of cardiac tamponade on electrocardiography is electrical alternans,^{13,16} which can affect any or all of the waves (**FIGURE 5**). Total electrical alternation (electrical alternation involving both the P wave and the QRS complex) is very specific for cardiac tamponade.¹⁷

Echocardiography is the principal tool used to detect pericardial effusion and therefore may aid in the diagnosis of cardiac tamponade (**FIGURE 6**). Echocardiographic criteria of cardiac tamponade are based on altered ventricular or atrial wall motion, and on respiratory fluctuations of ventricular size and flow velocities.^{18,19} Left atrial wall collapse is a specific sign of cardiac tamponade.

Direct measurement of intracardiac

pressures in cardiac tamponade shows equilibration of diastolic pressures in all cardiac chambers. In addition, respiratory reciprocation of cardiac pressures may be seen—an inspiratory increase on the right and a concomitant decrease on the left. Although the central pressures are elevated in a fashion similar to that in left heart failure, there is no associated pulmonary edema due to low levels of atrial natriuretic factor.²⁰

Pericardiocentesis is the treatment of choice

Drainage of the pericardial contents by needle pericardiocentesis is the treatment of choice for cardiac tamponade.^{9,13} Surgical drainage is often necessary in cases of intrapericardial bleeding to evacuate a clotted hemopericardium.²¹ Cardiac tamponade due to uremia generally responds to renal replacement therapy via hemodialysis, but if hemodynamic compromise is present, drainage is required.¹¹

Recurrences, especially in patients with malignant cardiac tamponade, may require surgical creation of a pericardial window. This procedure provides immediate hemodynamic benefit, causes minimal surgical morbidity and mortality, and results in a lower incidence of recurrence compared with pericardiocentesis

Echocardiography is the principal tool to detect pericardial effusion

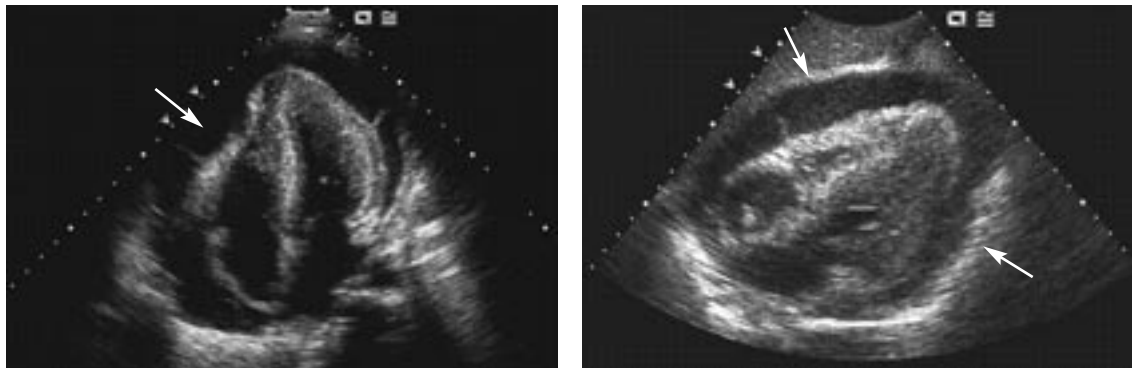


FIGURE 6. Echocardiographic four-chamber views show fluid in the pericardial space compressing the cardiac chambers.

and prolonged catheter drainage.²²

Medical treatment of acute cardiac tamponade is generally supportive. Volume expanders (eg, saline) and inotropic support may be beneficial only in hypovolemic patients. In other patients, a rapid increase in left ventricular volume in the presence of a pericardial effusion may increase intrapericardial fluid pressure enough to worsen right ventricular diastolic collapse and therefore accelerate the development of tamponade.^{9,23} Reversal of hypotension using dobutamine may be considered, although the endogenous inotropic stimulation of the heart is usually at maximal levels.²⁴

Special attention must be given to patients receiving mechanical ventilation with positive airway pressure, as this may further decrease cardiac output by reducing the compensatory venous filling pressures.⁹

Animal studies have shown benefits from using vasodilators with volume expanders to increase cardiac output and increase blood flow to the myocardium and kidneys.²³ Chronic opioid blockage with naloxone (Narcan) has been reported in ani-

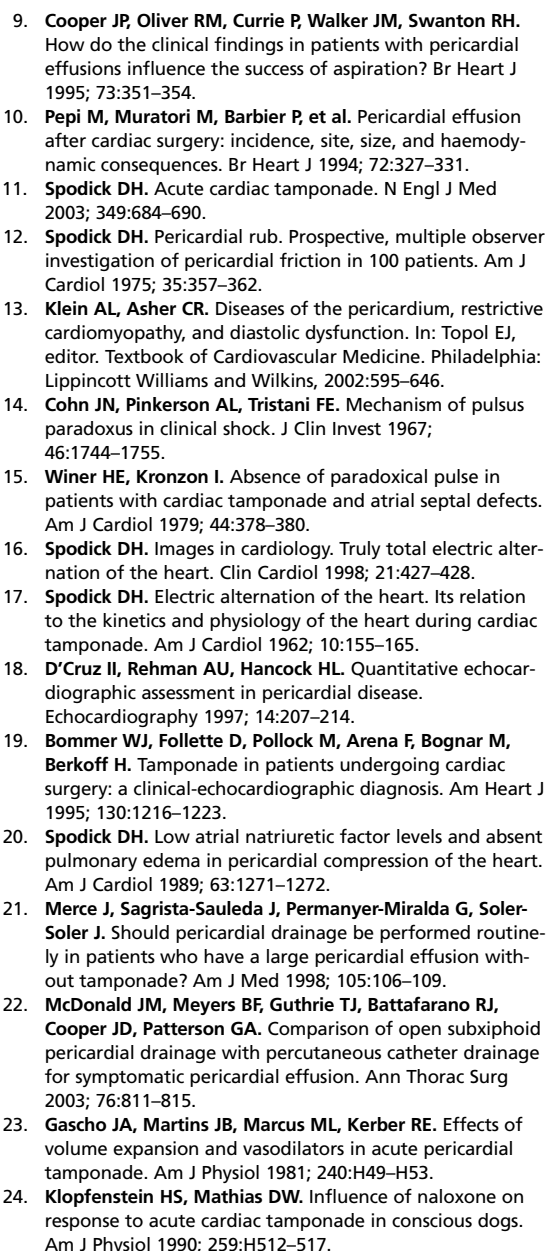
mal studies to increase mean arterial blood pressure with no change in heart rate, indicating an opioid mechanism as a contributor to the hypotension of cardiac tamponade.²⁴ We do not recommend using these interventions clinically, as they have not been studied in humans.

■ TAKE-HOME POINTS

- This case illustrates the need to consider cardiac tamponade as a cause of hypotension in the intensive care unit. As the symptoms are nonspecific, we must have a high suspicion in the correct setting.
- Time is of the essence. If one can recognize the classic signs of cardiac tamponade and confirm the clinical diagnosis with adjuvant testing when time permits, one can quickly perform life-saving drainage of the pericardial effusion.
- The CVP tracing is often readily available in the intensive care unit. Knowledge of characteristic CVP tracings of different diseases helps to expedite diagnostic and therapeutic decisions.

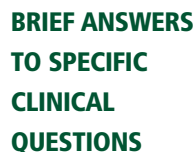
■ REFERENCES

1. Shabetai R. Pericardial disease. Etiology, pathophysiology, clinical recognition, and treatment. In: Willerson J, Cohn JN, editors. *Cardiovascular Medicine*, 2nd ed. New York: Churchill Livingstone, 2000:1245–1272.
2. O'Rourke RA, Braunwald E. Physical examination of the cardiovascular system. In: Braunwald E, Fauci AS, Kasper DL, Hauser SL, Longo DL, Jameson JL, editors. *Harrison's Principles of Internal Medicine*, 15th ed. New York: McGraw Hill, 2001:1255–1262.
3. Martins JB, Manuel WJ, Marcus ML, Kerber RE. Comparative effects of catecholamines in cardiac tamponade: experimental and clinical studies. *Am J Cardiol* 1980; 46:59–66.
4. Spodick DH. Threshold of pericardial constraint: the pericardial reserve volume and auxiliary pericardial functions. *J Am Coll Cardiol* 1985; 6:296–297.
5. Santamore WP, Li KS, Nakamoto T, Johnston WE. Effects of increased pericardial pressure on the coupling between the ventricles. *Cardiovasc Res* 1990; 24:768–776.
6. Braunwald E, Zipes DP, Libby P, editors. *Heart Disease: A Textbook of Cardiovascular Medicine*, 6th ed. Philadelphia: Saunders, 2001:1823–1876.
7. Reddy PS, Curtiss EI, Uretsky BF. Spectrum of hemodynamic changes in cardiac tamponade. *Am J Cardiol* 1990; 66:1487–1491.
8. Hashim R, Frankel H, Tandon M, Rabinovici R. Fluid resuscitation-induced cardiac tamponade. *J Trauma* 2002; 53:1183–1184.



9. **Cooper JP, Oliver RM, Currie P, Walker JM, Swanton RH.** How do the clinical findings in patients with pericardial effusions influence the success of aspiration? *Br Heart J* 1995; 73:351-354.
10. **Pepi M, Muratori M, Barbier P, et al.** Pericardial effusion after cardiac surgery: incidence, site, size, and haemodynamic consequences. *Br Heart J* 1994; 72:327-331.
11. **Spodick DH.** Acute cardiac tamponade. *N Engl J Med* 2003; 349:684-690.
12. **Spodick DH.** Pericardial rub. Prospective, multiple observer investigation of pericardial friction in 100 patients. *Am J Cardiol* 1975; 35:357-362.
13. **Klein AL, Asher CR.** Diseases of the pericardium, restrictive cardiomyopathy, and diastolic dysfunction. In: Topol EJ, editor. *Textbook of Cardiovascular Medicine*. Philadelphia: Lippincott Williams and Wilkins, 2002:595-646.
14. **Cohn JN, Pinkerson AL, Tristani FE.** Mechanism of pulsus paradoxus in clinical shock. *J Clin Invest* 1967; 46:1744-1755.
15. **Winer HE, Kronzon I.** Absence of paradoxical pulse in patients with cardiac tamponade and atrial septal defects. *Am J Cardiol* 1979; 44:378-380.
16. **Spodick DH.** Images in cardiology. Truly total electric alternation of the heart. *Clin Cardiol* 1998; 21:427-428.
17. **Spodick DH.** Electric alternation of the heart. Its relation to the kinetics and physiology of the heart during cardiac tamponade. *Am J Cardiol* 1962; 10:155-165.
18. **D'Cruz II, Rehman AU, Hancock HL.** Quantitative echocardiographic assessment in pericardial disease. *Echocardiography* 1997; 14:207-214.
19. **Bommer WJ, Follette D, Pollock M, Arena F, Bogner M, Berkoff H.** Tamponade in patients undergoing cardiac surgery: a clinical-echocardiographic diagnosis. *Am Heart J* 1995; 130:1216-1223.
20. **Spodick DH.** Low atrial natriuretic factor levels and absent pulmonary edema in pericardial compression of the heart. *Am J Cardiol* 1989; 63:1271-1272.
21. **Merce J, Sagrista-Sauleda J, Permanyer-Miralda G, Soler-Soler J.** Should pericardial drainage be performed routinely in patients who have a large pericardial effusion without tamponade? *Am J Med* 1998; 105:106-109.
22. **McDonald JM, Meyers BF, Guthrie TJ, Battafarano RJ, Cooper JD, Patterson GA.** Comparison of open subxiphoid pericardial drainage with percutaneous catheter drainage for symptomatic pericardial effusion. *Ann Thorac Surg* 2003; 76:811-815.
23. **Gascho JA, Martins JB, Marcus ML, Kerber RE.** Effects of volume expansion and vasodilators in acute pericardial tamponade. *Am J Physiol* 1981; 240:H49-H53.
24. **Klopfenstein HS, Mathias DW.** Influence of naloxone on response to acute cardiac tamponade in conscious dogs. *Am J Physiol* 1990; 259:H512-517.

ADDRESS: Peter Mazzone, MD, MPH, Department of Pulmonary, Allergy, and Critical Care Medicine, A90, Cleveland Clinic, 9500 Euclid Avenue, Cleveland, OH 44195; e-mail mazzonep@ccf.org.



We want to know what questions you want addressed in **"1-Minute Consult."** All questions should be on practical, clinical topics. You may submit questions by mail, phone, or e-mail.

PLEASE PRINT CLEARLY

Q:

Cleveland Clinic Journal of Medicine,
9500 Euclid Ave., NA32, Cleveland, OH 44195
PHONE 216•444•2661 FAX 216•444•9385
E-MAIL ccjm@ccf.org