

**STEPHEN H. SINCLAIR, MD***

Department of Ophthalmology, Crozer Chester Medical Center, Hahnemann University, Philadelphia, PA

CHERIE DELVECCHIO, BS

Pennsylvania College of Optometry, Elkins Park

The internist's role in managing diabetic retinopathy: Screening for early detection

ABSTRACT

Although laser treatment keeps vision damaged by diabetic retinopathy from becoming worse, it only rarely improves vision. If primary care physicians wait until the patient complains of blurred vision, it is too late—there is already permanent retinal injury, and the lost vision almost never can be restored. Unfortunately, only half of patients with diabetes undergo an appropriate examination every year. Only by teamwork between primary care physician and ophthalmologist can blindness from diabetic retinopathy be reduced.

KEY POINTS

Instead of simply telling the patient to get an eye examination, the internist should make the referral, write a letter to the ophthalmologist, and expect a report in return.

Strict control of blood sugar levels reduces the incidence of diabetic retinopathy by about 35% for every 1% absolute decrement in hemoglobin A_{1c}. Still, more than 80% of diabetic patients eventually develop some degree of retinopathy.

Laser treatment and surgery can usually arrest the progression of retinopathy but usually cannot restore lost vision.

Retinal photography holds promise for screening: photographs can be taken by trained personnel (not necessarily a physician) in the internist's office, with or without pupil dilation, and analyzed by computer algorithms or an eye care provider at a later date.

TO PREVENT BLINDNESS in their patients with diabetes, primary care physicians need to take a more active role in overseeing and managing their ophthalmic care—in particular, making sure that every patient with diabetes receives an eye examination with pupil dilation to screen for retinopathy at least once a year.

See related editorial, page 81

Diabetic retinopathy remains the number-one cause of blindness in the developed world. Treatments can arrest its development but not restore lost vision. Fortunately, screening examinations can detect it in its early clinical stages. Yet only about half of patients with diabetes actually receive this recommended examination.

In this article we outline the case for eye screening and recommend ways that primary care physicians can help.

HOW SUGAR DAMAGES THE EYE

Diabetic retinopathy begins with hyperglycemia, but how sugar causes the characteristic occlusion and leakage of the small vessels in the retina, with resulting progressive vision loss, is still largely unknown.¹

Capillary occlusion. One intriguing hypothesis is that, in the small arteries of target organs, hyperglycemia activates white

*Dr. Sinclair has indicated that he is a stock shareholder in Philadelphia Ophthalmic Imaging Systems.

Diabetic retinopathy

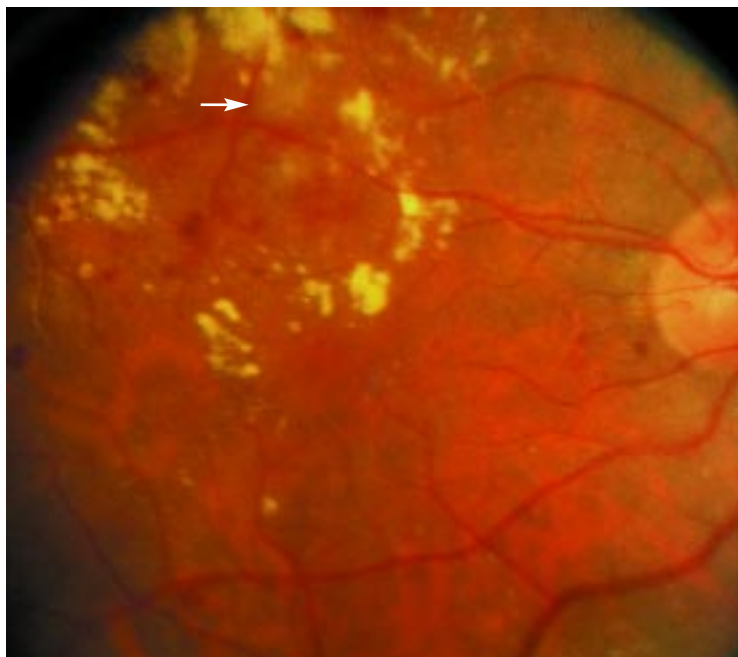


FIGURE 1. Right eye; diabetic background retinopathy with a “cotton wool” infarct (arrow) in the center of a ring of lipid exudates. The exudates and edema extend inferiorly into the macula.

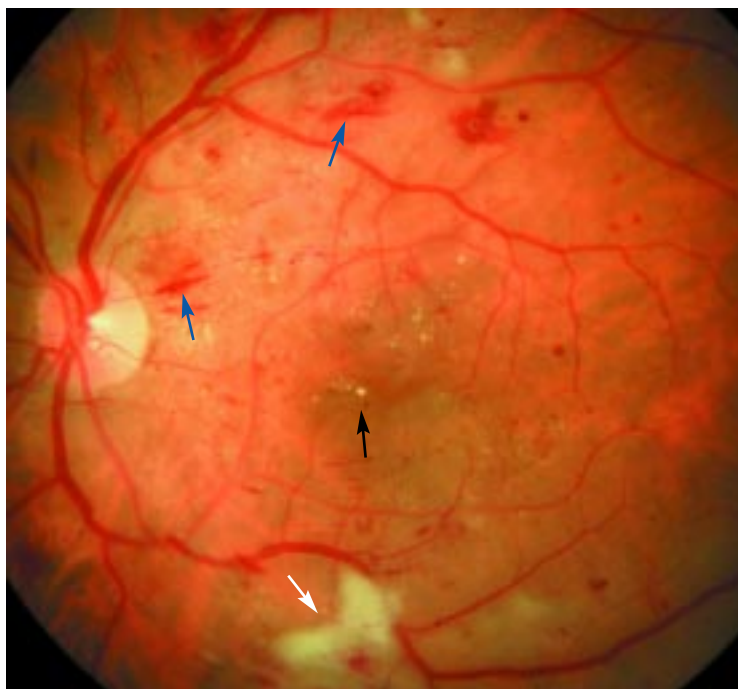


FIGURE 2. Left eye; nonproliferative retinopathy with hypertensive changes of striate hemorrhages (blue arrows), nerve-fiber layer cotton wool infarcts (white arrow), and diffuse macular edema with lipid exudates (black arrow).

blood cells, making them stiffer² and more resistant to flow.^{3,4} In addition, the white blood cells express more molecules on their surfaces called integrins, notably CD11a, CD11b, and CD18, and capillary endothelial cells express intercellular adhesion molecules (ICAMs); the two types of molecules stick together like Velcro, and the white blood cells adhere to the capillary wall.

Owing to these effects, the white blood cells cannot pass through the capillaries of target organs as easily as they should. Ultimately, the capillaries become plugged, and progressively larger areas of the retina are deprived of perfusion.^{5,6}

In the early stages of capillary occlusion, the surrounding capillaries compensate by accepting more flow, but as more capillaries and even arterioles are occluded, this autoregulation fails, and wider areas of the retina become ischemic.^{7,8}

Leakage, edema, exudates. When white blood cells adhere to the endothelium, they release products that make it more permeable.⁶ Furthermore, in response to ischemia, the vascular endothelium increases its production of various compensatory factors, most notably vascular endothelial growth factor (VEGF),^{9,10} a potent enhancer of permeability.

With the endothelium more permeable, more fluid leaks into the retina, resulting in tissue edema.¹¹ Exudates of edematous fluid and cholesterol accumulate in the retina (**FIGURE 1**, **FIGURE 2**), causing opacification and swelling and impairing vision resolution and contrast sensitivity.

Neovascularization. VEGF also stimulates new blood vessels to grow in the nonperfused areas, a process called neovascularization.¹² However, for reasons unknown, the new vessels grow in the wrong plane, between the internal surface of the retina and the vitreous gel (**FIGURE 3**).

Fibrosis. Along with the new vessels, fibrous tissue proliferates, producing local and then more widespread gel retraction that can tear the new vessels, causing bleeding between the gel and retina. The bleeding causes “floaters,” or, if more severe, it causes more diffuse loss of vision. Ultimately, the hemorrhage stimulates more fibrous tissue. As the fibrous tissue contracts, it pulls on the retina, distort-

ing and detaching it, both of which can cause severe vision loss.

■ TREATMENT HALTS RETINOPATHY, BUT CANNOT RESTORE VISION

Treatments for diabetic retinopathy are either local or systemic.

Local treatments: Laser and surgery

Focal laser treatment. If there is edema in the macula or the central fovea, where it threatens central vision, one must first identify the leaking microvascular lesions by injecting sodium fluorescein (a fluorescent dye) intravenously and photographing its transit through the retinal vessels.

Treatment consists primarily of fine laser cauterization, targeting the specific microvessels that are leaking, which may be few and focal if discovered in the early stages.

In a multicenter study,¹³ such laser treatment reduced edema and, in 50% of cases, prevented significant loss of central vision. Rarely, however, does it improve vision. Moreover, laser treatment can scar the retina around the fovea and damage periaxial vision.¹⁴ Therefore, laser treatment is most effective when the macular edema is discovered early, when vision impairment is still minimal and the areas of leakage are fewer and more focal.

Scatter laser treatment. If there is neovascularization, the areas of peripheral capillary nonperfusion are identified using the same intravenous fluorescein angiographic procedure and are treated with a scatter method of laser treatment (panretinal photocoagulation).

This procedure indirectly causes involution and fibrosis of the neovascularization, reducing the risk of severe hemorrhage or traction detachment by 60%.¹⁵ The apparent mechanism by which laser treatment reduces edema and neovascularization is thought to be by decreasing production of VEGF and by down-regulating VEGF receptors.^{9,12}

Surgery. If neovascularization is discovered late, when there is serious hemorrhage, fibrous tissue growth, or distortion or detachment of the retina, then the patient must undergo a surgical procedure called pars plana vitrectomy.

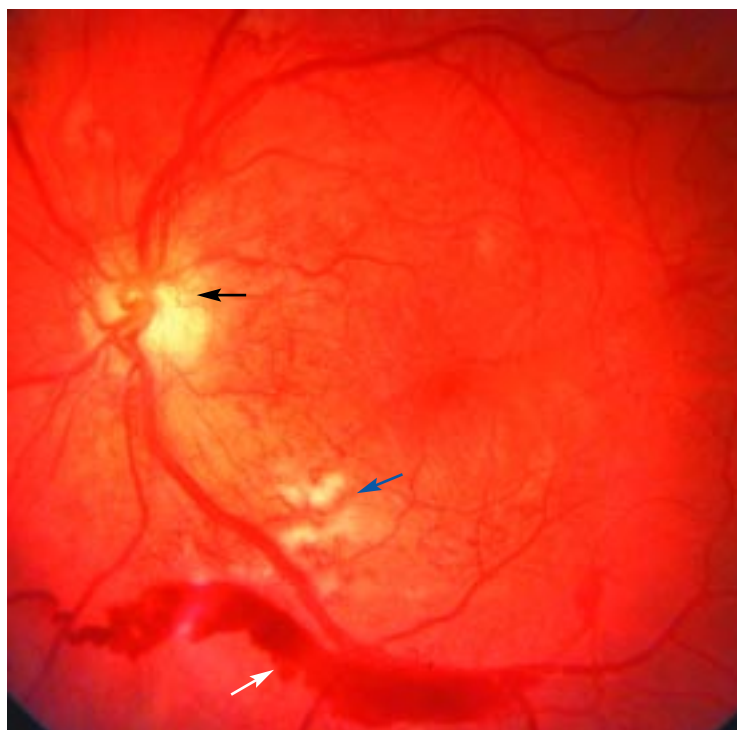


FIGURE 3. Left eye; proliferative retinopathy with disc neovascularization (black arrow), cotton wool infarcts (blue arrow), and intraretinal microvascular abnormalities. The neovascularization has caused a vitreous hemorrhage (white arrow), that is layered between the gel and retina in the lower part of the photograph.

In this procedure the gel is removed and the fibrous tissue carefully excised from the surface of the retina.^{16,17} During the surgery, additional scatter laser treatment is often given to reduce tissue ischemia, especially if laser treatment has not been given earlier.

More recently, vitrectomy has been performed for cases of edema in which the leakage is more widespread or unresponsive to focal laser treatments.^{18–20}

During vitrectomy, steroids may be injected to assist in resolving the macular edema, or an intraocular device may be inserted that slowly releases angiostatic steroids, currently under investigation for the treatment of macular edema.^{21,22}

Systemic treatments: Correcting hyperglycemia

Systemic factors that exacerbate the course of diabetic retinopathy include hyperglycemia, hypertension, hyperlipidemia, anemia, obstructive sleep apnea, and smoking. We will

discuss hyperglycemia here; the other factors will be the topic of a paper to follow.

Tight control of blood sugar has been the standard of care since it was shown to reduce the incidence of retinopathy in insulin-dependent diabetes in the DCCT (Diabetes Control and Complications Trial)²³ and in non-insulin-dependent diabetes in the UKPDS (United Kingdom Prospective Diabetes Study).²⁴ In both studies, for every decrease in hemoglobin A_{1c} of 1 absolute percentage point, the incidences of both the onset of retinopathy and of significant progression decreased by approximately 35%.

Nevertheless, even now, more than 80% of people with type 2 diabetes and 97% of those with type 1 diabetes still develop some degree of retinopathy within 15 years, and 40% develop proliferative retinopathy.^{25,26}

Numerous drugs have been tested to determine if they prevent the microvascular complications of hyperglycemia. Unfortunately, clinical studies of aldose reductase inhibitors,^{27,28} aminoguanidine,²⁹ and histamine blockers were unsuccessful. Clinical trials of protein kinase C inhibitors are in progress.³⁰

Although some new devices (eg, noninvasive monitors and closed-loop insulin delivery systems) and drugs (eg, metformin to manage insulin resistance) may help improve glucose control, it is doubtful that the prevalence of retinopathy or the rate of its progression will be stemmed, given the rising tide of diabetes prevalence.³¹

■ THE CASE FOR RETINOPATHY SCREENING

Even though laser and surgical treatment can reduce severe vision loss by up to 94%, diabetic retinopathy remains the leading cause of blindness in the developed world.³² It is the major cause of new blindness, the leading cause of blindness among working-age people (ages 25 to 74),^{26,33} and a major cause of prolonged disability. Furthermore, these depressing statistics have not improved in the last 10 years.

The problem is that although laser treatment prevents damaged vision from getting worse, it only rarely improves vision.¹³ If we wait until the patient complains of blurred

vision, it is too late—there is already permanent retinal injury, and the lost vision almost never can be restored.

Therefore, retinopathy demands a new standard of care: regular screening of people without symptoms.³⁴ In communities in which intensive retinopathy screening programs have been implemented, rates of vision loss have decreased.^{35,36} In view of these successes, the American Diabetes Association,³⁷ the American Academy of Ophthalmology,³⁸ the American Academy of Optometry,³⁹ and the Centers for Disease Control and Prevention recommend that all people with diabetes undergo a retinal examination with dilated pupils once a year to detect the first onset of retinopathy, and more frequently once lesions are detected.

Screening should begin in patients with type 2 diabetes shortly after the time of diagnosis and in those with type 1 approximately 3 to 5 years after diagnosis.

■ BARRIERS TO RETINOPATHY SCREENING

Patient misunderstanding, noncompliance

At present, only 35% to 55% of people with diabetes actually get an examination of the retina with pupil dilation every year.^{40–45} The rate appears lower among people with type 2 diabetes,⁴⁰ but does not vary with socioeconomic or educational level or type of insurance.^{41,46}

Why is the rate so low? Perhaps physicians are not talking to their patients about eye care and are not making the referrals.^{40,47–49} They may not have time for it, given the many other health problems of patients with diabetes. Overwhelmingly, however, the problem appears to be due to patient misunderstanding and noncompliance.

Although most diabetic patients believe that yearly eye examinations are needed,⁴⁰ many do not follow through with scheduling, for several reasons.

- **Fear of discovering something bad** was commonly reported in a survey of diabetic patients.⁵⁰ Although patients may be aware that retinopathy can have severe consequences, as long as they perceive no visual problems, they do not personalize this information.

Factors that worsen retinopathy:
Hyperglycemia
Hypertension
Hyperlipidemia
Anemia
Sleep apnea
Smoking



- **Reluctance to make yet another appointment.** An eye examination, in which the pupils are dilated, can cost a day lost from work.

- **Mixed signals from physicians.** Many patients report that their physicians advised them to get annual examinations, but they were also told that they could avoid complications if they controlled their blood sugar better. Then if the physician does not continually admonish his or her patients about their blood sugar control, the patients interpret this as meaning they are “doing all right” and therefore are not at risk of developing retinopathy, and so they may skip the examination.

In one study, the compliance rate increased significantly after patients participated in a blindness-prevention program, but whether this behavior persists is unknown.⁵¹

Poor physician communication

A second cause of the low rate of screening is poor communication among physicians.

After the internist advises the patient about the eye examination, he or she then assumes it is the patient’s responsibility to follow through and “comply.” Often, the internist does not know the name of the eye doctor, and few internists routinely write a letter to the eye doctor with the reasons for the requested examination, the patient’s hemoglobin A_{1c} level, or other information such as comorbidities.

Therefore, even when patients do schedule an eye appointment, very often the optometrist or ophthalmologist does not know the reason for the visit, may take only a cursory history, and may not perform the necessary dilated-pupil examination.

Although some eye care providers send the internist a report, rarely do they communicate when a patient fails to come in for an examination. Furthermore, when internists do receive a report about the examination, they often find that it contains ophthalmic language that they do not understand.

■ SHOULD PRIMARY CARE PHYSICIANS PERFORM RETINAL SCREENING?

Whether primary care physicians should screen for retinopathy is controversial.⁴⁹

However, the only medical systems in which the retinal examination rates exceed 80% to 85% are those in which screening is provided in the primary care setting (most often by photography; Kaiser Permanente, Joslin Clinic, Louisiana State University, personal communication).³⁴

Do internists do a good job of screening?

Although internists look at the retinal fundi in up to half of their diabetic patients,⁴⁷ they generally do not dilate the pupils, and therefore most often do an inadequate examination.^{47,48} When asked why they did not dilate the pupils, internists mentioned fear of inducing angle-closure glaucoma, the length of time required, and resulting complaints from patients.⁵²

How real are these concerns? Millstein et al⁵³ calculated that angle-closure glaucoma was induced in only 1 in 20,000 dilated-pupil examinations, and suggested a simple test to identify people who have a convex iris plane and are at increased risk and should not undergo pupil dilation: shine a flashlight sideways from the lateral side of the eye across the anterior segment. If the iris plane is convex, the nasal side of the iris will be in shadow.

Although time may be a deterrent in a busy internist’s schedule, adequate pupil dilation actually takes less than 15 minutes.⁵³ Patients say that, indeed, pupil dilation does alter their daily schedule more than office visits that do not involve pupil dilation,⁵² but for the most part patients still accomplish necessary tasks. If they are forewarned that their pupils will be dilated, they bring sunglasses, and rather than complain, they appreciate the better care and attention.⁵²

Even with pupil dilation, however, can internists recognize diabetic lesions with sufficient accuracy? Sussman et al⁵⁴ found that internists, diabetologists, and medical residents, examining the fundi of diabetic patients with pupils dilated, correctly identified fewer than 60% of the more significant lesions, whereas ophthalmologists and retinal specialists identified more than 96%.

This is understandable, considering that the median exposure to ophthalmic disease in medical school was less than 15 hours in 1979, and has continued to decline.⁵⁵ Residency

If we wait for blurred vision to develop, it is too late

programs in internal medicine or family practice do not usually emphasize ophthalmoscopy, either. In an eloquent editorial, Wender⁴⁹ questions the ability of practitioners to maintain adequate skills when they rarely perform this procedure.

Retinal photography shows promise

Retinal photography appears promising as a screening method in the primary care setting.⁵⁶ In this method, a trained photographer, nurse, or other health worker takes pictures of the retina, which an ophthalmologist may analyze later or, in some systems (undergoing evaluations), which may be analyzed by computer algorithms.

With pupil dilation, retinal photography, performed in a systematic manner by a trained photographer, has been demonstrated to be superior to direct examination in identifying retinopathy lesions.⁵⁷ Even without pupil dilation, early studies suggest that this procedure, performed with a special nonmydriatic camera, may offer a viable and even preferable method for detecting retinopathy in primary care settings.^{58–61}

However, the quality of the images and the derived sensitivity and specificity of the detection methods are yet to be determined in studies of large numbers of patients. Until then, retinal photography must be considered investigational and unproven.⁶²

■ TEAMWORK IS NEEDED

Only by teamwork among health care professionals can blindness from diabetic retinopathy be significantly reduced. We offer the following recommendations.

The primary care physician's job

We propose that, in patients with diabetes, it is the responsibility of the primary care physician to:

- Optimize glycemic control (goal hemoglobin A_{1c} level < 7%)³⁷
- Aggressively manage other risk factors for retinopathy, eg, hypertension, hyperlipidemia, anemia, obstructive sleep apnea, and smoking
- Make sure all patients with diabetes (type 2 as well as type 1) receive an annual retinal examination with pupil dilation or retinal

photography, no matter how good their vision seems—and if the hemoglobin A_{1c} level is more than 12%, we strongly recommend an examination every 6 months. To improve patient compliance, physicians need to:

- Educate their diabetic patients about the importance of getting an annual eye examination
- Either make the appointment for the patient or give the patient a note with the eye care provider's name and telephone number
- Communicate to the eye care provider the reason for the visit (ie, for a dilated ophthalmic examination), the hemoglobin A_{1c} level, and the presence of any other comorbid conditions (perhaps by faxing a form such as in **FIGURE 4**)
- If an eye doctor is not available, examine the retina, but only with pupil dilation and with adequate training. However, if there are referred eye physicians available, we recommend that primary physicians do not examine the fundi (without pupil dilation), as this gives the wrong message to the patient.
- Expect a letter from the eye care physician regarding whether the patient was seen, the status of the retinopathy, and recommendations for follow-up. If such a letter is not received within a reasonable time (2–3 months), it is the primary care physician's responsibility to communicate with the patient and with the eye care provider.
- Reinforce any recommendations for follow-up care established by the eye care provider and be knowledgeably abreast of the treatment and results.

Diabetes educators can help

We recognize that these responsibilities place an additional burden on internists, who already have a multitude of recommendations to follow from multiple organizations about preventing different diseases.⁴⁹

As medicine becomes more complex, physicians are expected to do more and more. The only way they can do it all is by delegating work to others, whom they supervise. For example, in diabetes, many educational and ancillary services are being performed by diabetes educators located in central facilities that serve multiple physicians, capitalizing on

A team approach can significantly reduce blindness from diabetic retinopathy



Request for screening for diabetic retinopathy

Date: _____

Dear Dr. _____

Mr./ Mrs. _____ has been referred to you for a dilated retinal examination to evaluate for diabetic retinopathy.

The most recent hemoglobin A_{1c} was _____%.

Additional comorbid conditions include:

- ☐ Hypertension
- ☐ Hyperlipidemia
- ☐ Nephropathy
- ☐ Anemia
- ☐ Obstructive sleep apnea
- ☐ Smoking

Would you please be so kind as to communicate the results of your examination with specific regard to the absence or presence of retinopathy and your findings, along with the recommendations for follow-up. You may do this either by faxing this convenient form to #_____, by mailing the form, or by sending a letter. If the patient fails to make the scheduled appointment, please also notify this office.

Thanking you in advance for your assistance on behalf of our patient,

Sincerely yours,

Results of examination

Date of examination _____

☐ Patient did not appear for scheduled examination

Retinal findings on examination with pupil dilation:

Right eye: ☐ No retinopathy
☐ Retinopathy:

Left eye: ☐ No retinopathy
☐ Retinopathy:

Recommendations:

Name

Signature

FIGURE 4

economies of scale. Many diabetes educators now talk about ophthalmic care, and may facilitate the eye care provider's appointment and follow-up. It remains the primary care physician's responsibility, however, to make sure that services are provided and a report is generated.

To remind practitioners and patients what to do, it is helpful to use flow charts and computer-based or paper-based management processes.^{63–65} In addition, the problem of diabetic retinopathy calls for programs to promote physician communication, public awareness and education, and insurance payer education.

The eye care physician's job

If an eye care physician provides the services, it is his or her responsibility to:

- Understand the reasons for the visit and to perform the necessary funduscopy with pupil dilation
- Generate a report that is returned to the primary care physician, which provides, in readable format, the results of the examination and the appropriate recommendations for follow-up given the duration of diabetes, the retinopathy grade, the level of hemoglobin A_{1c}, and the existence of other comorbid conditions
- If the patient does not present for a scheduled examination, inform the internist, contact the patient and reinforce the reason for the examination, and make sure that an appointment is rescheduled (perhaps using a form such as in **FIGURE 4**).



REFERENCES

1. Aiello L, Gardner T, King G, et al. Diabetic retinopathy. Technical review. *Diabetes Care* 1998; 21:143–156.
2. Masuda M, Murakami T, Egawa H, Murata K. Decreased fluidity of polymorphonuclear leukocyte membrane in streptozocin-induced diabetic rats. *Diabetes* 1990; 39:466–470.
3. Bohlen H, Hankins K. Early arteriolar and capillary changes in streptozotocin-induced diabetic rats and intraperitoneal hyperglycaemic rats. *Diabetologia* 1982; 22:344–348.
4. Wierusz-Wysocka B, Wysocki H, Siekierka H, et al. Evidence of polymorphonuclear neutrophils activation (PMN) in patients with insulin-dependent diabetes mellitus. *J Leukocyte Biol* 1987; 47:519–523.
5. Schroder S, Palinski W, Schmid-Schonbein G. Activated monocytes and granulocytes, capillary nonperfusion, and neovascularization in diabetic retinopathy. *Am J Pathol* 1991; 139:81–100.
6. Barouch F, Miyamoto K, Allport J, et al. Integrin-mediated neutrophil adhesion and retinal leukostasis in diabetes. *Invest Ophthalmol Vis Sci* 2000; 41:1153–1158.
7. Sinclair S. Macular retinal capillary hemodynamics in diabetic patients. *Ophthalmology* 1991; 98:1580–1586.
8. Grunwald J, Riva C, Brucker J, et al. Retinal blood flow in diabetes mellitus. *Ophthalmology* 1986; 93:590–595.
9. Boulton M, Foreman D, Williams G, McLeod D. VEGF localization in diabetic retinopathy. *Br J Ophthalmol* 1998; 82:561–568.
10. Miyamoto K, Khosrof S, Bursell S, et al. Vascular endothelial growth factor (VEGF)-induced retinal vascular permeability is mediated by intercellular adhesion molecule-1 (ICAM-1). *Am J Pathol* 2000; 156:1733–1739.
11. Funatsu H, Yamashita H, Ikeda T, et al. Angiotensin II and vascular endothelial growth factor in the vitreous fluid of patients with diabetic macular edema and other retinal disorders. *Am J Ophthalmol* 2002; 133:537–543.
12. Benjamin L. Glucose, VEGF-A, and diabetic complications. *Am J Pathol* 2001; 158:1181–1184.
13. Early Treatment Diabetic Retinopathy Study Research Group. Photocoagulation for diabetic macular edema. Early Treatment Diabetic Retinopathy Study Report Number 1. *Arch Ophthalmol* 1985; 103:1796–1806.
14. Sinclair SH, Alaniz R, Presti P. Laser treatment of diabetic macular edema: comparison of ETDRS-level treatment with threshold-level treatment by using high-contrast discriminant central visual field testing. *Semin Ophthalmol* 1999; 14:214–222.
15. Diabetic Retinopathy Study Research Group. Photocoagulation treatment of proliferative diabetic retinopathy. Clinical application of Diabetic Retinopathy Study (DRS) findings, DRS report number 8. *Ophthalmology* 1981; 88:583–600.
16. Diabetic Retinopathy Vitrectomy Study Research Group. Early vitrectomy for severe vitreous hemorrhage in diabetic retinopathy: four-year results of a randomized trial: diabetic retinopathy study report 5. *Arch Ophthalmol* 1990; 108:958–964.
17. Diabetic Retinopathy Vitrectomy Study Research Group. Early vitrectomy for severe proliferative diabetic retinopathy in eyes with useful vision. Results of a randomized trial. DRVS report no. 3. *Ophthalmology* 1988; 95:1307–1320.
18. Gandorfer A, Messmer EM, Ulbig MW, Kampik A. Resolution of diabetic macular edema after surgical removal of the posterior hyaloid and the inner limiting membrane. *Retina* 2000; 20:126–133.
19. Giovannini A, Amato G, Mariotti C, Scassellati-Sforzolini B. Optical coherence tomography findings in diabetic macular edema before and after vitrectomy. *Ophthalmic Surg Lasers* 2000; 31:187–191.
20. Yang CM. Surgical treatment for severe diabetic macular edema with massive hard exudates. *Retina* 2000; 20:121–125.
21. Jaffe GJ, Yang CH, Guo H, Denny JP, Lima C, Ashton P. Safety and pharmacokinetics of an intraocular fluocinolone acetonide sustained delivery device. *Invest Ophthalmol Vis Sci* 2000; 41:3569–3575.
22. Jaffe G, Ashton P. A multicenter, randomized, masked, controlled study to evaluate Retisert, an intravitreal fluocinolone acetonide implant, in the treatment of patients with diabetic macular edema. *Control Delivery Systems*, 2001; v. 2001.
23. Diabetes Control and Complications Trial Research Group (DCCT). The effect of intensive treatment of diabetes on the development and progression of long-term complications in insulin-dependent diabetes mellitus. *N Engl J Med* 1993; 329:977–986.
24. United Kingdom Prospective Diabetes Study (UKPDS) Group. Intensive blood-glucose control with sulphonylureas or insulin compared with conventional treatment and risk of complications in patients with type 2 diabetes (UKPDS 33). *Lancet* 1998; 352:837–853.
25. Klein R, Moss S, Klein B. New management concepts for timely diagnosis of diabetic retinopathy treatable by photocoagulation. *Diabetes Care* 1987; 10:633–638.
26. Klein R, Klein B. Vision disorders in diabetes. In: Group NDD, editor. *Diabetes in America*, 2nd ed. Bethesda, Md.: National Institutes of Health, National Institute of Diabetes and Digestive and Kidney Disease, 1995; v. NIH publication 95-1468.
27. Sorbinil Retinopathy Trial Research Group. A randomized trial of sorbinil, an aldose reductase inhibitor in diabetic retinopathy. *Arch Ophthalmol* 1990; 108:1234–1244.
28. Tromp A, Hooymans J, Barendsen B, van Doormaal J. The effects of an aldose reductase inhibitor on the progression of diabetic



- retinopathy. *Doc Ophthalmol* 1991; 78:153–159.
29. Boel E, Selmer J, Flodgaard HJ, Jensen T. Diabetic late complications: will aldose reductase inhibitors or inhibitors of advanced glycosylation endproduct formation hold promise? *J Diabetes Complications* 1995; 9:104–129.
 30. Frank R. Potential new medical therapies for diabetic retinopathy: protein kinase C inhibitors. *Am J Ophthalmol* 2002; 133:693–698.
 31. Mokhad AH, Ford ES, Bowman BA, et al. Diabetes trends in the U.S.: 1990–1998. *Diabetes Care* 2000; 23:1278–1283.
 32. American Diabetes Association. Implications of the diabetes control and complications trial. *Clin Diabetes* 1993; 11:91–96.
 33. Williams R. Diabetes mellitus. In: Stevens A, Raftery J, editors. *Health Care Needs Assessment*. New York: Oxford University Press, 1994.
 34. Klein R. Barriers to prevention of vision loss caused by diabetic retinopathy [editorial]. *Arch Ophthalmol* 1997; 115:1073–1074.
 35. Agardh E, Arardh C-D, Hansson-Lundblad C. The 5-year incidence of blindness after introducing a screening programme for early detection of treatable diabetic retinopathy. *Diabet Med* 1993; 10:555–559.
 36. Porta M, Tomalino MG, Santoro F, et al. Diabetic retinopathy as a cause of blindness in the province of Turin, north-west Italy, in 1967–1991. *Diabet Med* 1995; 12:355–361.
 37. American Diabetes Association. Standards of medical care for patients with diabetes mellitus. *Diabetes Care* 1994; 17:616–623.
 38. American Academy of Ophthalmology. *Diabetic Retinopathy: Preferred Practice Pattern*. San Francisco, Calif, 1989.
 39. American Optometric Association. *Guidelines for Optometric Care of Patients with Diabetes Mellitus*. St Louis, 1994.
 40. Schoenfeld E, Greene JM, Wu SY, Leske C. Patterns of adherence to diabetes vision care guidelines: baseline findings from the Diabetic Retinopathy Awareness Program. *Ophthalmology* 2001; 108:563–571.
 41. Brechner R, Cowie C, Howie L, et al. Ophthalmic examination among adults with diagnosed diabetes mellitus. *JAMA* 1993; 270:1714–1718.
 42. Weiner J, Parente S, Garnick D, et al. Variation in office-based quality: a claim-based profile of care provided to Medicare patients with diabetes. *JAMA* 1995; 273:1503–1508.
 43. Moss S, Klein R, Klein B. Factors associated with having eye examinations in persons with diabetes. *Arch Fam Med* 1995; 4:529–534.
 44. Mukamel D, Bresnick G, Wang Q, Dickey C. Barriers to compliance with screening guidelines for diabetic retinopathy. *Ophthalmic Epidemiol* 1999; 6:61–72.
 45. McCarty C, Lloyd-Smith C, Lee S, et al. Use of eye care services by people with diabetes: the Melbourne Visual Impairment Project. *Br J Ophthalmol* 1998; 82:410–414.
 46. Donovan J. Patient decision making: the missing ingredient in compliance research. *Int J Tech Assessment Health Care* 1995; 11:443–55.
 47. Kraft S, Marrero D, Lazaridis E, et al. Primary care physicians' practice patterns and diabetic retinopathy: current levels of care. *Arch Fam Med* 1997; 6:29–37.
 48. Jacques C, Jones R, Houts P, et al. Reported practice behaviors for medical care of patients with diabetes mellitus by primary-care physicians in Pennsylvania. *Diabetes Care* 1991; 14:712–717.
 49. Wender R. Preventive health care for diabetics: a realistic vision. *Arch Fam Med* 1997; 6:38–41.
 50. Steinmann W, Sinclair S, Holmes J, et al. Retinopathy in diabetics at first ophthalmologic visit [abstract]. *Invest Ophthalmol Vis Sci* 1986; 27(suppl):4.
 51. Will J, German R, Schurman E, Michael S, Kurth DM, Deeb L. Patient adherence to guidelines for diabetes eye care: results from the Diabetic Eye Disease Follow-up Study. *Am J Public Health* 1990; 84:1669–1671.
 52. Steinmann W, Garnder M, O'Sullivan R, et al. Provision of ophthalmic care by primary care providers. Submitted.
 53. Millstein M, Sinclair S, Steinmann W. Pupillary dilation with tropicamide 1%. *Ann Intern Med* 1987; 107:181–184.
 54. Sussman E, Tsias W, Soper K. Diagnosis of diabetic eye disease. *JAMA* 1982; 247:3231–3234.
 55. Jacobs D. Teaching doctors about the eye: trends in the education of medical students and primary care residents. *Surv Ophthalmol* 1998; 42:383–389.
 56. O'Hare J, Hopper A, Madhavan C, et al. Adding retinal photography to screening for diabetic retinopathy: a prospective study in primary care. *BMJ* 1996; 312:679–682.
 57. Moss S, Klein R, Kressler S, Richie K. Comparison between ophthalmoscopy and fundus photography in determining severity of diabetic retinopathy. *Ophthalmology* 1985; 92:62–67.
 58. Lin DY, Blumenkranz MS, Brotherton RJ, Grosvenor DM. The sensitivity of single-field nonmydriatic monochromatic digital fundus photography with remote image interpretation for diabetic retinopathy screening: a comparison with ophthalmoscopy and standardized mydriatic color photography. *Am J Ophthalmol* 2002; 134:204–213.
 59. Lim J, LaBree L, Nicholes T, Gardenas I. A comparison of digital nonmydriatic fundus imaging with standard 35-millimeter slides for diabetic retinopathy. *Ophthalmology* 2000; 107:866–976.
 60. Gomez-Ulla F, Fernandez M, Gonzalez F, et al. Digital retinal images and teleophthalmology for detecting and grading diabetic retinopathy. *Diabetes Care* 2002; 25:1384–1389.
 61. Bursell SE, Cavallerano JD, Cavallerano AA, et al. Stereo nonmydriatic digital-video color retinal imaging compared with Early Treatment Diabetic Retinopathy Study seven standard field 35-mm stereo color photos for determining level of diabetic retinopathy. *Ophthalmology* 2001; 108:572–585.
 62. Klein R, Klein B. Screening for diabetic retinopathy, revisited: editorial. *Am J Ophthalmol* 2002; 134:261–263.
 63. Cohen S, Halvorsen H, Gosselink C. Changing physician behavior to improve disease prevention. *Prev Med* 1994; 23:284–291.
 64. Dickey L, Kamerow D. The "Put Prevention into Practice" campaign: office tools and beyond. *J Fam Pract* 1994; 39:321–323.
 65. Manley M, Eppos R, Husten C, et al. Clinical interventions in tobacco control: a National Cancer Institute training program for physicians. *JAMA* 1991; 226:3172–3173.
-
- ADDRESS: Stephen H. Sinclair, MD, Crozer Chester Medical Center, Upland, PA 19013; e-mail Stephen@StephenSinclairMD.com.