

**MICHAEL ROSEN, MD**Minimally Invasive Surgery Center, Department  
of General Surgery, The Cleveland Clinic**JEFFREY PONSKY, MD**Section Head, Surgical Endoscopy, Department  
of General Surgery, The Cleveland Clinic

# Laparoscopic repair of giant paraesophageal hernias: An update for internists

## ABSTRACT

Paraesophageal hernias are typically associated with symptoms and can sometimes lead to life-threatening complications. We recommend laparoscopic surgical repair for patients with symptomatic paraesophageal hernias. This article explains why and presents a general overview of the laparoscopic repair of paraesophageal hernias and its merits relative to open surgical repair.

## KEY POINTS

Patients with paraesophageal hernias tend to be elderly and often have significant comorbidities.

Laparoscopic repair of paraesophageal hernias is associated with less postoperative discomfort and shorter hospitalization and recovery times compared with open surgical repair.

Almost all patients who undergo laparoscopic hernia repair obtain symptom relief, but patients in some reported series have experienced asymptomatic hernia recurrence.

**A** 65-YEAR-OLD WOMAN with coronary artery disease, hypertension, gastroesophageal reflux disease, and osteoporosis presented to her primary care physician reporting postprandial discomfort and weight loss of 15 pounds.

**Physical examination.** The patient appeared frail. Her abdomen appeared normal (soft, nontender, without masses, and with bowel sounds in all four quadrants), but her stool was heme-positive.

**Radiographic evaluation.** A chest radiograph (**FIGURE 1**) revealed a large intrathoracic stomach bubble. An upper gastrointestinal series showed a giant type III paraesophageal hernia with organoaxial rotation and an upside-down stomach (**FIGURE 2**).

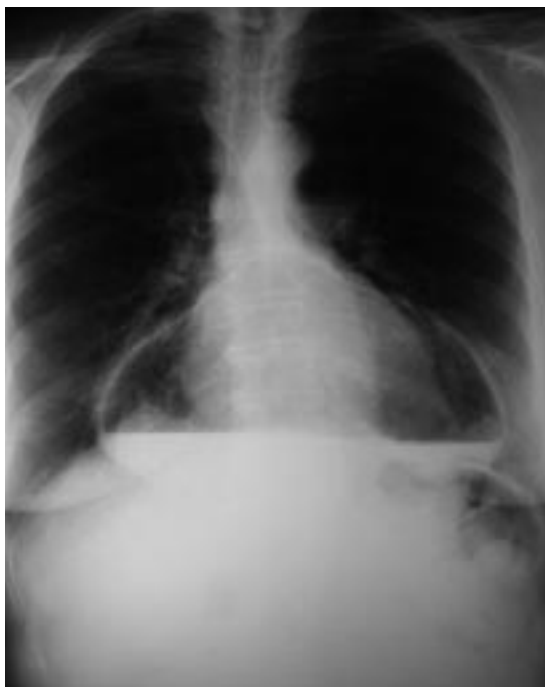
Upper endoscopy revealed linear gastric ulcerations.

She underwent an uncomplicated laparoscopic procedure to repair her paraesophageal hernia and was discharged home on the second postoperative day. She resumed her usual activities within 2 weeks.

## PARAESOPHAGEAL HERNIAS: TYPICALLY SYMPTOMATIC, SOMETIMES RISKY

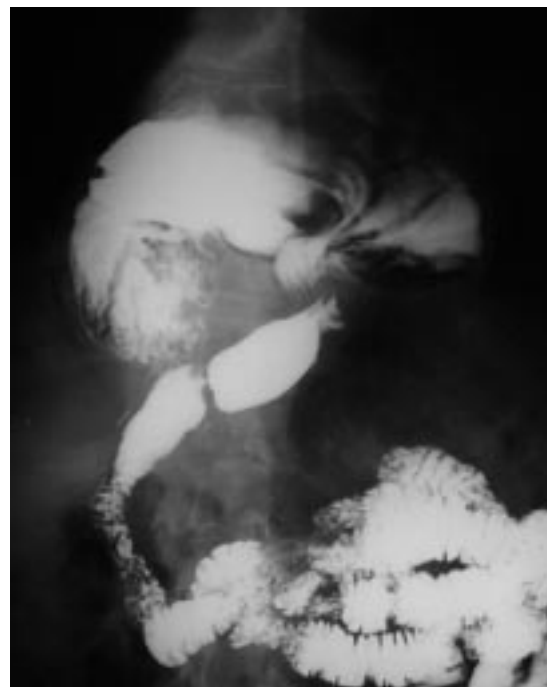Paraesophageal hernias usually occur in elderly people and account for between 5% and 10% of all hiatal hernias.<sup>1</sup> Hiatal hernias are defined by the relationship between the stomach, the gastroesophageal junction, and the hiatal defect.<sup>1</sup> Paraesophageal hernias occur when the fundus of the stomach herniates alongside the esophagus into the chest. The more common sliding hernias, by contrast,

### Paraesophageal hernia: Chest view



**FIGURE 1.** Chest radiograph in a 65-year-old woman, showing a gastric air bubble in the posterior mediastinum.

### Upper GI series



**FIGURE 2.** Upper gastrointestinal series in the same patient, showing a large type III paraesophageal hernia with organoaxial rotation.

**Paraesophageal  
hernias  
account for  
5%–10% of  
hiatal hernias**

occur when the gastroesophageal junction moves cephalad, and may predispose to gastroesophageal reflux.

Paraesophageal hernias tend to be large, yet patients with these hernias may have no symptoms. Upon detailed questioning, however, most patients report some symptom attributable to their hernia. Typical symptoms and signs include chest pain, epigastric discomfort, shortness of breath, postprandial discomfort, nausea, vomiting, weight loss, esophageal reflux, and anemia.

Moreover, patients with paraesophageal hernias may develop life-threatening complications, including<sup>2</sup>:

- Intrathoracic incarceration of the stomach with accompanying obstruction (vomiting, dysphagia, and chest pain)
- Decreased pulmonary reserve (from compromised lung expansion)
- Bleeding (mechanical or ischemic gastric ulcerations)
- Strangulation
- Perforation.

### ■ SYMPTOMS SHOULD PROMPT SURGICAL REPAIR

Historically, surgical repair has been indicated for patients with paraesophageal hernias regardless of whether they have related symptoms.<sup>3,4</sup> The rationale has been that, if left untreated, 30% to 45% of patients develop serious complications, and mortality rates of up to 50% have been reported among these patients.<sup>3,4</sup>

Recently, several authors have questioned the need for repair in a truly asymptomatic patient.<sup>5</sup> Our current practice is to offer laparoscopic surgical repair to patients with symptomatic hernias, but to use conservative management for patients with asymptomatic hernias.

### Open or laparoscopic surgery?

Because patients with paraesophageal hernias tend to be elderly, they often have significant comorbid conditions. For this reason, a minimally invasive approach can be particularly beneficial, reducing postoperative pain and the



length of hospitalization and convalescence.<sup>6</sup>

The alternatives, thoracotomy or laparotomy, result in significant postoperative morbidity and discomfort and require extensive postoperative rehabilitation. Patients stay in the hospital for 7 to 10 days, on average, after a thoracotomy or laparotomy, whereas most patients are discharged on the second day after a laparoscopic repair. Patients also return to full function more quickly after laparoscopic repair than with the more invasive alternatives.

### ■ WHAT'S INVOLVED IN LAPAROSCOPIC REPAIR?

#### Preoperative evaluation

The routine preoperative evaluation consists of:

- A complete history and physical examination
- Chest radiography
- Upper gastrointestinal series to define the hernia
- Flexible upper endoscopy to rule out other anatomic abnormalities.

Ambulatory esophageal pH testing and esophageal manometry are not routinely obtained since they are often unreliable, owing to the anatomic distortion of the gastroesophageal junction in patients with a paraesophageal hernia.

#### The technique

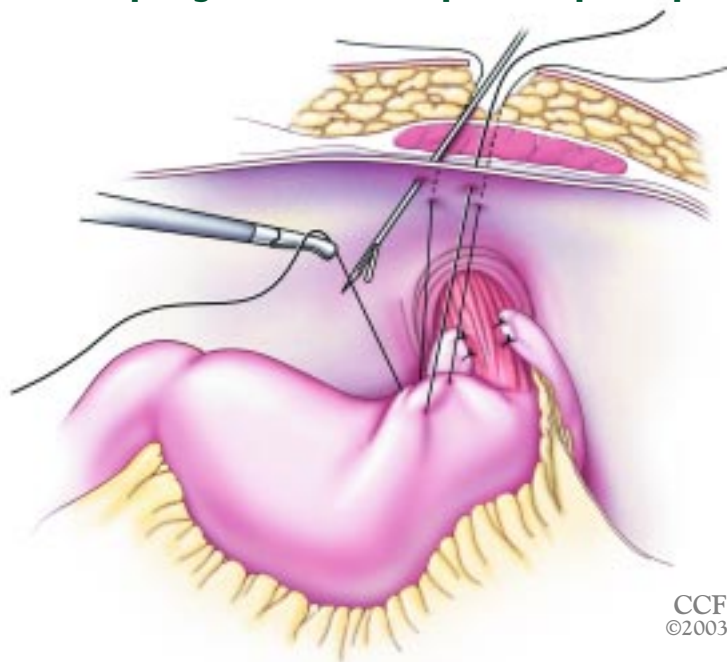
Whether approached laparoscopically or through a laparotomy or thoracotomy, the optimal surgical techniques for surgical repair continue to be debated.

Our standard laparoscopic technique involves a five-port approach. All patients undergo reduction of the hernia into the abdomen, complete mediastinal sac excision, primary crural repair, an antireflux procedure (Toupet fundoplication), and an anterior gastropexy. The anterior gastropexy involves suturing the anterior stomach wall to the anterior abdominal wall in two sites (FIGURE 3). Esophageal lengthening procedures (Collis gastroplasty) are not performed.

#### Postoperative diet

Patients are placed on a liquid diet on the first postoperative day if a meglumine diatrizoate (Gastrografin) swallow reveals no leakage.

## Paraesophageal hernia: laparoscopic repair



**FIGURE 3.** Intra-abdominal depiction of a completely reduced stomach with a Toupet fundoplication performed at the gastroesophageal junction. Here an anterior gastropexy is performed with sutures placed in the gastric body and a suture passer bringing the sutures out extracorporeally. When the gastropexy is completed, the sutures will fix the stomach to the anterior abdominal wall.

They are then advanced to a diet of soft solids for 2 weeks and then to a regular diet as tolerated.

### ■ OUTCOMES OF LAPAROSCOPIC REPAIR

#### The open surgery standard

If laparoscopic surgery is proposed as the method of choice for paraesophageal hernia repair, the operative principles and results of traditional open surgery should be maintained.<sup>7</sup>

Several large series with long-term follow-up have shown hernia recurrence rates of 7% to 11% following open surgical repair of paraesophageal hernias.<sup>8–10</sup> In one of these series, Maziak et al<sup>8</sup> reported on symptom-based outcomes following 94 consecutive open surgical repairs performed over 36 years. Ninety-seven percent of the repairs were performed via left posterolateral thoracotomy.



After a mean follow-up of 94 months, 93% of patients were free of symptoms or had only "inconsequential" symptoms requiring no therapy. Clearly this is a standard that laparoscopic repair has to match. These authors also reported two postoperative deaths, one of which was directly attributable to a leak of the staple line from the gastroplasty procedure.

### The laparoscopic record so far

Most series that have reported on laparoscopic repair of paraesophageal hernias have used primarily symptomatic follow-up and have reported hernia recurrence rates of 0% to 5%.<sup>6,11-14</sup> Because patients can have large paraesophageal hernias without accompanying symptoms before surgical repair, it is reasonable not to rely solely on symptomatic outcomes for evaluating potential postoperative recurrence. Two recent reports of laparoscopic series that evaluated paraesophageal hernia patients with postoperative radiographic studies found high rates of asymptomatic anatomic recurrence, ranging from 23% to 42%.<sup>15,16</sup>

At The Cleveland Clinic Foundation, one surgeon (J.P.) performed 28 consecutive laparoscopic repairs of large paraesophageal hernias between July 2000 and January 2002. One intraoperative complication (a small tear in the esophagus) occurred but was recognized immediately and repaired laparoscopically. The patient recovered without further event. No major postoperative complications or

deaths occurred. All patients experienced symptomatic relief, and barium esophageal studies revealed no anatomic recurrences during a mean follow-up of 21 months (range 12 to 24 months).

All of the paraesophageal hernias we have encountered could be reduced into the abdomen without undue tension after adequate sac excision. Also, none of our patients required an esophageal lengthening procedure. This supports the notion that adequate esophageal mobilization and complete sac excision with gastropexy results in satisfactory anatomic repair of these defects. One patient in our series developed transient postoperative dysphagia that required endoscopic dilatation. This rate is somewhat lower than previously reported rates of postoperative dysphagia (eg, 13% in the open surgery series of Maziak et al<sup>8</sup>).

### ■ LAPAROSCOPIC REPAIR IS SAFE, FEASIBLE

The laparoscopic repair of paraesophageal hernias is safe and feasible and can provide excellent results. Because most patients with paraesophageal hernias are elderly, like the one in our case report, the laparoscopic approach offers the important advantages of minimal postoperative pain and convalescence and an early return to normal activities. This minimally invasive approach provides these short-term benefits while maintaining a long-lasting durable repair.



### ■ REFERENCES

- Allison P. Reflux, esophagitis, sliding hiatal hernia and the anatomy of repair. *Surg Gynecol Obstet* 1951; 92:419-431.
- Oddsottir M. Paraesophageal hernia. *Surg Clin North Am* 2000; 80:1243-1252.
- Skinner DB, Belsey RH. Surgical management of esophageal reflux and hiatal hernia. Long-term results with 1,030 patients. *J Thorac Cardiovasc Surg* 1967; 53:33-54.
- Hill LD, Tobias JA. Paraesophageal hernia. *Arch Surg* 1968; 96:735-744.
- Stylopoulos N, Gazelle GS, Rattner DW. Paraesophageal hernias: operation or observation? *Ann Surg* 2002; 236:492-500.
- Luketich JD, Raja S, Fernando HC, et al. Laparoscopic repair of giant paraesophageal hernia: 100 consecutive cases. *Ann Surg* 2000; 232:608-618.
- Behrns KE, Schlinkert RT. Laparoscopic management of paraesophageal hernia: early results. *J Laparoendosc Surg* 1996; 6:311-317.
- Maziak DE, Todd TR, Pearson FG. Massive hiatus hernia: evaluation and surgical management. *J Thorac Cardiovasc Surg* 1998; 115:53-60; discussion 61-62.
- Ellis FH Jr, Crozier RE, Shea JA. Paraesophageal hiatus hernia. *Arch Surg* 1986; 121:416-420.
- Williamson WA, Ellis FH Jr, Streitz JM Jr, Shahian DM. Paraesophageal hiatal hernia: is an antireflux procedure necessary? *Ann Thorac Surg* 1993; 56:447-451; discussion 451-452.
- Perdikis G, Hinder RA, Filipi CJ, et al. Laparoscopic paraesophageal hernia repair. *Arch Surg* 1997; 132:586-589; discussion 590-591.
- Trus TL, Bax T, Richardson WS, et al. Complications of laparoscopic paraesophageal hernia repair. *J Gastrointest Surg* 1997; 1:221-228.
- Willekes CL, Edoga JK, Frezza EE. Laparoscopic repair of paraesophageal hernia. *Ann Surg* 1997; 225:31-38.
- Hawasli A, Zonca S. Laparoscopic repair of paraesophageal hiatal hernia. *Am Surg* 1998; 64:703-710.
- Hashemi M, Peters JH, DeMeester TR, et al. Laparoscopic repair of large type III hiatal hernia: objective followup reveals high recurrence rate. *J Am Coll Surg* 2000; 190:553-560; discussion 560-561.
- Wu JS, Dunnegan DL, Soper NJ. Clinical and radiologic assessment of laparoscopic paraesophageal hernia repair. *Surg Endosc* 1999; 13:497-502.

**ADDRESS:** Jeffrey Ponsky, MD, Department of General Surgery, A80, The Cleveland Clinic Foundation, 9500 Euclid Avenue, Cleveland, OH 44195; e-mail JPonsky@aol.com