



Primary pulmonary hypertension: An overview of epidemiology and pathogenesis

ZIAD W. GHAMRA, MD, AND RAED A. DWEIK, MD

■ ABSTRACT

Pulmonary arterial hypertension (PAH) refers to a group of diseases characterized by high pulmonary artery pressure of unknown mechanism. Primary pulmonary hypertension (PPH) is the idiopathic subset of PAH that affects a mostly young population and is more common in females than in males. A familial form of PPH accounts for about 6% of cases, and its autosomal dominant gene was recently identified. Pulmonary arterial hypertension is histologically characterized by endothelial and smooth muscle cell proliferation, medial hypertrophy, and thrombosis in situ. The pathogenesis of PAH remains unclear. Elevated pulmonary vascular resistance seems to result from an imbalance between locally produced vasodilators and vasoconstrictors, in addition to vascular wall remodeling. Nitric oxide, a locally produced selective pulmonary vasodilator, appears to play a central role in the pathobiology of PAH.

From the Department of Pulmonary and Critical Care Medicine, The Cleveland Clinic Foundation, Cleveland, Ohio.

Address: Raed A. Dweik, MD, Department of Pulmonary and Critical Care Medicine, A90, Cleveland Clinic Foundation, 9500 Euclid Avenue, Cleveland, OH 44195; e-mail: dweikr@ccf.org.

Disclosure: Both authors have indicated that they have no commercial affiliations or interests that pose a potential conflict of interest with this article.

Better understanding of the pathogenesis of primary pulmonary hypertension (PPH) over the last decade has led to new treatments that have changed the course of this once uniformly fatal condition. This progress is especially welcome because PPH affects a predominantly young and productive population. This article reviews recent advances in our understanding of the pathogenesis, epidemiology, and genetics of PPH.

■ DEFINITION AND CLASSIFICATION

Primary pulmonary hypertension is defined by an elevation in mean pulmonary artery pressure to greater than 25 mm Hg at rest or greater than 30 mm Hg during exercise in the absence of an identifiable etiology. In 1998 the second World Health Organization (WHO) conference on pulmonary hypertension¹ classified PPH with other pulmonary hypertensive conditions under the grouping of *pulmonary arterial hypertension* (PAH). Under this so-called Evian classification (the WHO conference was held in Evian, France), which was based on similarities in clinical features, PAH refers to a vasculopathy of unknown mechanism that involves the small muscular arteries and arterioles. Pulmonary arterial hypertension can be associated with known diseases, such as connective tissue diseases and human immunodeficiency virus (HIV) infection, in addition to classic idiopathic PPH (Table 1).

■ HISTOPATHOLOGY

The hypertensive pulmonary arteriopathy seen in patients with PPH affects the muscular arteries and

arterioles and probably represents a combination of injury and repair. Several histopathologic patterns can be seen, although none is pathognomonic, since the diagnosis of PPH still relies on the exclusion of secondary causes.^{2,3}

Plexogenic pulmonary arteriopathy (Figure 1) is the most common lesion seen in PPH. It is characterized by medial hypertrophy, fibrotic intimal lesions that may comprise organized thrombi, and destructive lesions involving the entire arterial wall. **Thrombotic pulmonary arteriopathy** is defined by the presence of organized mural thrombi resulting from thrombosis in situ in the setting of an intact arterial wall and a nondilated vessel. These two lesion types, though distinct histologically, appear to be the product of the same disease process, since different members of kindreds with familial PPH had evidence of both lesions.⁴

Isolated medial hypertrophy, the third type of histopathologic lesion in PPH, consists of a pattern of increased thickness of the medial smooth muscle wall, duplication of the elastic laminae in muscular arteries, and muscularization of the arterioles. This rare pattern may actually precede the formation of the plexogenic lesions and is thought to be reversible with treatment.⁵

■ EPIDEMIOLOGY

A few case series of elevated pulmonary artery pressures in otherwise healthy young people in the 1950s and 1960s,^{6,7} along with the epidemic of anorexic-associated PPH in Europe, led to the first WHO conference on PPH in 1973. As part of an ensuing international effort to better understand this rare condition, the National Heart, Lung, and Blood Institute's Division of Lung Disease in 1981 initiated the national Primary Pulmonary Hypertension Patient Registry. The registry prospectively enrolled 187 patients from 32 referral centers nationwide through 1985.⁸ These patients' demographic characteristics constitute the best available data to date on the epidemiology of PPH.

The mean age of this population was 36.4 years (± 15 SD; range 1–81). A 1.7:1.0 female-to-male preponderance was noted. Nearly one tenth of patients were older than 60 years of age. No racial predilection was found.

Subsequent retrospective reports from France,⁹ Israel,¹⁰ and Japan¹¹ found comparable mean ages among samples of patients with PPH (39.0, 42.8,

TABLE 1
The 1998 WHO Evian classification
of pulmonary hypertension

| |
|---|
| 1. Pulmonary arterial hypertension |
| 1.1 Primary pulmonary hypertension |
| a. Sporadic |
| b. Familial |
| 1.2 Related to: |
| a. Collagen vascular disease |
| b. Congenital systemic to pulmonary shunts |
| c. Portal hypertension |
| d. HIV infection |
| e. Drugs/toxins (anorexigens or others) |
| f. Persistent pulmonary hypertension of the newborn |
| g. Other |
| 2. Pulmonary venous hypertension |
| 2.1 Left-sided atrial or ventricular heart disease |
| 2.2 Left-sided valvular heart disease |
| 2.3 Extrinsic compression of central pulmonary veins |
| a. Fibrosing mediastinitis |
| b. Adenopathy/tumors |
| 2.4 Pulmonary veno-occlusive disease |
| 2.5 Other |
| 3. Pulmonary hypertension associated with disorders of the respiratory system or hypoxemia |
| 3.1 Chronic obstructive pulmonary disease |
| 3.2 Interstitial lung disease |
| 3.3 Sleep-disordered breathing |
| 3.4 Alveolar hypoventilation disorders |
| 3.5 Chronic exposure to high altitude |
| 3.6 Neonatal lung disease |
| 3.7 Alveolar-capillary dysplasia |
| 3.8 Other |
| 4. Pulmonary hypertension due to chronic thrombotic and/or embolic disease |
| 4.1 Thromboembolic obstruction of proximal pulmonary arteries |
| 4.2 Obstruction of distal pulmonary arteries |
| a. Pulmonary embolism (thrombus, tumor, ova, parasites, foreign matter) |
| b. In situ thrombosis |
| c. Sickle cell disease |
| 5. Pulmonary hypertension due to disorders directly affecting the pulmonary vasculature |
| 5.1 Inflammatory |
| a. Schistosomiasis |
| b. Sarcoidosis |
| c. Other |
| 5.2 Pulmonary capillary hemangiomatosis |

Adapted from reference 1 with permission of the World Health Organization.

and 41.8 years, respectively) and similar female-to-male ratios, indicating an apparent worldwide female preponderance.

No studies on the incidence of PPH have yet been performed, but the incidence has been estimated at 1 to 2 cases per 1 million inhabitants per

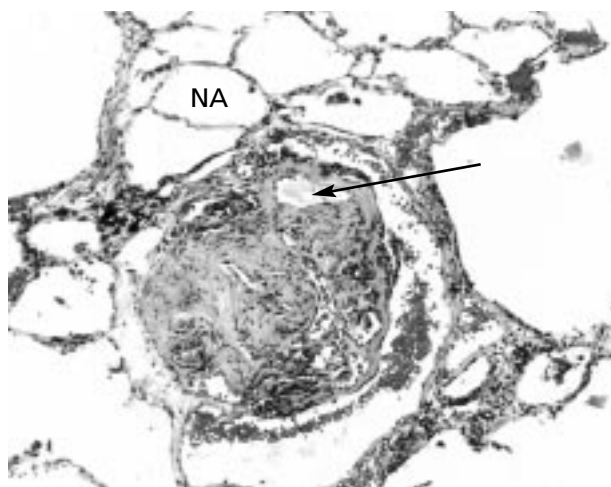


Figure 1. Histopathologic photograph of a plexogenic pulmonary arteriopathy lesion surrounded by normal alveoli (NA). The arrow points to a newly formed vascular lumen. Color versions of this photograph and another photograph of this lesion taken with a different stain appear on the cover of this supplement. Photo courtesy of Carol F. Farver, MD.

year.⁸ Considering the rarity and subtle presentation of this disease, underdiagnosis and underreporting are likely widespread, making calculation of a true incidence difficult.

Familial PPH

In the national registry for PPH,⁸ 12 (6%) of the 187 enrolled patients had a first-degree relative affected by the same disease process. Familial PPH appears to be inherited as an autosomal dominant trait with a variable but low gene penetrance, with some individuals inheriting the trait without exhibiting the phenotype.¹² Genetic anticipation further affects the gene penetrance, with subsequent generations developing PPH at an earlier age.¹³ Interestingly, 160 (57%) of 282 children born to parents who were carriers of the gene for familial PPH were female, suggesting either a selective wastage of male fetuses or a preferential fertilization by an X over a Y male gamete.¹³

In 1997, the gene for familial PPH was mapped to chromosome 2q31–32.^{14,15} In 2000, the bone morphogenetic protein receptor type II gene (*BMPR2*) was identified as the actual gene for familial PPH and its product was recognized as a transforming growth factor beta receptor, suggesting a role for this receptor in maintaining pulmonary vascular integrity.^{16,17} In fact, mutations in *BMPR2* were also found in 13

(26%) of 50 patients with sporadic or nonfamilial PPH in one series,¹⁸ which suggests that it may soon be possible to identify individuals at risk for PPH.

These landmark discoveries in the genetics of familial PPH have opened the way to a better understanding of the pathogenesis of PPH and may have important therapeutic implications as more of the molecular pathways are revealed.

■ PATHOGENESIS

Pulmonary arterial hypertension, although associated with some disease entities, has a still-unknown mechanism that probably results from multiple noxious stimuli targeting a predisposed pulmonary vasculature. The most obvious predisposing factors are the mutations in the *BMPR2* gene^{16,17} that result in familial PPH and in some cases of sporadic PPH, as discussed above.¹⁸

The epidemic of PAH that developed in users of appetite-suppressant drugs,^{19,20} probably through these drugs' serotonergic effects,^{20,21} is an example of a noxious stimulus causing PAH. However, because only 0.1% of aminorex users were affected, possible polymorphism at the level of the vascular smooth muscle serotonin transporter was recently hypothesized as a predisposing factor for PPH in these individuals.²¹ The mechanism of injury leading to PAH associated with HIV infection is less clear,²² although some evidence points to stimulation of endothelial cell growth by infected T lymphocytes.²³ Pulmonary arterial hypertension is also associated with connective tissue diseases without any obvious pathophysiologic link.²⁴ Some have proposed the possibility of an autoimmune injury leading to the vasculopathy.^{25,26} Deficiency of thyroid hormone, either through a shared autoimmune insult to the thyroid gland and the pulmonary vasculature, or through loss of the thyroid hormone's vasomotor role, has also been associated with PPH.²⁷ Moreover, the paracrine actions of the vascular endothelium appear dysfunctional in PAH, resulting in abnormal proliferation of vascular smooth muscle and endothelial cells, which may contribute to the increased pulmonary vascular resistance observed in this disease.

Many advances have been made in unraveling the pathogenesis of PAH. In many instances, however, any cause-and-effect explanation for the observed abnormalities remains blurred, as most abnormalities are found in advanced stages of pulmonary hypertension.

Endothelial dysfunction/vasoconstriction

An injured endothelium probably represents the response to a variety of stimuli that lead to secondary pulmonary hypertension, but the endothelial dysfunction seen in PPH seems to be idiopathic, or of yet unknown etiology. It remains uncertain whether this constitutes one of the triggers for the vasculopathy of PPH or whether it is in response to a variety of noxious mechanical and chemical stimuli. The endothelial malfunction is manifested by an imbalance between locally produced vasoconstrictors and vasodilators, resulting in abnormal vascular tone. Of those local mediators, nitric oxide, prostacyclin, and endothelin-1 are among the best studied and carry several therapeutic implications.

Nitric oxide. The endothelium-derived relaxing factor nitric oxide (NO) has been shown to play a pivotal role in the pathobiology of PPH.²⁸⁻³³ Nitric oxide is a potent pulmonary vasodilator that is produced locally in the lung and has profound effects on smooth muscle relaxation and proliferation. Normal pulmonary vascular tone is maintained in part by local production of the vasodilator NO, and NO exerts an inhibitory effect on vascular smooth muscle cell proliferation and migration.³⁴ Anatomic sources of NO in the lung include the pulmonary circulation, the lower airways, and the upper airways and paranasal sinuses.³⁵

Nitric oxide is endogenously synthesized by NO synthases, which convert L-arginine to L-citrulline and NO in the presence of oxygen and several cofactors.^{36,37} Three NO synthases (types I, II, and III) have been identified and are widely expressed in various tissues, including the lungs.³⁸ Nitric oxide also can be detected in the exhaled breath of humans.^{35,39}

Once produced, NO is freely diffusible and enters pulmonary smooth muscle cells to activate soluble guanylate cyclase and produce guanosine 3',5'-cyclic monophosphate (cGMP).³⁶ Increased cGMP activates a kinase that phosphorylates a calcium-dependent potassium channel, leading to hyperpolarization and pulmonary vascular smooth muscle relaxation. The close proximity of the airways to the blood vessels allows the NO produced in high levels in the upper⁴⁰ and lower airways by NO synthase II³⁵ to affect the pulmonary vascular tone in concert with the low NO levels produced by NO synthase III in the vascular endothelium. As soon as this potent vasodilator's job is done in the lung, it binds to hemoglobin and has virtually no effect on sys-

temic hemodynamics, making it a truly selective pulmonary vasodilator.

Interestingly, patients with PPH have low levels of NO in their exhaled breath.³⁰ In fact, the severity of pulmonary hypertension correlates inversely with NO levels estimated by measurement of NO reaction products in bronchoalveolar lavage fluid (**Figure 2**).³⁰ Although this is a more complex issue than simple lack of a vasodilator, replacement of NO seems to work well in treating the problem.⁴¹ Exogenous administration of NO gas by inhalation is a highly effective and specific therapy for PPH.^{33,41,42} Although cost and unresolved technical difficulties in the delivery of inhaled NO have prevented its widespread use to date,⁴¹ recent evidence suggests that other therapies for PPH may exert their benefits at least partially through endogenous NO.^{28,31} Nitric oxide levels were found to be increased in the exhaled breath of patients with PPH after therapeutic infusion of epo-prostenol, a prostacyclin analogue.³¹

Endothelin-1 is a peptide produced by the vascular endothelium that has potent vasoconstrictive and proliferative paracrine actions on vascular smooth muscle cells.⁴³ The pulmonary circulation plays an important role in the production and clearance of endothelin-1, and this physiologic balance is reflected in circulating levels of endothelin-1.⁴⁴ Patients with pulmonary hypertension, PPH in particular, have an increased expression of endothelin-1 in pulmonary vascular endothelial cells.⁴⁵ Similarly, serum endothelin-1 levels are increased in patients with pulmonary hypertension.⁴⁶

Prostacyclin. The endothelium also produces prostacyclin (PGI₂) by cyclooxygenase metabolism of arachidonic acid. Prostacyclin causes vasodilation throughout the human circulation⁴⁷ and is an inhibitor of platelet aggregation by its action on platelet adenylate cyclase.⁴⁸

The final enzyme in the production of PGI₂ is prostacyclin synthase. Transgenic mice overexpressing this enzyme in their respiratory epithelial cells are protected against the development of hypoxic pulmonary hypertension,⁴⁹ and the remodeled pulmonary vasculature in lung tissue obtained from patients with severe PPH expresses low levels of prostacyclin synthase when compared with normal lung tissue.⁵⁰ In addition, a PGI₂ metabolite, 2,3-dinor-6-keto-PGF₁, is diminished in the urine of patients with pulmonary hypertension, further underscoring the role of endothelial dysfunction in the pathobiology of PPH.⁵¹

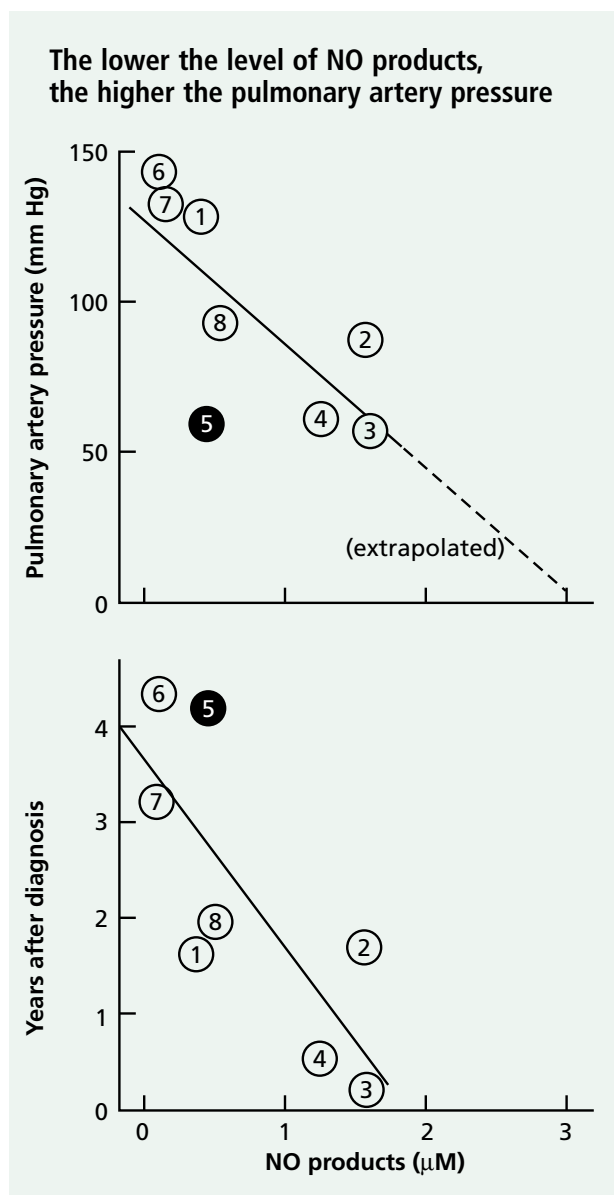


Figure 2. Relationship of reaction products of nitric oxide (NO) in bronchoalveolar lavage fluid to pulmonary artery pressures (top) and years after diagnosis of PPH (bottom). The circles represent individual patients. The filled circle represents a patient with familial PPH who died during the study. Reprinted, with permission, from reference 30. © American Lung Association

Remodeling

In addition to the pulmonary vasoconstriction that results from dysregulation of the local endothelial mediators as discussed above, pulmonary vascular remodeling seems to play a major role in the increased vascular resistance seen in PPH. An

abnormal proliferation of endothelial cells occurs in the irreversible plexogenic lesion.⁵² These proliferating endothelial cells are monoclonal in origin, raising the possibility that a random somatic mutation may be one of the initial steps leading to sporadic PPH.⁵³ The endothelial cells express angiogenic factors (eg, vascular endothelial growth factor), which suggests a role for them in the disordered angiogenesis that may be part of the plexiform lesion formation.⁵⁴ In addition, pulmonary vascular smooth muscle cells that normally have a low rate of multiplication undergo proliferation and hypertrophy. Those smooth cell changes arise from the loss of the antimitogenic endothelial substances (eg, PGI₂ and NO)^{55,56} and an increase in mitogenic substances (eg, endothelin-1).⁵⁷ At the same level, the growth-inhibitory effect of transforming growth factor beta on vascular smooth cells is lost, which may explain the molecular mechanism of the mutation in familial PPH.^{18,58}

Other stimuli arise from locally activated platelets that release thromboxane A₂ and serotonin, which act as growth-promoting substances on the vascular smooth muscle cells.^{52,59,60} In fact, elevated blood levels of serotonin are found in patients with PPH,⁶¹ perhaps because of an abnormality in the platelet storage pool that is the main source of serotonin in the human circulation.⁶² Pulmonary vascular smooth cell hyperplasia also correlates with polymorphism and overexpression of the serotonin transporter, which may constitute an additional factor in an individual's genetic susceptibility to developing PPH.^{21,63} On the other hand, the pulmonary artery smooth muscle cells in PPH appear to be in an abnormally depolarized state.⁶⁴ This abnormal resting potential results in a heightened state of vasoconstriction secondary to increased levels of cytosolic Ca²⁺ and seems to relate to a primary dysfunction or downregulation of the voltage-gated K⁺ channels.^{64,65}

In addition to smooth muscle cell proliferation, an increase in extracellular matrix deposition contributes to the medial hypertrophy in PAH.⁶⁶ The extracellular matrix is remodeled through a dynamic process of matrix protein degradation and synthesis triggered by the high flow and pressure in the pulmonary vasculature, resulting in the obliterative changes seen in the pulmonary arteries.⁶⁶ A perivascular inflammatory cell infiltrate observed in the plexogenic lesion indicates that cytokines may also play a role in its development.⁵²

Thrombosis

In a large retrospective series that looked at lung tissue obtained from autopsy specimens of patients with PPH,⁶⁷ 22 of 56 pathologic specimens showed evidence of thrombi confined to the small muscular arteries. This was atypical for the classic appearance of venous thromboembolism, and the concept of thrombosis in situ in PPH emerged.

Pulmonary arterial hypertension seems to be associated with a prothrombotic milieu that is a consequence rather than a cause of the vasculopathy, although this remains debatable. The determinants of this increased propensity for thrombosis arise at the level of the microvasculature, where the dysfunctional endothelium loses the anticoagulant properties that usually prevent intravascular clot-

ting of blood material.⁶⁸ Instead, the procoagulation mediators that are usually inhibited under physiologic conditions seem to be activated. In fact, blood thrombin activity is increased in patients with pulmonary hypertension, indicating activation of intravascular coagulation,⁶⁹ whereas soluble thrombomodulin, a cell membrane protein that acts as an important site of thrombin binding and coagulation inactivation, is decreased.⁷⁰ In addition, PGI₂ and NO, both inhibitors of platelet aggregation, are decreased at the level of the injured endothelial cell, as discussed above. Circulating platelets in patients with PAH seem to be in a continuous state of activation⁵¹ and contribute to the prothrombotic milieu by aggregating at the level of the injured endothelial cells.⁷¹

REFERENCES

- Rich S, ed. Primary pulmonary hypertension: executive summary from the World Symposium on Primary Pulmonary Hypertension. Geneva: World Health Organization, 1998.
- Pietra GG, Edwards WD, Kay M, et al. Histopathology of primary pulmonary hypertension. A qualitative and quantitative study of pulmonary blood vessels from 58 patients in the National Heart, Lung, and Blood Institute Primary Pulmonary Hypertension Registry. *Circulation* 1989; 80:1198–1206.
- Pietra GG. Histopathology of primary pulmonary hypertension. *Chest* 1994; 105(2 suppl):2S–6S.
- Lloyd JE, Atkinson JB, Pietra GG, et al. Heterogeneity of pathologic lesions in familial primary pulmonary hypertension. *Am Rev Respir Dis* 1988; 138:952–957.
- Bjornsson J, Edwards WD, Kay JM, et al. Primary pulmonary hypertension: a histopathologic study of 80 cases. *Mayo Clin Proc* 1985; 60:16–25.
- Dresdale DT, Schultz M, Michtom RJ. Primary pulmonary hypertension: clinical and hemodynamic study. *Am J Med* 1951; 11:686–694.
- Wood P. Pulmonary hypertension with special reference to the vasoconstrictive factor. *Br Heart J* 1959; 21:557–570.
- Rich S, Dantzker DR, Ayres SM, et al. Primary pulmonary hypertension: a national prospective study. *Ann Intern Med* 1987; 107:216–223.
- Brenot F. Primary pulmonary hypertension. Case series from France. *Chest* 1994; 105(suppl):33S–36S.
- Appelbaum L, Yigla M, Bendayan D, et al. Primary pulmonary hypertension in Israel: a national survey. *Chest* 2001; 119:1801–1806.
- Kuriyama T. Epidemiology of primary pulmonary hypertension in Japan. *Nippon Rinsho* 2001; 59:1047–1052.
- Lloyd JE, Primm RK, Newman JH. Familial primary pulmonary hypertension: clinical patterns. *Am Rev Respir Dis* 1984; 129:194–197.
- Lloyd JE, Butler MG, Foroud TM, et al. Genetic anticipation and abnormal gender ratio at birth in familial primary pulmonary hypertension. *Am J Respir Crit Care Med* 1995; 152:93–97.
- Nichols WC, Koller DL, Slovis B, et al. Localization of the gene for familial primary pulmonary hypertension to chromosome 2q31–32. *Nat Genet* 1997; 15:277–280.
- Morse JH, Jones AC, Barst RJ, et al. Mapping of familial primary pulmonary hypertension locus (PPH1) to chromosome 2q31–32. *Circulation* 1997; 95:2603–2606.
- Deng Z, Morse JH, Slager SL, et al. Familial primary pulmonary hypertension (gene PPH1) is caused by mutations in the bone morphogenetic protein receptor-II gene. *Am J Hum Genet* 2000; 67:737–744.
- Lane KB, Machado RD, Pauculo MW, et al. Heterozygous germline mutations in BMPR2, encoding a TGF- β receptor, cause familial primary pulmonary hypertension. The International PPH Consortium. *Nat Genet* 2000; 26:81–84.
- Thomson JR, Machado RD, Pauculo MW, et al. Sporadic primary pulmonary hypertension is associated with germline mutations of the gene encoding BMPR-II, a receptor member of the TGF- β family. *J Med Genet* 2000; 37:741–745.
- Gurtner HP. Pulmonary hypertension, “plexogenic pulmonary arteriopathy” and the appetite depressant drug aminorex: post or propter? *Bull Physiopathol Res* 1979; 15:897–923.
- Rothman RB, Ayestas MA, Dersch CM, Baumann MH. Aminorex, fenfluramine, and chlorphentermine are serotonin transporter substrates. Implications for primary pulmonary hypertension. *Circulation* 1999; 100:869–875.
- Eddahibi S, Humbert M, Fadel E, et al. Hyperplasia of pulmonary artery smooth muscle cells is causally related to overexpression of the serotonin transporter in primary pulmonary hypertension. *Chest* 2002; 121(3 suppl):97S–98S.
- Mehta NJ, Khan IA, Mehta RN, Sepkowitz DA. HIV-related pulmonary hypertension: analytic review of 131 cases. *Chest* 2000; 118:1133–1141.
- Ascheri G, Hohendl C, Schatz O, et al. Infection with human immunodeficiency virus-1 increases expression of vascular endothelial cell growth factor in T cells: implications for acquired immunodeficiency syndrome-associated vasculopathy. *Blood* 1999; 93:4232–4241.
- Gurubhagavatula I, Palevsky HI. Pulmonary hypertension in systemic autoimmune disease. *Rheum Dis Clin North Am* 1997; 23:365–394.
- Yanai-Landau H, Amital H, Bar-Dayana Y, et al. Autoimmune aspects of primary pulmonary hypertension. *Pathobiology* 1995; 63:71–75.
- Barst RJ, Flaster ER, Menon A, et al. Evidence for the association of unexplained pulmonary hypertension in children with the major histocompatibility complex. *Circulation* 1992; 85:249–258.
- Curnock AL, Dweik RA, Higgins BH, et al. High prevalence of hypothyroidism in patients with primary pulmonary hypertension. *Am J Med Sci* 1999; 318:289–292.
- Dweik RA. Pulmonary hypertension and the search for the selective pulmonary vasodilator. *Lancet* 2002; 360:886.
- Dweik RA. The promise and reality of nitric oxide in the diagnosis

- and treatment of lung disease. *Cleve Clin J Med* 2001; 68:486–493.
30. Kaneko FT, Arroliga AC, Dweik RA, et al. Biochemical reaction products of nitric oxide as quantitative markers of primary pulmonary hypertension. *Am J Respir Crit Care Med* 1998; 158:917–923.
31. Ozkan M, Dweik RA, Laskowski D, et al. High levels of nitric oxide in individuals with pulmonary hypertension receiving epoprostenol therapy. *Lung* 2001; 179:233–243.
32. Ozkan M, Dweik RA, Ahmad M. Drug-induced lung disease. *Cleve Clin J Med* 2001; 68:782–795.
33. Arroliga AC, Dweik RA, Kaneko FJ, Erzurum SC. Primary pulmonary hypertension: update on pathogenesis and novel therapies. *Cleve Clin J Med* 2000; 67:175–190.
34. Dweik RA, Erzurum SC. Effects of nitric oxide and cyclic GMP on smooth muscle proliferation. In: Moss J, ed. *LAM and Other Diseases Characterized by Smooth Muscle Proliferation (Lung Biology in Health and Disease series)*. New York: Marcel Dekker, 1999; 131:333–349.
35. Dweik RA, Laskowski D, Abu-Soud HM, et al. Nitric oxide synthesis in the lung. Regulation by oxygen through a kinetic mechanism. *J Clin Invest* 1998; 101:660–666.
36. Moncada S, Higgs A. The L-arginine–nitric oxide pathway. *N Engl J Med* 1993; 329:2002–2012.
37. Nathan C, Xie QW. Nitric oxide synthases: roles, tolls, and controls. *Cell* 1994; 78:915–918.
38. Kobzik L, Bredt DS, Lowenstein CJ, et al. Nitric oxide synthase in human and rat lung: immunocytochemical and histochemical localization. *Am J Respir Cell Mol Biol* 1993; 9:371–377.
39. Gustafsson LE, Leone AM, Persson MG, et al. Endogenous nitric oxide is present in the exhaled air of rabbits, guinea pigs and humans. *Biochem Biophys Res Commun* 1991; 181:852–857.
40. Lundberg JO, Farkas-Szallasi T, Weitzberg E, et al. High nitric oxide production in human paranasal sinuses. *Nat Med* 1995; 1:370–373.
41. Channick RN, Newhart JW, Johnson FW, et al. Pulsed delivery of inhaled nitric oxide to patients with primary pulmonary hypertension: an ambulatory delivery system and initial clinical tests. *Chest* 1996; 109:1545–1549.
42. Rubin LJ. Primary pulmonary hypertension. *N Engl J Med* 1997; 336:111–117.
43. Yanagisawa M, Kurihara H, Kimura S, et al. A novel potent vasoconstrictor peptide produced by vascular endothelial cells. *Nature* 1988; 332:411–415.
44. Dupuis J, Duncan JS, Cernacek P, Gosselin G. Human pulmonary circulation is an important site for both clearance and production of endothelin-1. *Circulation* 1996; 94:1578–1584.
45. Giaid A, Yanagisawa M, Langleben D, et al. Expression of endothelin-1 in the lungs of patients with pulmonary hypertension. *N Engl J Med* 1993; 328:1732–1739.
46. Stewart DJ, Levy RD, Cernacek P, Langleben D. Increased plasma endothelin-1 in pulmonary hypertension: marker or mediator of disease? *Ann Intern Med* 1991; 114:464–469.
47. Moncada S, Vane JR. Pharmacology and endogenous roles of prostaglandin endoperoxides, thromboxane A₂, and prostacyclin. *Pharmacol Rev* 1979; 30:293–331.
48. Gorman RR, Bunting S, Miller OV. Modulation of human platelet adenylate cyclase by prostacyclin. *Prostaglandins* 1977; 273:767–768.
49. Geraci MW, Gao B, Shepherd DC, et al. Pulmonary prostacyclin synthase overexpression in transgenic mice protects against development of hypoxic pulmonary hypertension. *J Clin Invest* 1999; 103:1509–1515.
50. Tudor RM, Cool CD, Geraci MW, et al. Prostacyclin synthase expression is decreased in lungs from patients with severe pulmonary hypertension. *Am J Respir Crit Care Med* 1999; 159:1925–1932.
51. Christman BW, McPherson CD, Newman JH, et al. An imbalance between the excretion of thromboxane and prostacyclin metabolites in pulmonary hypertension. *N Engl J Med* 1992; 327:70–75.
52. Tudor RM, Groves B, Badesh DB, Voelkel NF. Exuberant endothelial cell growth and elements of inflammation are present in plexiform lesions of pulmonary hypertension. *Am J Pathol* 1994; 144:275–285.
53. Lee SD, Shroyer KR, Markham NE, et al. Monoclonal endothelial cell proliferation is present in primary but not secondary pulmonary hypertension. *J Clin Invest* 1998; 101:927–934.
54. Tudor RM, Chacon M, Wang J, et al. Expression of angiogenesis-related molecules in plexiform lesions in severe pulmonary hypertension: evidence for a process of disordered angiogenesis. *J Pathol* 2001; 195:367–374.
55. Newby AC, Southgate KM, Assender JW. Inhibition of vascular smooth muscle cell proliferation by endothelium-dependent vasodilators. *Herz* 1992; 17:291–299.
56. Pukac LA, Ottlinger ME, Karnovsky MJ. Heparin suppresses specific second messenger pathways for protooncogene expression in rat vascular smooth muscle cells. *J Biol Chem* 1992; 267:3707–3711.
57. Hirata Y, Takagi Y, Fukunda Y, Marumo F. Endothelin is a potent mitogen for rat vascular smooth muscle cells. *Atherosclerosis* 1989; 78:225–228.
58. Morell NW, Yang X, Upton PD, et al. Altered growth responses of pulmonary artery smooth muscle cells from patients with primary pulmonary hypertension to transforming growth factor- β 1 and bone morphogenetic proteins. *Circulation* 2001; 104:790–795.
59. Lee S, Wang W, Lanzillo J, Fanburg B. Serotonin produces both hyperplasia and hypertrophy of bovine pulmonary artery smooth muscle cells in culture. *Am J Physiol* 1994; 266(1 Pt 1):L46–L52.
60. Fanburg B, Sheu-Ling L. A new role for an old molecule: serotonin as a mitogen. *Am J Physiol* 1997; 272(1 Pt 1):L795–L806.
61. Herve P, Launay J-M, Scrobohaci M-L, et al. Increased plasma serotonin in primary pulmonary hypertension. *Am J Med* 1995; 99:249–254.
62. Herve P, Drouet L, Dosquet C, et al. Primary pulmonary hypertension in a patient with a familial platelet storage pool disease: role of serotonin. *Am J Med* 1990; 89:117–120.
63. Eddahibi S, Humbert M, Fadel E, et al. Serotonin transporter overexpression is responsible for pulmonary artery smooth muscle hyperplasia in primary pulmonary hypertension. *J Clin Invest* 2001; 108:1141–1150.
64. Yuan JX, Aldinger AM, Juhaszova M, et al. Dysfunctional voltage-gated K⁺ channels in pulmonary artery smooth muscle cells of patients with primary pulmonary hypertension. *Circulation* 1998; 98:1400–1406.
65. Yuan XJ, Wang J, Juhaszova M, et al. Attenuated K⁺ channel gene transcription in primary pulmonary hypertension. *Lancet* 1998; 351:726–727.
66. Rabinovitch M. Pathobiology of pulmonary arterial hypertension. Extracellular matrix. *Clin Chest Med* 2001; 22:433–449.
67. Fuster V, Steele PM, Edwards WD, et al. Primary pulmonary hypertension: natural history and the importance of thrombosis. *Circulation* 1984; 70:580–587.
68. Farber HW, Loscalzo J. Prothrombotic mechanisms in primary pulmonary hypertension. *J Lab Clin Med* 1999; 134:561–566.
69. Chaouat A, Weitzenblum E, Higenbottam T. The role of thrombosis in severe pulmonary hypertension. *Eur Respir J* 1996; 9:356–363.
70. Welsh CH, Hassell KL, Badesch DB, et al. Coagulation and fibrinolytic profiles in patients with severe pulmonary hypertension. *Chest* 1996; 110:710–717.
71. Lopes AA, Maeda NY, Almeida A, et al. Circulating platelet aggregates indicative of in vivo platelet activation in pulmonary hypertension. *Angiology* 1993; 44:701–706.