

# FOREIGN BODY IN THE ESOPHAGUS

## *Report of a Case*

PAUL M. MOORE, JR., M.D.

A foreign body in the esophagus always causes some disturbance in deglutition. There may be dysphagia or odynphagia. Usually the two are combined and the patient not only is unable to swallow food, but also has definite pain in the process. In addition to this, he usually can indicate the level at which the obstruction exists. The amount of obstruction to the passage of food depends on the size and shape of the foreign body. There usually is a definite history of the onset but in infants and small children this history may be lacking since the object may have been swallowed when the child was alone. There may be no definite pain. The only sign which may be noticed is that the child does not eat well. He may refuse all solid food or may vomit solid food when he attempts to eat it. Reluctance to eat is not an entirely reliable sign because many children pass through a period in which they pick at their food and take a long time and much persuasion to eat a meal. However, when a child who has previously eaten well suddenly begins to refuse food, he should be suspected of having a foreign body in the esophagus. Anteroposterior and lateral roentgenograms should be taken. If a radio-opaque foreign body is present, it will show in these films. If these are negative, barium should be given and its progress through the esophagus watched under the fluoroscope. Roentgenograms should be taken of any deviation from normal. These will show the presence of a nonopaque foreign body. If all of these examinations are negative, probably no foreign body is present although a small one still could be caught in a fold in the esophagus, and produce pain. In older people the possibility of an early carcinoma always should be borne in mind. It is well to advise esophagoscopy in all such cases.

A small sharp foreign body may pass through the esophagus and not lodge in it, but in passing may scratch the esophageal mucosa. This leaves the sensation of a foreign body being present and there is pain on swallowing. If roentgen studies are negative, a short period of observation may be followed before esophagoscopy is done. This is not safe, however, unless careful roentgen studies are made. I have seen one case that ended fatally from perforation of the esophagus and aorta by a chicken bone. The family physician had not made roentgen studies and because discomfort diminished, nothing was done until a massive hemorrhage from the esophagus occurred. Only then was the patient referred to the hospital for study.

## CASE REPORT

The following case is reported because it illustrates the importance of a careful and thorough investigation in every child who presents any symptom which might

## FOREIGN BODY IN THE ESOPHAGUS

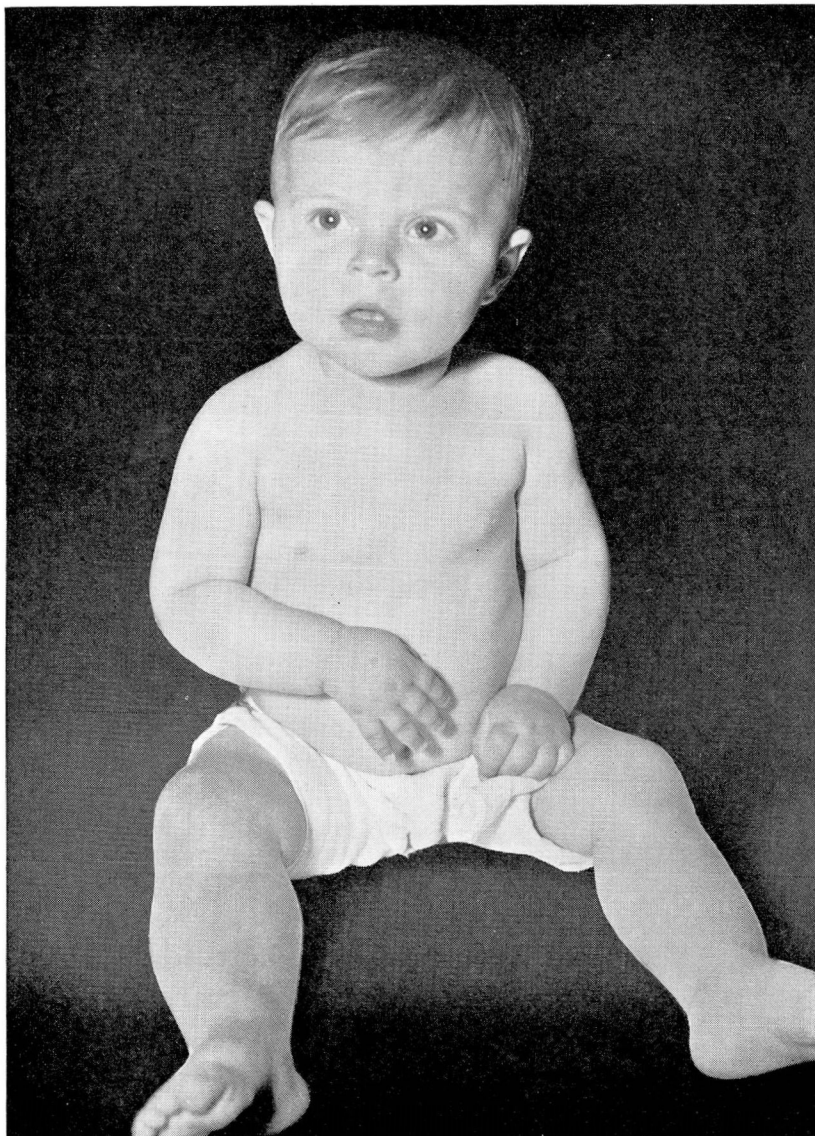


FIGURE 1: Photograph showing excellent condition of the patient even though she had subsisted on a liquid diet for almost a year.

be caused by a foreign body in the food or air passages. It also is of interest because of the remarkably excellent condition of the patient in spite of her inability to swallow anything but liquids for almost a year.

The patient, a white girl fifteen months of age, was admitted to the Cleveland Clinic Hospital on July 16, 1940, with the complaint of inability to swallow solid food since the age of four months. She vomited whenever she attempted to eat any solid food and had subsisted entirely on a liquid diet during this time. In

spite of this handicap, she was in excellent health, had gained weight steadily, and had no illnesses of any kind. Fluoroscopic examination, done that day by the referring doctor, revealed a ring in the upper end of the esophagus.

Examination showed a well nourished, active and healthy infant (Fig. 1). The nasal passages were clean and clear, the tonsils were small and submerged, and there was no inflammation in the pharynx. The external auditory canals contained a small amount of cerumen. Both drums were of good lustre and transparency. The chest showed good and equal expansion. The lungs produced normal resonance and breath sounds throughout. The heart was not enlarged, and the heart sounds were normal.

Roentgen examination showed a metal ring with a setting just above the level of the aorta. The broad axis of the ring was at right angles to the sagittal plane (Fig 2 A).

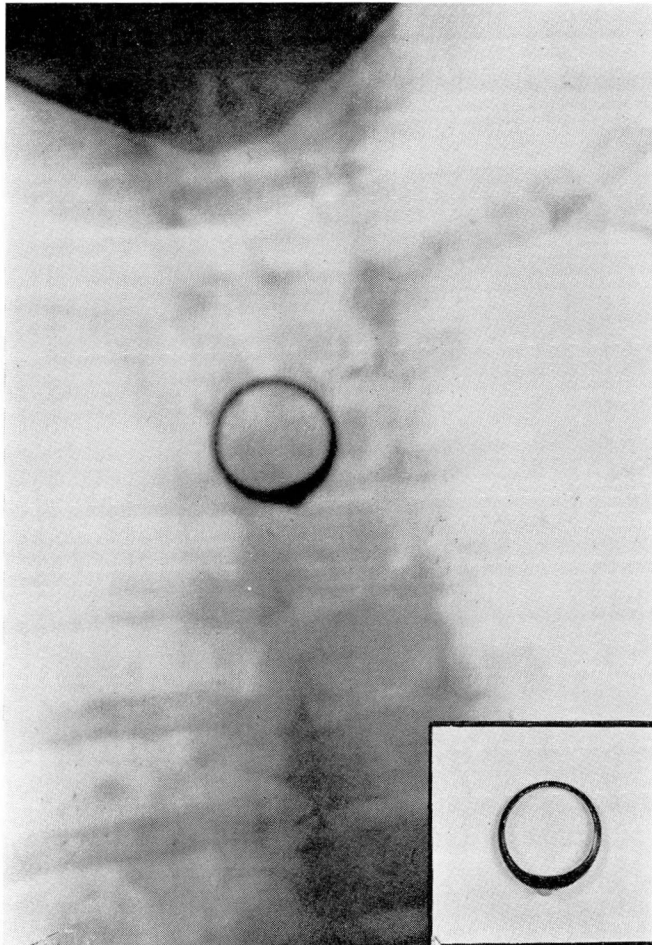


FIGURE 2: A. Roentgenogram showing ring just above the level of the aorta.  
B. Photograph of the black, tarnished, gold ring removed from the esophagus of this patient.



## FOREIGN BODY IN THE ESOPHAGUS

A Hasslinger 8.5 mm. esophagoscope was passed easily without anesthesia. A black foreign body was visualized just above the level of the aortic arch. Although there was no evidence of inflammation of the mucosa, the esophagoscope met with definite resistance, preventing its reaching the foreign body. This suggested that some inflammation in the past may have produced scar tissue in the esophageal wall. As the end of the esophagoscope approached the ring, a fold of mucosa rolled up on the posterior wall to hide the ring from view. The esophagoscope then was withdrawn until the ring could be seen again. When the esophageal wall was pulled away during inspiration, the ring was grasped with a ring rotation forceps. A steady straight pull released the ring which was of black tarnished gold with a small blue stone setting (Fig. 2 B).

By evening, she was drinking freely. She also was eating crackers which she had been unable to swallow previously. There was no postoperative reaction. When last seen, she still was timid about eating bread and other solid food, but was taking a soft diet without any difficulty. A barium esophagram subsequent to the removal of the ring showed no evidence of stricture. The child is anatomically capable of swallowing solid foods but is not yet psychologically prepared to accept them.