

LICHEN NITIDUS

A Report of Two Cases, with an Unusual Finding of Melanin in Giant and Epithelioid Cells in One Case

GEO. H. CURTIS, M.D.

Lichen nitidus was first described in 1907 by Pinkus¹ who reported nine cases, all men. The principal clinical characteristics of the disease are small discrete papules no larger than a pinhead, having a flat surface, being round or vaguely polygonal shaped, bright pink in color, and distributed on the penis, chest, and arms. In 1909 Arndt² reported twelve cases, all with lesions on the penis, and in one case, on the buccal membrane also. Kyrle and McDonagh³ reported a case in England in 1909, Sutton⁴ reported a case in the United States in 1910, and Civatte⁵ reported the first case in France in 1911.

Including the two cases in this report, I have been able to find reports of only ninety-five cases of lichen nitidus in the English, French, and German literature. The disease is uncommon, but because of the lack of symptoms which otherwise would announce its presence, it is probably more common than supposed.

In a review of the literature, Niles⁶ presented three theories for the etiology of lichen nitidus: (1) Tuberculous, because of a clinical and histologic association between tuberculosis and lichen nitidus in some cases, (2) a variety of lichen planus because, in other cases, there is a clinical and histologic resemblance between the two, and (3) in still other cases, lichen nitidus has the independent clinical and histologic picture of an inflammatory granuloma of unknown cause.

The evidence for tuberculous etiology includes: positive tuberculin reactions and an accentuation of the lesions (one case)⁷; the presence of tuberculosis elsewhere in the body and on the skin; the finding on microscopic examination of acid-fast granules in the lesions of lichen nitidus (one case); a certain histologic similarity between cutaneous tuberculous lesions and lichen nitidus; and finally, the disappearance of the lesions under tuberculin therapy (one case)⁸. As evidence against a tuberculous etiology, all animal inoculations have given negative results; the lesions may be present for years without change; the penis (an area almost always free from other forms of cutaneous tuberculosis) is a site of predilection; caseation or necrosis in the lesions, as is usually seen in tuberculosis cutis, never occurs; and the disease often occurs in individuals who present no evidence of tuberculosis.

Barber⁹, Dowling¹⁰, Haynes and Hellier¹¹, Ellis and Hill¹², and others believe that lichen nitidus may be a variation of lichen planus. In the cases studied by them, lesions of lichen planus and lichen nitidus were coexisting, and it was impossible to determine whether some of the

LICHEN NITIDUS

lesions were lichen nitidus papules or lichen planus papules. Furthermore, some lesions varied histologically between typical lesions of each disease. In other cases, an attack of lichen planus followed shortly after the disappearance of a lichen nitidus eruption.

The consensus of most dermatologists is that lichen nitidus is an independent entity of unknown cause. The several diseases from which lichen nitidus must be differentiated, namely, lichen scrofulosorum, lichen planus, and verruca plana juvenilis in typical form, on careful examination, bear little or no resemblance to lichen nitidus in clinical or histologic characteristics. In the absence of a known cause for lichen nitidus, its relation to tuberculosis and lichen planus cannot be confirmed.

At first glance, lichen nitidus clinically resembles lichen planus to a moderate degree. The lesions usually are of pinhead size or smaller and have a glistening surface. They are sharply defined, circular or polygonal in outline, slightly raised above the level of the skin, pinkish in color, or of the same hue as the surrounding skin. Usually the papules have no relation to hair follicles, but by careful search, a papule surrounding a hair follicle is found occasionally^{13, 14}. Upon close examination, some of the papules are seen to be umbilicated, and usually occur in groups without coalescence of individual papules. The favorite sites for the lesions are the genitalia, the abdomen, breast, flexor surfaces of the elbows, wrists, and palms. The lesions or groups of lesions may be generalized and have been observed in the mouth, on the neck and on the soles. Barber¹⁴ described patches in generalized cases as being pityriasiform or psoriasiform, and reddish yellow, brownish yellow, or reddish violet in color. Subjective symptoms usually are absent, but there may be slight itching. The disease is chronic, although it may disappear spontaneously.

Because of an unusual finding of pigment in the microscopic examination of lesions in one case, and because in both cases the eruption disappeared within a few months under superficial roentgen therapy, the following cases are reported.

REPORT OF CASES

Case 1: A negro, twenty-five years of age, came to the Clinic on February 20, 1940, complaining of an eruption on the penis, trunk, and extremities which he first noticed three months previously. At times, the lesions itched slightly. Before his mother's death from pulmonary tuberculosis in 1926, he had been in close association with her. Since then, he had had a number of examinations for tuberculosis at the city health clinics, but no evidence of tuberculosis was found.

General physical examination showed a well developed, well nourished young negro of sthenic habitus without abnormalities. A roentgenogram of the chest showed no evidence of tuberculosis.

The striking feature of the eruption was the numerous discrete papules, all of

the same size and somewhat smaller than a pinhead, evenly and thickly distributed on the skin of the penis (Fig. 1). The papules were sharply defined, roughly

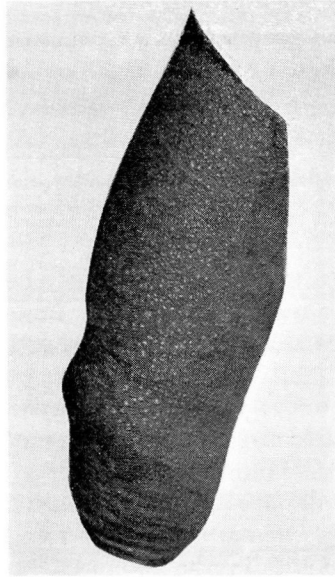


FIGURE 1: Case 1. Lichen nitidus.

circular, elevated slightly above the skin surface, and of a paler hue than the normal skin color. Their surfaces were flat and glistening, and some showed tiny central depressions. Careful examination of the eruption on the rest of the body showed the papules to be interfollicular. On the neck, trunk, and extremities, the papules were aggregated into irregularly shaped groups of as few as twelve papules up to more than a hundred. The groups were irregularly distributed on the neck, shoulders, chest, back, abdomen, arms, about the elbows, forearms, dorsa of the hands, thighs, and legs. At the elbows the grouping was triangular in shape with the vertex toward the wrists. The face, scalp, buccal mucous membrane, fingers, palms, and soles showed no lesions.

The hemogram and urinalysis were normal. The fasting blood sugar level was 85 mg. per 100 cc. and Wassermann and Kahn tests of the blood gave negative reactions. Quantitative intracutaneous tests with K.O.T. 1:1000, 1:10,000, 1:100,000, 1:one million, 1:ten million, and 1:one hundred million showed elevated, red, edematous papules ranging from 2 cm. to 0.5 cm. in diameter respectively, surrounded by a less inflamed but edematous halo.

A small piece of skin containing several papules was removed from the abdomen for microscopic examination. The patient refused to allow a sufficient amount of skin to be taken for guinea pig inoculation.

A section (Fig. 2) of a papule stained with hematoxylin and eosin shows an inflammatory reaction confined entirely to the papillary region. In the intact epidermis above, the horny and granular layers are normal. The prickle cell layer is reduced from the normal thickness of four to six cells, to from two to

LICHEN NITIDUS

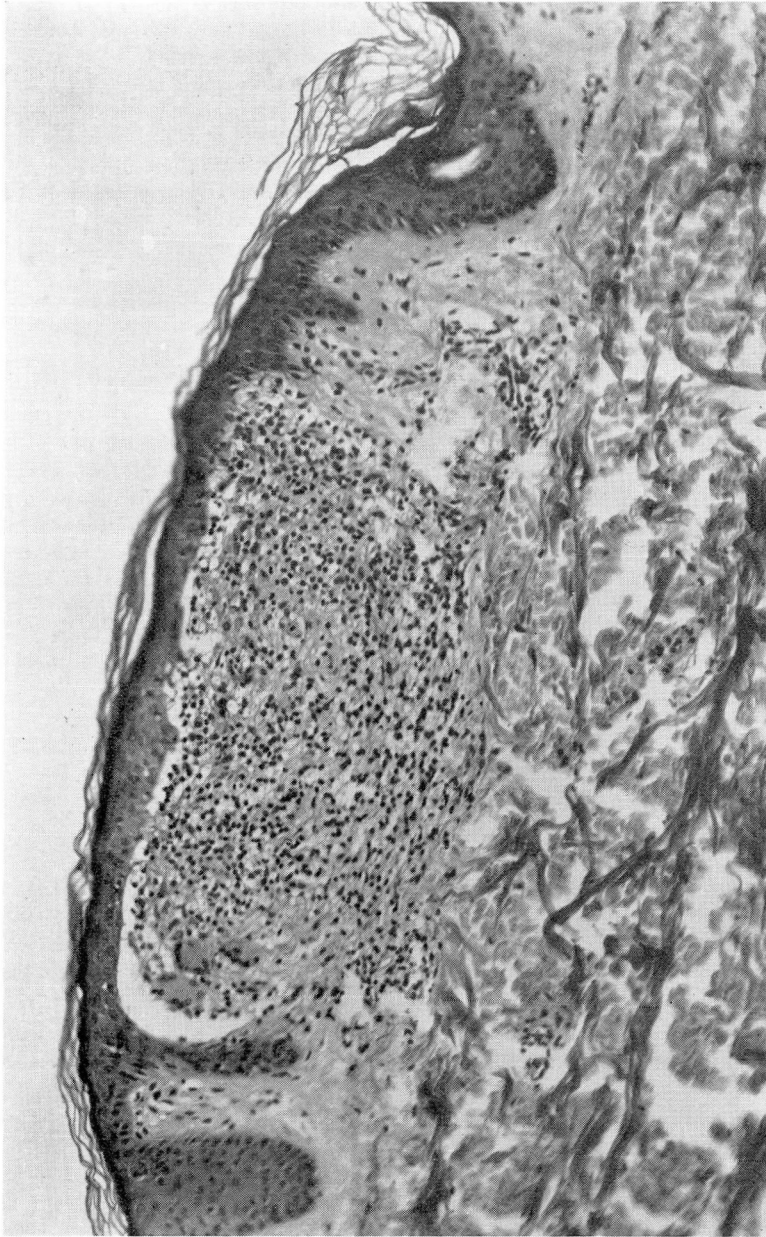


FIGURE 2: Case I. An interfollicular papule of lichen nitidus. Note the position of the granuloma in the papillary layer and giant cells. (x 150).

three cells, and the germinal layer is obliterated. The granuloma is flat, sharply circumscribed, and delimited on each side by a crescentic rete peg. It consists of edematous connective tissue in which a dense round cell infiltration is imbedded.

The architecture of the connective tissue and papillae is destroyed. A section stained for elastic tissue shows no elastic fibers in the inflammatory nodule. There is proliferation of fixed tissue cells; and a few epithelioid cells and proliferating capillaries are present. There are no eosinophils and only a few polymorphonuclear cells in the infiltrate. In the upper half (mostly the upper third) of the granuloma, there are a number of scattered cells containing melanin granules. In the left side of the granuloma, closely approximated to the epidermis, are three giant cells. In another section of a papule, a giant cell appears to lie almost wholly within the epidermis. The cytoplasm is completely filled with melanin granules. In sections of papules stained with a silver reducing stain, the pigment containing cells appear to be of two types: (1) cells resembling the chromatophores of irregular shape and containing coarse melanin granules as seen in normal papillae, and (2) cells containing fine melanin granules, resembling the basal cells of the epidermis.

In the corium and neighborhood of the granuloma, there is perivascular round cell infiltration of the same type and size as the round cells in the granuloma. The blood vessels are dilated but none shows endothelial proliferation. The deep corium and the subcutaneous tissue are normal.

In order to determine the relative efficacy of roentgen therapy and of an ointment containing 4 per cent each of salicylic acid and resorcinol in petrolatum⁴, the lesions on one half of the body were given eight superficial roentgen ray treatments of 75 r at weekly intervals, while to the lesions on the other half of the body, the ointment was applied twice daily for the same period of time. After the fifth roentgen ray treatment, the papules were reduced to a glistening scale-less macule. After the eighth treatment, the macules had almost disappeared.

During the eight weeks of treatment with the ointment, the papules remained unchanged, although the skin showed some keratolytic effect. This half of the cutaneous surface is being treated with roentgen ray therapy at the present time and the eruption is disappearing.

Case 2: A white woman, twenty-seven years of age, came to the Clinic on March 3, 1939, complaining of an eruption on her arms which had been present since December, 1938. It appeared first in the cubital fossae and rapidly spread distally over the volar surfaces of the forearms to the wrists. At times the eruption itched slightly. She was disturbed by the fact that, when her arms were in a dependent position, the eruption became bright red. In January, 1939, the eruption appeared in a few places on the abdomen.

There was no relevant family history of chronic diseases, and she had never been exposed to, nor had any symptoms or examinations relative to tuberculosis.

Physical examination showed a well developed and well nourished young woman of sthenic habitus. A roentgenogram of the chest showed no evidence of tuberculosis. She presented ill-defined, irregular coin-sized areas of brownish-red color on the volar aspect of the forearms, wrists, and one patch on the left arm near the anterior axillary fold (Fig. 3). A large patch occupied all of each cubital fossa. These patches were made up of numerous discrete, uniformly pinhead sized, flat brownish-red to skin colored papules. Some of the papules were polygonal but under a magnifying glass this was seen to be due to the lesions being situated at intersections of the cross markings of the skin. Others showed a slight scale and a tiny central depression. Most of the scaly papules, relatively few in number, were perifollicular. However, most of the papules were round, smooth, and glistening. Similar groups of papules were on the abdomen and dorsa of the feet. The rest of the cutaneous surface and the buccal mucous mem-

LICHEN NITIDUS

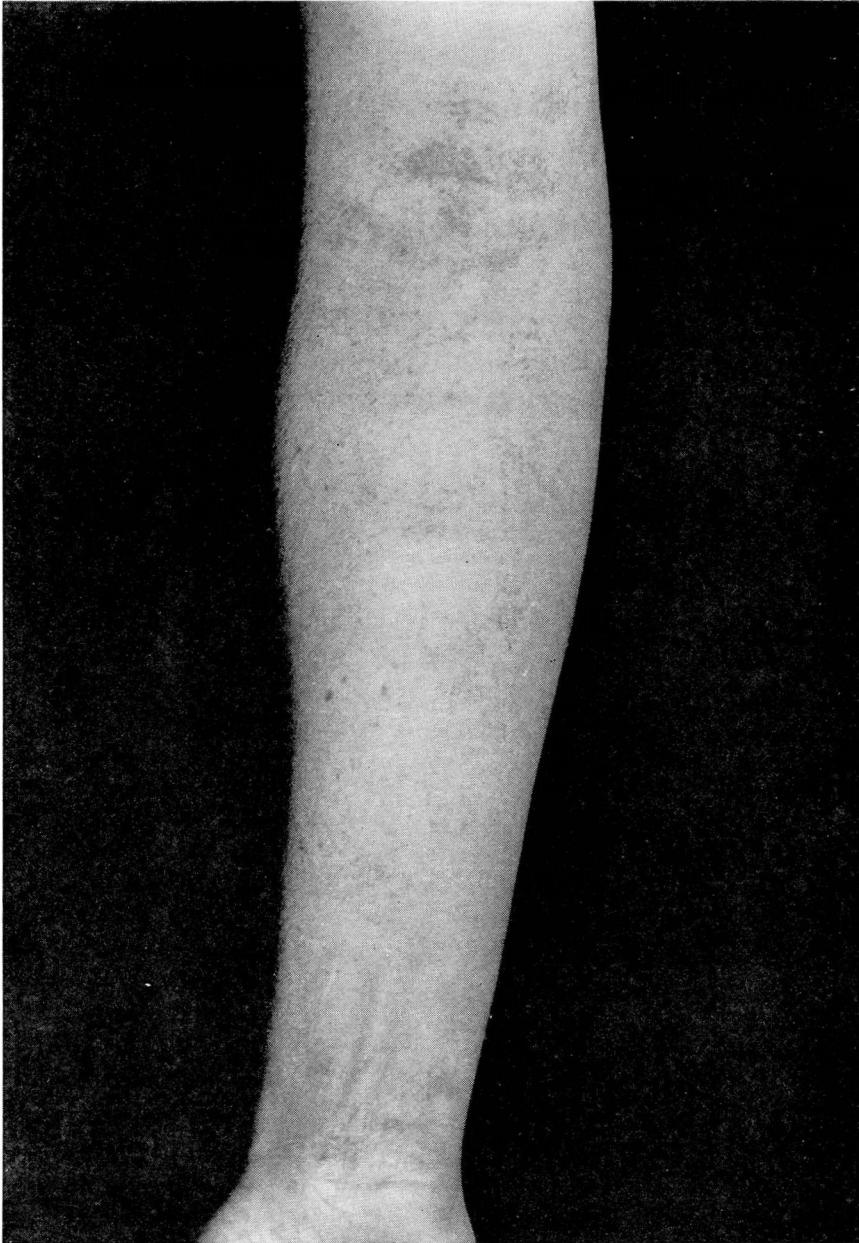


FIGURE 3: Case 2. Lichen nitidus.

brane showed no eruption. On diascopy, the papules were seen to be granulomatous.

The hemogram and urinalysis were normal. The fasting blood sugar level was 88 mg. per 100 cc., and Wassermann and Kahn tests of the blood gave negative

reactions. Intradermal tests with K.O.T. 1:100 showed a 2 plus reaction, while 1:10,000 and 1:100,000 were negative.

A small piece of skin containing several papules was excised from the left forearm for microscopical examination. A section containing a perifollicular papule (Fig. 4) surrounding a hair follicle shows an inflammatory reaction, the greater part of which is on the right side of the follicle. On both sides of the shaft, the granuloma extends downward past the mouths of the sebaceous glands to a point where the shaft disappears from the section. Except for the downward prolongation along the follicle, the inflammatory reaction is confined to the papillary layer and sharply limited at the upper part of the corium. The epidermis above is intact. That part of the horny layer above the summit of the granuloma shows parakeratosis, below which the granular layer is absent. On either side of the parakeratosis, where the epidermis regains its normal appearance, the horny layer shows moderate hyperkeratosis and the cells of the granular layer reappear. There is a small hyperkeratotic plug in the follicle. The prickle cell layer is reduced to two or three cells in thickness while the germinal layer is obliterated by invading round cells.

The granuloma is roughly spherical, consisting of a small round cell infiltrate slightly more dense at the periphery, and made up of uniform size and type of cells. No polymorphonuclear leukocytes, eosinophils or plasma cells are present. The infiltrate is nested in an edematous connective tissue stroma with proliferating fixed tissue cells. At the very summit of the granuloma, there is a giant cell containing twenty-five nuclei, beneath which is what appears to be the remains of a rete peg, the continuity of whose cells is disrupted by the infiltrating round cells. There is an increased number of new formed capillaries. In the upper corium, there is perivascular round cell infiltration of the same type of cells as those in the granuloma. There is no endothelial proliferation but the blood vessels are dilated. The deep corium and subcutaneous tissue appear normal. Other inflammatory nodules in the papillae are identical with the one just described except for an absence of parakeratosis, hyperkeratosis, and giant cells. No pigment containing cells, except for a few chromatophores in the normal papillae, is seen in this or other sections studied.

The eruption was treated with five superficial roentgen ray treatments of 75 r each at weekly intervals. After the fourth treatment, the papules had almost disappeared. When seen a year later, the patient stated that within two weeks following the last treatment, the eruption disappeared entirely and has not recurred. A thorough examination of the skin showed no evidence of the eruption.

Briefly, the histologic characteristics of the papules in these two cases are of a sharply circumscribed granuloma, which has invaded and destroyed the basement membrane, germinal layer, and part of the prickle cell layer, limited to the papillary region. In young lesions, the granuloma is limited to a single papilla. Giant cells of the foreign body type may be found in most of the older lesions. The granulomas consist of edematous connective tissue stroma, proliferating fixed tissue cells, and a rather dense but evenly distributed small round cell infiltration. They may be situated on one side, or occasionally may surround a hair follicle. In a typical lesion, the inflammatory reaction is limited on either side by a somewhat crescentic and prolonged rete peg. Newly formed capillaries growing into the granulomas frequently are seen in older lesions.

LICHEN NITIDUS

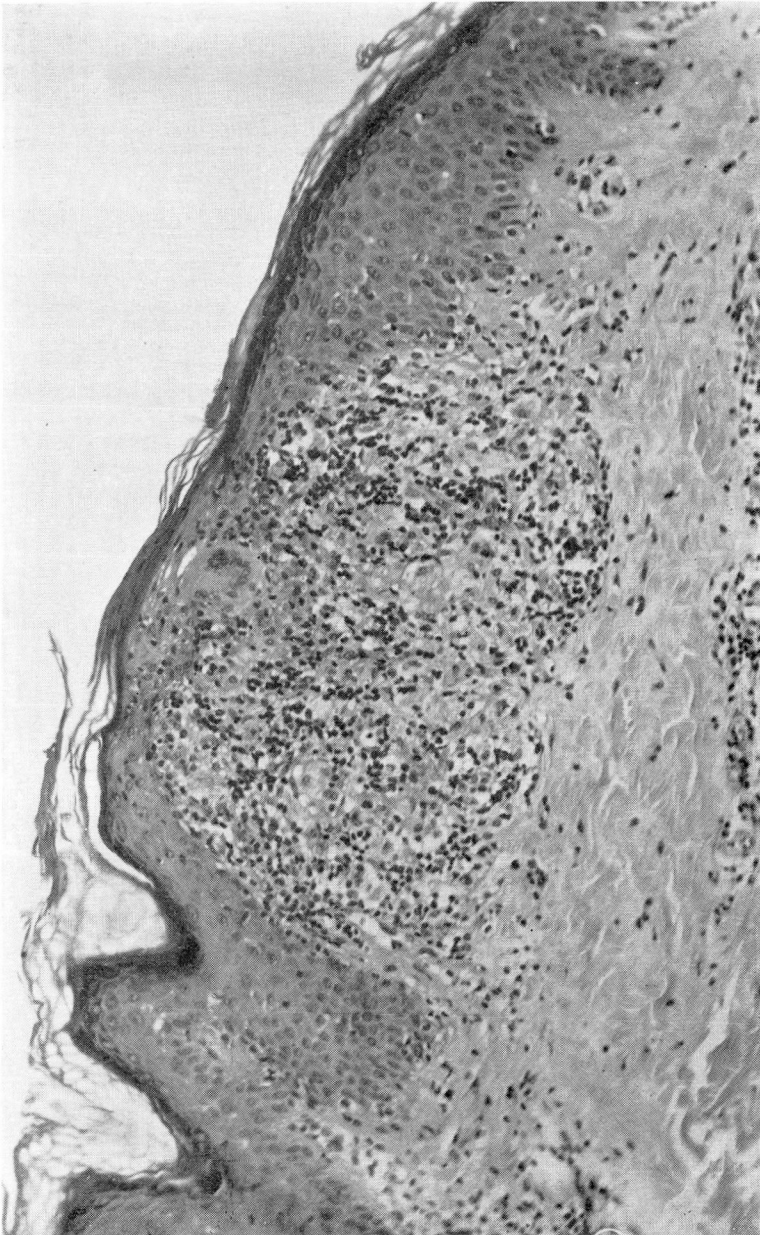


FIGURE 4. Case 2. Perifollicular lichen nitidus papule showing only that part on one side of a follicle. Note the giant cell lying almost wholly within the epidermis. (x 150).

McCarthy¹⁵ mentions pigmentation of giant and other cells in the cells in the granuloma. Trimble and Maloney¹⁶ did not mention this finding in their two patients who were negroes. The position of the giant cells

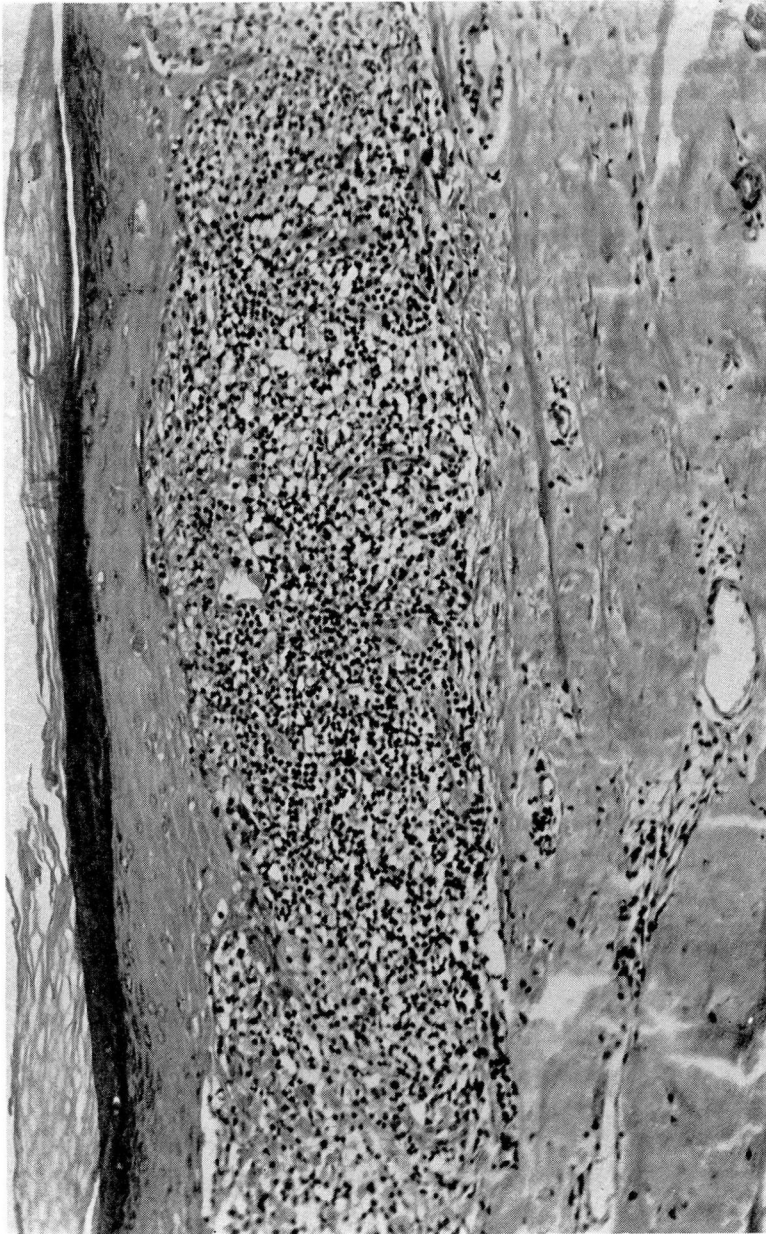

FIGURE 5: A mature lichen planus papule. Note the position of the infiltrate in the papillary layer and corium in contrast to figures 2 and 4. (x 150).

and the small melanin granules in their cytoplasm in Case 1 suggests that they could be of epidermal origin. The large number of cells in the upper part of the granulomas containing fine granular melanin are

LICHEN NITIDUS

morphologically similar to basal cells. In contrast, the more deeply situated irregular shaped cells which contain coarse melanin granules are morphologically identical with chromatophores in the normal papillae.

DIAGNOSIS

In Case 1 the history of intimate exposure to tuberculosis, a high degree of skin sensitivity to tuberculin, and the presence of giant cells in the papules suggested a relationship between the eruption and tuberculosis. On the other hand, a positive tuberculin reaction is common in adults who show no evidence of tuberculosis in the anamnesis and/or on repeated examinations as in this case. The lack of histologic evidence for the lesions being tuberculous has been discussed above. Although it was not possible to obtain tissues for animal inoculations or to make exhaustive studies of serial sections for acid-fast bacilli, the negative results recorded in the literature would seem to indicate that these procedures in this case also would have given negative results. A search for tubercle bacilli in a few microscopical sections gave negative results.

As for the cutaneous manifestations of tuberculosis, including the tuberculids, lichen scrofulosorum more closely resembles lichen nitidus. However, the former usually occurs in children with frank tuberculosis, while lichen nitidus is generally seen in adults, usually without evidence of tuberculosis. The eruption of lichen scrofulosorum tends to group and is decidedly scaly and perifollicular with spreading borders made up of the papules and clearing centers. Only a few of the papules of lichen nitidus are perifollicular (none were found in this case). When the papules become so closely aggregated in scaly patches, they usually retain their individuality and the patches have not been observed to clear in the center.

Histologically, lichen scrofulosorum presents a variable picture with an almost entire dissemblance to a typical tubercle with central necrosis. Predominating is a perifollicular infiltrate containing many lymphocytes, few if any giant cells, and a few epithelioid cells. In the plane type usually occurring in the vicinity of the perifollicular type, the infiltrate is deeper in the corium than in lichen nitidus, does not infiltrate the epidermis, and is not so sharply outlined nor uniform as lichen nitidus. Tubercle bacilli have been found in the lesions of lichen scrofulosorum.

In Case 2, a small number of scaly perifollicular papules were interspersed between more numerous interfollicular papules, and the groups of lesions were not scaly. This patient presented no clinical evidence of tuberculosis and the histologic picture of the papules was characteristic of lichen nitidus. Aside from the presence of giant cells, the granulomas show no whorls of epithelioid cells or central necrosis. The rather dense round cell infiltration is evenly distributed. In a typical hard tubercle

of almost microscopic size, there is central caseation surrounded by concentrically arranged epithelioid cells which are in turn surrounded by lymphocytic infiltration. According to MacCallum¹⁸, "There is absolutely no provision for a blood supply in such nodules (tubercle), and those capillaries which were present at that point before are found to be obliterated, so that if an organ studded with tubercles be injected through an artery with blue gelatin, each tubercle will stand out white against a blue background." New capillaries were seen in all the mature granulomas studied. Therefore, it seems that the typical well developed granuloma of lichen nitidus can readily be distinguished from a tuberculous nodule.

In these two cases it was not difficult to differentiate between the eruption present and lichen planus. In lichen planus, pruritus usually is pronounced, and both patients were reminded of the slight itching only when asked. In Case 2, the brownish-red color and vaguely polygonal papules might be confused with lichen planus papules of the same size, but, although the lesions of lichen nitidus are uniformly the same size, lichen planus papules vary in size from a millet seed to a small pea, and the larger lesions have a distinct lilac to purplish color. Although both eruptions tend to groupings of the papules, in lichen nitidus the papules retain their individuality while in lichen planus they coalesce to form figures. The white lines or dots (Wickham's striae) in lichen planus papules are not present in lichen nitidus. Lichen planus rarely, if ever, presents an involvement of the penis as does lichen nitidus (Fig. 1), but often occurs on the glans with the formation of annular lesions. Lichen nitidus is rare in the mouth while a lichen planus involvement of the mouth is common. Lichen planus, on involution, usually leaves pigmentation which may persist for months, but lichen nitidus leaves no trace.

Histologically, very small lesions of lichen planus may resemble lichen nitidus, but in well developed lichen planus papules there is no resemblance (Compare Figs. 2, 4, and 5).

Verruca plana juvenilis offered the least difficulty in the diagnosis as the papules have a warty surface which is easily removed with a curette while lichen nitidus papules have to be picked out. The verrucae vary in size and in color from light to dirty brown, and are less sharply defined.

TREATMENT

Several types of treatment have been used with success. In Sutton's case⁴ the lesions disappeared following the use of salicylic acid and resorcinol (See Case 1). Niles successfully used gold sodium thiosulfate in increasing doses from 25 to 100 mg. in his case. Fox¹⁶ and MacKee¹⁷ caused the eruption to disappear with superficial roentgen therapy.

LICHEN NITIDUS

SUMMARY AND CONCLUSIONS

Two cases of lichen nitidus are reported with a description of the clinical and histologic features. In one case, an unusual finding of melanin in giant and epithelioid cells is described. The clinical and histologic differences between lichen nitidus, cutaneous tuberculosis, and lichen planus are pointed out; and, in the absence of the known cause, it is concluded that lichen nitidus is not related to the latter two diseases. In both cases the eruption disappeared after five to eight roentgen ray treatments, and in one case, which has been under observation for fourteen months, the eruption has not recurred.

REFERENCES

1. Pinkus, F.: Über eine neue Knötchen formige Haut Eruption, *Behandl. der Berlin Dermat. Gesellsch.*, 12:85:11, 1907.
2. Arndt, G.: Beiträge zur Kenntnis des Lichen Nitidus, *Dermat. Ztschr.*, 16:551, 1909.
3. Kyrle, J. and McDonagh, J. E. R.: Lichen nitidus, *Brit. J. Dermat.*, 21:339-346, (November) 1909.
4. Sutton, R. L.: Lichen nitidus, *J. Cutan. Dis.*, 28:597-605, 1910.
5. Civatte, M. A.: Lichen nitidus coexistent avec un lichen plan, *Bull. Soc. Fr. de derm. et syph.*, 22:65-67, 1911.
6. Niles, H. D.: Lichen nitidus; report of case treated with gold sodium thiosulfate and review of literature, *Arch. Dermat. & Syph.*, 22:687-697, (October) 1930.
7. Chatellier, L.: Sur la tuberculide licheniforme et nitida, *Ann. de derm. et syph.*, 7:340-351, 1918-19.
8. Gougerot, H. and Burnier, H.: Un cas de "lichen nitidus" generalise gueri par la tuberculinothérapie, *Bull. Soc. Fr. de derm. et syph.*, 41:650-652, (April) 1934.
9. Barber, H. W.: Discussion on a case of lichen nitidus presented by K. Sibley, *Brit. J. Dermat. & Syph.*, 43:136-138, 1931.
10. Dowling, C. E.: Discussion on a case of lichen nitidus presented by K. Sibley, *Brit. J. Dermat. & Syph.*, 43:136-138, 1931.
11. Haynes, H. and Hellier, H.: Lichen nitidus associe a du lichen plan et a de la lichenification verruqueuse, *Ann. de dermat. et syph.*, 8:192-214, (March) 1937.
12. Ellis, F. A. and Hill, W. F.: Is lichen nitidus a variety of lichen planus? *Arch. Dermat. & Syph.*, 38:569-573, (October) 1938.
13. Michelson, H. E.: Lichen nitidus, *Arch. Dermat. & Syph.*, 7:763-772, (June) 1923.
14. Barber, H. W.: Lichen nitidus, *Brit. J. Dermat.*, 38:143-156, (April) 1926.
15. McCarthy, L.: *Histopathology of Skin Diseases*, St. Louis, C. V. Mosby, 1931.
16. Fox, H.: Discussion: Trimble, W. B. and Maloney, E. R.: Lichen nitidus, *Arch. Dermat. & Syph.*, 7:452-461, (April) 1923.
17. MacKee, G. M.: *X-rays and Radium in the Treatment of Diseases of the Skin*, Philadelphia, Lea and Febiger, p. 744, 1938.
18. MacCallum, W. G.: *A Textbook of Pathology*, 4th ed., Philadelphia, W. B. Saunders Co., p. 606, 1928.