

PENTOTHAL SODIUM ANESTHESIA IN PNEUMO-ENCEPHALOGRAPHY

A Preliminary Report

W. JAMES GARDNER, M.D., WM. A. NOSIK, M.D., and
ROBERT E. BRUBAKER, M.D.

In view of the increasing application of intravenous anesthetics to general surgical operations, and of the favorable reports of their use in some neurosurgical procedures ^{1, 2}, a series of pneumo-encephalograms, employing pentothal sodium, has been done. In a series of twenty-five consecutive cases, pentothal sodium anesthesia has proved to be well adapted to this procedure from the standpoint of the patient, the anesthetist, and the operator.

PROCEDURE

A hypodermic injection of morphine sulfate, grains 1/6, and atropine sulfate, grains 1/150, is given forty-five minutes preoperatively. The patient is taken to the encephalography room, secured in the operating chair, and the field prepared and draped. The lumbar interspace selected for the subsequent introduction of the encephalogram needle is then infiltrated with 0.75 per cent novocaine. This pre-anesthetic infiltration allows a smoother and lighter anesthesia as the stimulation from the insertion of the needle is avoided.

A suitable vein in the arm or hand is selected for the injection of the anesthetic. The needle is connected with a two-way stopcock, one inlet of which receives the pentothal solution, and the other a drip of normal saline which continuously clears blood from the needle between the intermittent injections of the anesthetic. After the induction of anesthesia, the encephalogram needle is inserted into the lumbar interspace which already has been infiltrated with novocaine, and the exchange of cerebrospinal fluid and air is completed. The injection of the anesthetic then is discontinued and roentgenograms are taken immediately. The induction of anesthesia is carried out with the patient sitting in the operating chair. Figure 1 shows the set-up for the procedure and the administration of the anesthetic.

CLINICAL DATA

The twenty-five patients presented were from fourteen to fifty-eight years of age. Eighteen patients were in the third and fourth decades.

The post-encephalographic diagnoses were: grand mal, ten cases; post-traumatic encephalopathy, four cases; brain tumor, three cases; unverified brain tumor, two cases; major hysteria, three cases; and one case each of cerebral scar, cerebral vascular disease, and Alzheimer's disease.

The amount of pentothal sodium injected as a 5 per cent solution varied from 0.22 gram to 1.5 grams, the average being 0.7 gram.

PENTOTHAL SODIUM ANESTHESIA

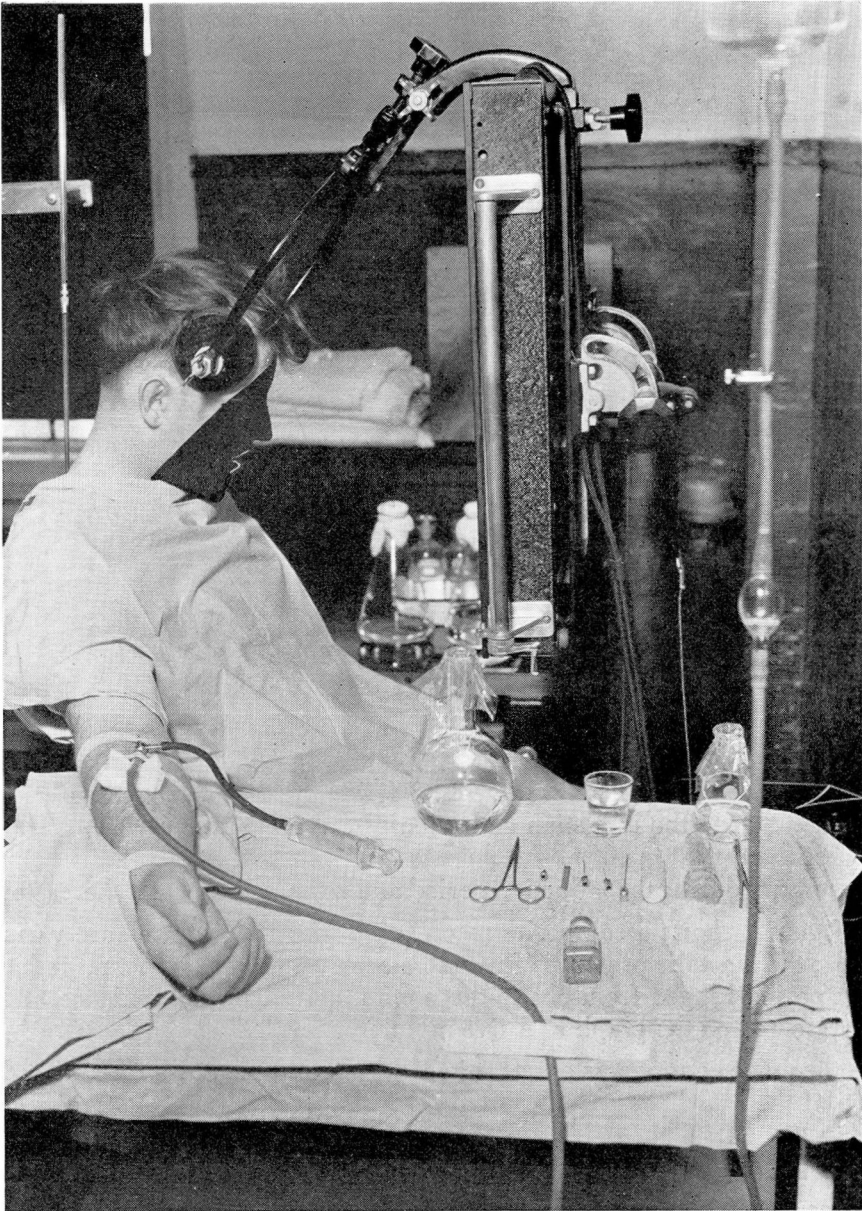


FIGURE 1. Set-up for the procedure and the administration of the anesthetic.

The blood pressure charts of the majority of the patients showed a characteristic curve. During induction of the anesthesia, both systolic and diastolic pressures fell 5 to 25 mm. of mercury. However, at the beginning of the procedure or during its course the pressures rose to the

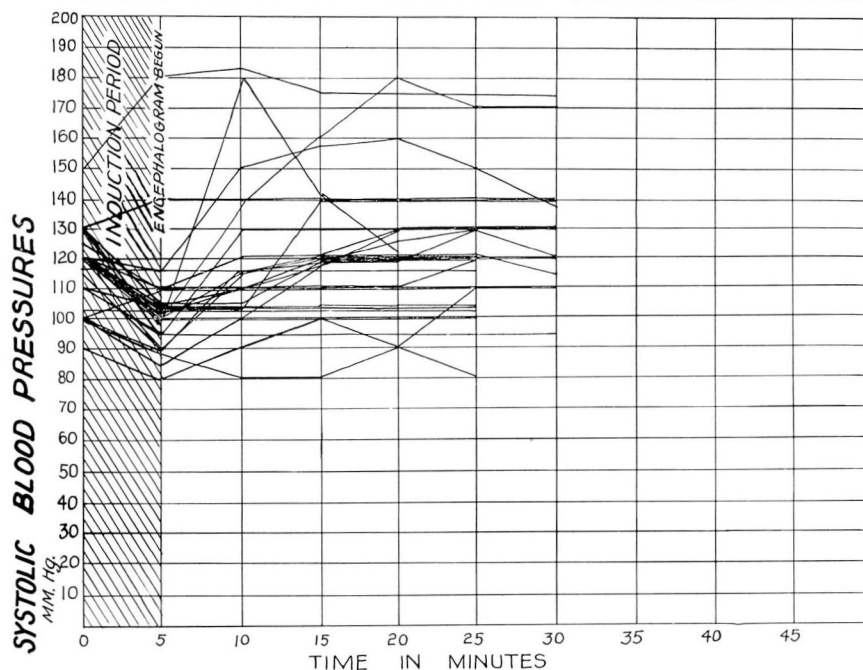
BLOOD PRESSURE VARIATIONS (PENTOTHAL SODIUM ANAESTHESIA)

FIGURE 2: Composite recording of the systolic pressure variations.

pre-anesthetic level or above it. In a few cases the blood pressure fell slightly during the induction and remained at a constant level. In two cases there was no change. In two cases the pressure rose 10 and 30 mm. of mercury during the induction period and remained constant thereafter.

Figure 2 shows a composite recording of the systolic pressure variations; the diastolic pressures fluctuated accordingly. The actual induction period ranged from one to three minutes, but for convenience, it is represented on the graph as a five minute interval.

The pulse volume was constant in all cases, and the pulse rate, regardless of the blood pressure fluctuations, rarely varied more than plus or minus ten during the induction period and the subsequent procedure.

Marked respiratory depression was not noted, the rate of injection of the pentothal sodium solution being carefully regulated to prevent this occurrence. Pallor appeared in one case, but no other untoward anesthetic effects resulted.

The recovery period and convalescence were uneventful in each instance. Nausea and vomiting occurred in one case, but in the remaining twenty-four cases the postanesthetic course was quiet and comfortable. It is our impression that post-encephalographic headache after the

PENTOTHAL SODIUM ANESTHESIA

use of pentothal sodium anesthesia is distinctly less annoying to the patient than after the use of other agents.

CONCLUSIONS

Pentothal sodium satisfies the desiderata of anesthesia in pneumo-encephalography—a smooth induction period, minimal changes in blood pressure, pulse, and respirations due to the anesthetic itself, and a quiet recovery period. We believe that its continued use in this procedure is justified when no contraindications to the type of anesthesia exist.

REFERENCES

1. Tuohy, E. B.: Anesthetic procedures used at the Mayo Clinic. II. For neurologic surgery, Proc. Staff. Meet. Mayo Clin., 13:377-379, (June 15) 1938.
2. Ruth, H. S., Tovell, R. M., Milligan, A. D. and Charleroy, D. K.: Pentothal sodium: Is its growing popularity justified? J. A. M. A., 113:1864-1868, (November 18) 1939.