

SOME GASTROSCOPIC OBSERVATIONS IN GASTRIC ULCER

JOHN F. RENSHAW, M.D.

Gastroscopy is a routine procedure in all cases of gastric ulcer seen in the Section on Gastro-intestinal Diseases at the Cleveland Clinic.

We believe that every case of gastric ulcer should have gastroscopic examinations because gastroscopy serves several purposes. First, it is one more way of confirming the clinical and roentgen diagnosis of benign gastric ulcer. Second, by gastroscopy one is better able to follow the course of the disease and to observe completed healing. Third, the persistence or healing of an associated gastritis may be observed. Fourth, when the clinical or roentgen evidence is not sufficient to make a definite diagnosis of ulcerating carcinoma, gastroscopy may add enough additional data to justify a definite diagnosis of a benign or malignant lesion. We believe, further, that gastroscopy should be done in all patients with negative roentgen findings but with definite gastro-intestinal symptoms, especially the ulcer-like syndrome. The following cases represent typical examples of the more common problems which are encountered.

The value of direct visualization in confirming or contradicting the roentgen and clinical diagnosis is shown in the following case.

Case 1: This patient was a forty-eight year old nurse whose presenting symptom was "stomach trouble." She had had distress intermittently for twenty years, characterized by bloating, belching, and occasional sour regurgitations, coming on half an hour after eating. At times there was relief from the use of soda, and at other times a bowel movement would give relief. Laxatives were used frequently.

Physical examination and the routine laboratory tests were negative. The free hydrochloric acid reached a level of 35 units and the total acid 46 units, forty-five minutes after the administration of an Ewald meal.

The first roentgen examination revealed a normal gall-bladder and duodenum. The colon was typical of a spastic or irritable colon, the left half being spastic and the right half atonic. However, an encircling type of filling defect in the pars pylorica due to neoplasm was reported (Fig. 1a).

At gastroscopic examination three days later, the entire stomach was well visualized. The antrum appeared lumpy and thickened and no peristalsis other than one or two very shallow waves was noted. At the lesser curvature of the body, a benign gastric ulcer was seen (Fig. 1b). The gastroscopic diagnosis was benign gastric ulcer on the angulus and severe hypertrophic gastritis.

The patient was placed on ulcer management. Three weeks later the roentgenograms were repeated and reported to be normal. At gastroscopy, however, the ulcer was still seen. The entire antrum was excellently visualized and there was definitely no evidence of malignancy (Fig. 1c). Final gastroscopic examination was done five weeks later, at which time a small, yellowish-white scar was seen at the site of the ulcer.

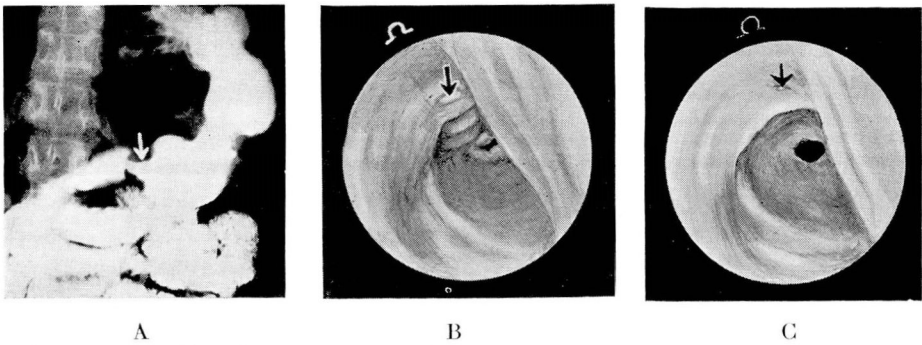


FIGURE 1: a. Encircling type filling defect of antrum.
 b. Small gastric ulcer, entire antrum including lesser curvature visualized, no evidence of carcinoma.
 c. Ulcer almost healed after three weeks of treatment.

(Permission of W. B. Saunders Co.)

This patient had an atypical history of ulcer. The clinical picture was compatible with the roentgen diagnosis of neoplasm but the first routine gastroscopic examination revealed the diagnosis to be benign gastric ulcer. Subsequent roentgen and gastroscopic examinations were complementary to each other and with both methods the lesion was seen to be benign. Furthermore, the completed healing of the ulcer was accurately observed. The gastritis remained unchanged so that a definite prognosis could be given to the patient. She must be careful of her diet and living habits all her life. And yet, in spite of all precautions, from time to time she will most likely have recurrent distress due to an acute exacerbation of the gastritis. It may be that persons with severe gastritis are more prone to recurrences of peptic ulcer. It also may be that carcinoma is more likely to develop in these patients than in those with normal stomachs. Therefore, we advocate repetition of the gastroscopic examination whenever the patient has recurrence of distress. Even if the patient is free from distress, we believe it is good "health insurance" to repeat the gastroscopic examination once a year.

The value of direct visualization of the lesion is demonstrated in Case 2. This time the roentgen diagnosis concurred with the gastroscopic diagnosis. The value of using both roentgen examination and gastroscopy to follow the course of healing of the ulcer is also emphasized in this case. Exhaustive studies by other workers, particularly Templeton and Schindler¹, have adequately shown this to be true. Both methods are required. One supplements the other, each providing certain information that the other does not.

Case 2: The patient was a forty-five year old restaurant proprietor whose chief complaint was "abdominal distress." The first attack occurred in 1914 and was followed by subsequent attacks in 1918, 1923, and the present one in 1939. Each attack had been characterized by dull, gnawing epigastric pain coming on three to four hours after eating, and relieved by food or rest.

The physical examination was negative. Urinalysis and routine blood tests were essentially normal. With an Ewald test meal, the free hydrochloric acid reached a level of 50 units and the total acid 72 units, forty-five minutes after the meal.

SOME GASTROSCOPIC OBSERVATIONS IN GASTRIC ULCER

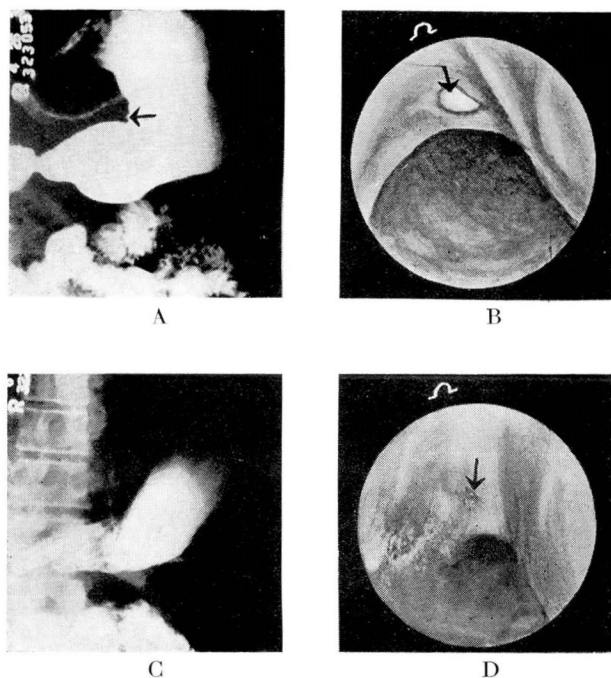


FIGURE 2: a. Suspicious ulcer niche in lesser curvature.
b. Typical benign ulcer.
c. Same case five weeks later.
d. Ulcer almost healed.

(Permission of W. B. Saunders Co.)

Roentgen examination of the gastro-intestinal tract revealed a normally functioning gallbladder without calculi, the duodenum was normal except for a diverticulum of the third portion, and the colon was spastic. The stomach, however, had a suspicious ulcer niche along the lesser curvature of the pars media (Fig. 2a).

The gastroscopic examination at that time demonstrated a typical, benign gastric ulcer on the angulus (Fig. 2b). Five weeks later the progress roentgen examination of the stomach reported a normal stomach and duodenum except for the diverticulum of the third portion (Fig. 2c). However, at gastroscopic examination on the same day, a small gastric ulcer still was present on the angulus and there was a mild, superficial gastritis (Fig. 2d). The examinations were repeated four months later, and a small, pinhead-sized scar was seen gastroscopically, while the roentgen examination was negative.

In Case 3, the need for doing gastroscopy when the roentgenograms are negative is emphasized. It is interesting to note that this patient had had three roentgen examinations of the gastro-intestinal tract, two of which were done after the ulcer had been demonstrated by gastroscopy, and yet all were negative. This is not a rare experience because in a recent review of thirty-five cases of benign gastric ulcer, three such ulcers were observed gastroscopically. The percentage may be even higher

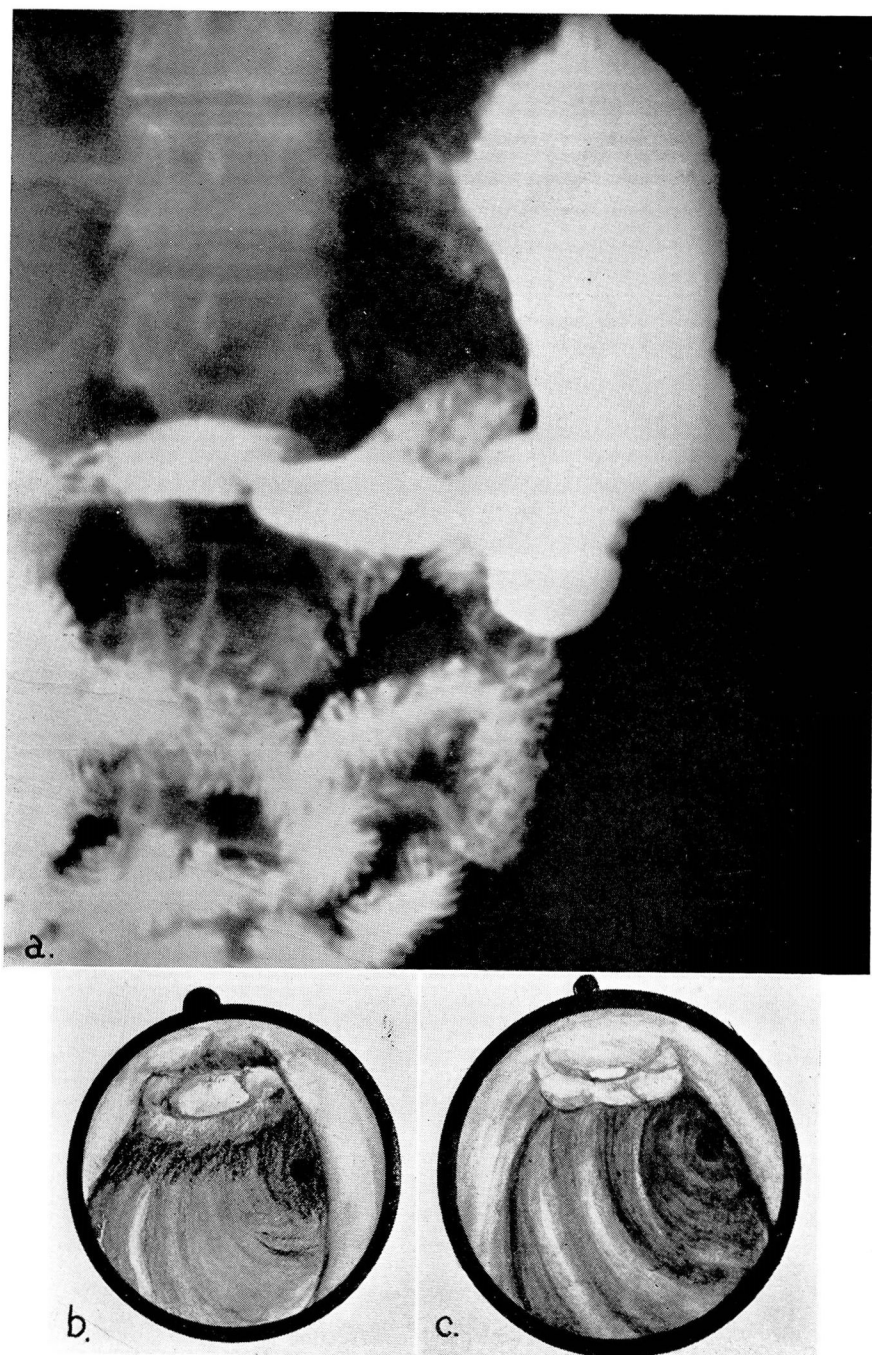


FIGURE 3: a. Normal roentgenogram.
b. Benign ulcer on angulus.
c. The same ulcer eight days later.

SOME GASTROSCOPIC OBSERVATIONS IN GASTRIC ULCER

because not all patients with negative roentgen studies have a gastroscopic examination, although they should. Likewise, those same patients are not submitted to exploratory laparotomy, so there is no way to check the negative roentgen findings. Of course, the simplest method, as far as the stomach is concerned, is to do a gastroscopic examination.

Case 3: This patient was a man, thirty-two years of age, who was a spinner in a rayon mill. His chief complaints were a pain in the back, and pain and gas after eating. The present illness began three years previously when dull, localized epigastric pain developed one and a half to two hours after eating. The pain was always relieved by taking some food. On a diet and Amphojel, he had had relief for six to seven months. However, distress recurred shortly after disregarding his diet. He was finally admitted to another hospital for diagnostic study. The roentgen examination revealed normal findings but gastroscopy revealed an ulcer. After twenty days of hospitalization the patient was discharged and was free from symptoms for five months. When the pain recurred, various self-prescribed patent medicines were tried for several months, without much relief. Pain finally developed in the lower dorsal spinal region one and a half to two hours after meals. Frequent feedings seemed to be the only method that gave relief.

Physical examination was negative. The skin was pale. The laboratory tests revealed an anemia and occult blood in the stool. There were 3,380,000 red cells with 74 per cent hemoglobin. Shortly after starting ulcer management, the stools remained negative for occult blood. The blood sugar level was normal and Wassermann and Kahn tests of the blood gave negative reactions. An Ewald test meal elicited 28 units of free hydrochloric acid and 40 units of total acid.

Roentgen examination of the stomach disclosed normal findings except for some hypertrophy of the rugae (Fig. 3a). The duodenum, gallbladder and colon were normal.

The gastroscopic examination revealed a well-defined, moderately deep ulcer on the angulus (Fig. 3b). Two portions of the edge were described as being "cherry red" and probably representing bleeding areas. This was undoubtedly the source of the occult blood in the stool and the cause of the anemia. After eight days of ulcer management, a progress gastroscopic examination (Fig. 3c) revealed a marked reduction in the size of the ulcer and no evidence of discoloration or bleeding about the crater. There was no occult blood in the stools after the second day of ulcer management.

Case 4 was a thirty-four year old clerk whose complaint was "stomach trouble" of two years' duration. He had had more or less daily discomfort for two years. It was characterized by epigastric pain which radiated to the back. The pain kept him awake at night, but once asleep, he would not awaken. Milk or soda did not give satisfactory relief, but milk of magnesia would. The pain became worse as the period after eating became longer. He also had much gas, belching, and general abdominal discomfort associated with nervous tension and constipation.

Physical examination revealed a prematurely gray, hyperkinetic young adult. The peripheral blood vessels were moderately thickened. There was epigastric tenderness but no masses or organs were palpated. The usual laboratory tests revealed normal erythrocyte and leukocyte counts; hemoglobin, blood sugar, and urinalysis were negative. The Wassermann and Kahn tests of the blood gave negative reactions. The basal metabolic rate was minus 14 per cent. Forty-five minutes after an Ewald test meal, the level of free hydrochloric acid was 57 units and the total acid was 75 units.

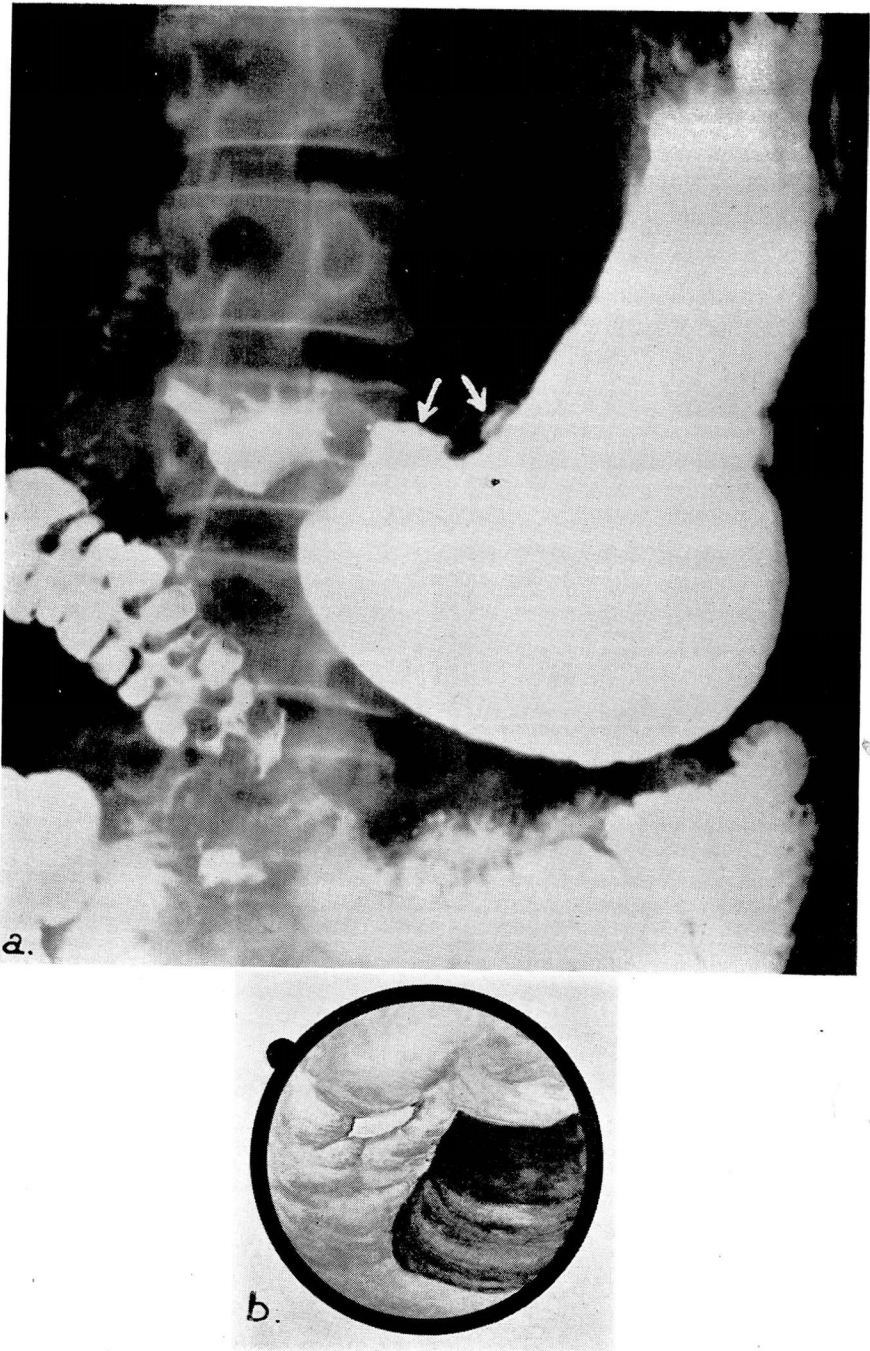


FIGURE 4: a. Large ulcer on lesser curvature of antrum and smaller one in body.
b. Benign ulcer near angulus in body. Ulcer in antrum not visualized. Hypertrophic gastritis was limited to upper parts of stomach.

SOME GASTROSCOPIC OBSERVATIONS IN GASTRIC ULCER

The roentgenologist reported pyloric obstruction with 60 per cent retention at the end of four hours (Fig. 4a) and 25 per cent at the end of twenty-four hours. An ulcer measuring 1.75 cm. was present in the lesser curvature of the distal pars pylorica. It was associated with marked spasm. There was also a suspicious small ulcer niche in the lesser curvature of the pars media. The gallbladder and colon were normal.

Gastroscopy revealed a benign ulcer on the angulus, associated with severe hypertrophic gastritis in the upper parts of the stomach (Fig. 4b). The pylorus and distal antrum, including the larger ulcer, could not be seen. Not infrequently the lesser curvature of the antrum cannot be visualized and this is one of the technical difficulties of gastroscopy. However, on further analysis of such cases, it has been our experience that gastroscopy usually contributes additional data in spite of nonvisualization of the prepyloric area. In the case reported, the smaller ulcer was definitely benign and the gastroscopic examination further strengthened the clinical opinion that the other lesion was benign.

The patient was hospitalized for strict management. The obstruction was completely relieved within four days. It is interesting to note, however, that the acidity and secretion during the night were difficult to control. It was found by hourly aspirations that two to three times the usual amounts of alkalis had to be used at night in spite of large doses of atropine sulfate. Once complete neutralization was obtained the patient was symptom-free. Two weeks later, progress examination revealed marked decrease in the size of the ulcers. The patient was discharged and instructed to continue the same program at home and to return in four weeks for progress roentgen and gastroscopic examinations.

We believe that every patient who has had a gastric operation for gastric or duodenal ulcer should have gastroscopic examinations if any distress recurs or persists. Case 5 illustrates the importance of this statement.

Case 5: This patient was a forty-five year old dye maker whose chief complaint was "pain in the stomach." The present illness began twenty years previously when a gastro-enterostomy was performed for duodenal ulcer. He was symptom-free for fifteen years, but for the past five years recurring intermittent attacks of pain appeared, characteristically localized to the epigastrium, and coming on two hours after meals. The pain was relieved by taking food or soda. At times, what he described as "farry stools" had been passed.

Physical examination was essentially negative except for some epigastric tenderness. The routine laboratory tests were normal.

The first roentgen examination in June, 1937, revealed a large penetrating gastric ulcer in the lesser curvature. Three weeks later, progress examination revealed that the ulcer niche was at least a third smaller. Examination four months later showed that the ulcer had not decreased further in size. However, in March, 1938, no niche was present. In July, 1939, sixteen months after the last examination, the patient returned because of recurrent distress. At that time roentgen examination (Fig. 5a) showed a normally functioning gastro-enterostomy with no demonstrable evidence of gastric ulcer other than convergence of folds at the pars media which was the location of the ulcer previously noted.

At gastroscopic examination (Fig. 5b), however, a definite gastric ulcer was seen in the hub of the converging folds. Associated with this was a marked deformity of the stomach due to the scarring and radiating folds. Severe gastritis was also present. The value of the gastroscopic examination in demonstrating the ulcer is apparent in this case.

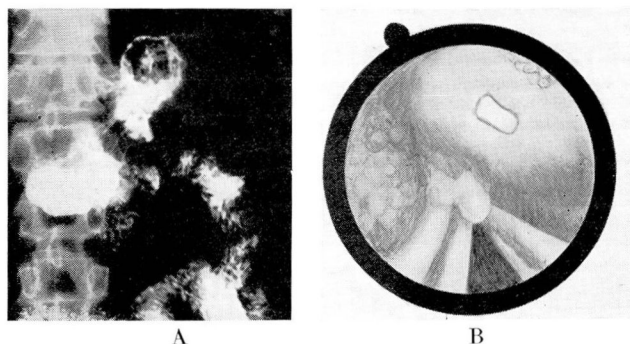


FIGURE 5: a. Normally functioning gastro-enterostomy, with no demonstrable evidence of gastric ulcer.
b. Ulcer crater on posterior wall portion of stoma with convergence of folds to apex and pseudopolypoid formation.
(Permission of W. B. Saunders Co.)

Laparotomy was performed on the following patient almost exclusively on the basis of the gastroscopic findings. The clinical picture was that of a benign gastric ulcer which had been present for the past twenty-five years, and the impression of the clinician was benign ulcer. The roentgen examination did not seem to agree with the clinical picture and the roentgen diagnosis was a qualified one of suspected neoplasm. Because of this seemingly incompatible history and roentgen diagnosis and because the ulcer was a gastric one, gastroscopy was indicated. The gastroscopic diagnosis definitely settled the issue.

Case 6: This patient was a woman thirty-nine years of age whose chief complaint was a gnawing pain half an hour after eating. She had been seen for the same complaint approximately eighteen months previously. At that time there was definite clinical and roentgen evidence of duodenal ulcer. She followed ulcer management for five months and was not seen again for eleven months, at which time she had a recurrence of her previous distress. This time, however, it was more severe and there had been a weight loss of thirty pounds.

Physical examination was essentially negative except for an elevated blood pressure. The systolic pressure was 186 mm. of mercury and the diastolic pressure 120 mm. of mercury. There was evidence of marked weight loss but no unusual abdominal findings.

The laboratory examination was essentially normal. The gastric acidity following an Ewald meal was 46 units of free hydrochloric acid and 65 units of total acid.

Roentgen examination revealed the stomach to be normal except for an area of apparent induration or a filling defect at the pylorus. The gastroscopist, however, reported the lesion to be a malignant ulceration in the prepyloric region. The patient was advised to enter the hospital but refused to do so. Ulcer management was carried out at home. The progress gastroscopic examination after one week of ulcer management revealed a benign prepyloric ulcer. The patient continued ulcer management and returned approximately five weeks later for further examinations. At this time the roentgen examination revealed a large atonic stomach obstructed at the pylorus. There was retention of 90 per cent of the barium in five hours. Gastroscopy at this time revealed pyloric obstruction but the ulcer was not seen. The gastroscopist, however, considered the lesion benign but could not definitely exclude a malignancy.

SOME GASTROSCOPIC OBSERVATIONS IN GASTRIC ULCER

A few days later gastric resection of the posterior Polya type was performed and the pathological report of the resected specimen was acute peptic ulcer with considerable inflammatory reaction.

This case demonstrates the necessity for repeated roentgen and gastroscopic examinations where evidence is not conclusive. Because of the uncertainty of the type of lesion, it was necessary to do repeated examinations, and it was only by this cumulative evidence that a diagnosis could be made.

CONCLUSIONS

The cases reported represent typical examples of some of the problems in the diagnosis of gastric ulcer. The need for doing a gastroscopic examination in conjunction with a roentgen examination in every case of known or suspected gastric ulcer is emphasized. It has been our experience that the gastroscopist's diagnosis concurs with the roentgenologist's diagnosis in 80 to 85 per cent of the cases. In the other 15 to 20 per cent which represent the doubtful or incorrect diagnoses made by either method of examination, the percentage of error was almost equally divided between the two. The failure in several instances was due to technical difficulties of the examination. Only a very few cases were incorrectly diagnosed because of improper interpretation and these failures were also divided equally between roentgenology and gastroscopy. Therefore, considering all factors, the roentgen examination remains the most important single examination in gastric ulcer, but gastroscopy is able to contribute such important data in many cases and to further supplement the roentgen examination in other cases, that it becomes an *indispensable adjunct* to the roentgen examination.

REFERENCE

1. Templeton, F. E. and Schindler, R.: Roentgenologic and Gastroscopic Studies in Chronic Gastritis and Peptic Ulcer, Am. J. Roentgenology and Radium Therapy, 41:354-367, (March) 1939.