

MYXEDEMA HEART

WILBUR E. FLANNERY, M.D. and A. CARLTON ERNSTENE, M.D.

The term "myxedema heart" was first employed by Zondek¹ in 1918 to describe a syndrome due to myxedema and consisting of enlargement of the heart, sluggish cardiac movements, electrocardiographic changes, and congestive myocardial failure. Although Zondek's observations have been fully confirmed, it has been well established also that myxedema only rarely is complicated by congestive heart failure. Enlargement of the heart and changes in the electrocardiogram occur commonly, however, and the term myxedema heart has now come to be applied to these changes even though evidence of congestive failure is absent. Organic heart disease may also be present, and because of this, the cardiac abnormalities in any case of myxedema must be shown to be amenable to therapy with thyroid substance before one can conclude that they were due to myxedema heart.

The present report is based on eight cases of myxedema in which electrocardiograms were made at the time the condition was first diagnosed (table I). In two of the cases the symptoms had developed three months and nine years, respectively, after thyroidectomy, while in the other six, the condition was of spontaneous origin. The age of the patients ranged from 37 years to 68 years. Five were women and three were men. The initial basal metabolic rates ranged between —24 per cent and —41 per cent, and the plasma cholesterol concentrations between 196 mgm. per 100 cc. and 248 mgm. per 100 cc. The resting pulse rate ranged from 48 to 78 beats per minute, the systolic blood pressure from 108 to 160 mm. of mercury, and the diastolic pressure from 70 to 100 mm. of mercury.

Roentgenograms of the chest were made in five cases before the institution of treatment, but in only two of these were additional films made at a later date. In four of the five cases the transverse diameter of the heart shadow exceeded one-half the internal diameter of the chest by 0.6 cm. to 1.5 cm. In the other case, cardiac enlargement appears to have been present also for the transverse diameter of the heart shadow after four months of treatment with thyroid substance was 1.8 cm. less than in the original films.

Electrocardiographic abnormalities were recorded in all eight cases (table I). The P-waves were iso-electric or of subnormal amplitude in all. The QRS complexes were of low voltage in four, while in a fifth, although the voltage was within normal limits at the beginning of treatment, thyroid therapy resulted in an increase in amplitude. In all eight cases, the T-waves were of low amplitude, iso-electric, or inverted in all three conventional leads. T-IVF was inverted in three of the five cases in which precordial leads were recorded. Auriculoventricular conduc-

TABLE I
THE HEART IN MYXEDEMA

Case No.	Age Years	Sex	Before treatment	Basal Metabolic Rate Per Cent	Plasma Cholesterol mgm/100cc.	Pulse Rate	Electrocardiogram	Internal Diameter of Thorax cm.	Transverse Diameter of Heart cm.	Blood Pressure	
										Systolic mm. Hg.	Diastolic mm. Hg.
1	56	F	Before treatment	-36	263	58	P-waves iso-electric. Low voltage of QRS. T-I and II inverted. Low T-III. T-IV F inverted.	30.0	16.5	150	98
			4 weeks after beginning treatment	-4	128	62	P-I iso-electric. P-II and III normal. QRS complexes of greater amplitude. T-I, II, and IV F upright. Low T-III.	30.0	14.0	132	81
			6 months after beginning treatment	-5	183	60	P-I, II, and III upright. QRS complexes of greater amplitude. T-I, II, III, and IV F of greater amplitude.	30.4	16.5	128	86
2	60	F	Before treatment	-24		72	Low P-waves. Low voltage of QRS. T-I, II, III, and IV F inverted. Left axis deviation.	28.0	15.2	160	98
			One month after beginning treatment	± 0		82	P-waves and QRS complexes of greater voltage. T-I, II, and IV F upright. T-III inverted. Left axis deviation.	29.2	15.2	130	98
3	68	F	Before treatment	-38	333	78	Low P-waves. P-R = 0.24 second. QRS complexes of normal amplitude. T-I, II, and IV F inverted. T-III diphasic. Left axis deviation.			110	90
4	57	F	Before treatment	-28	348	93	Low P-waves. QRS complexes of normal amplitude. Low T-I. T-II, III inverted. T-IV F normal.	29.2	15.2	130	98
5	45	M	Before treatment	-31	277	48	Low P-waves. QRS complexes of normal amplitude. Low T-I. T-II iso-electric. T-III inverted. T-IV F normal.			110	90
6	37	M	Before treatment	-41	196	104	Low P-waves. QRS complexes of normal amplitude. Low T-I. T-II and III inverted.	31.8	14.5	138	100
			4 months after beginning treatment	-17	136	104	Normal P-waves. QRS complexes of greater voltage. T-I normal. T-II upright but low. T-III inverted.	31.8	12.7		
7	43	F	Before treatment	-38	333	66	Low P-waves. QRS complexes of low voltage. Low T-I. Flat T-II. Inverted T-III.			125	70
			4 months after beginning treatment	\pm	200	78	P-waves and QRS complexes of normal amplitude. T-I and II normal. T-III inverted.				
8	38	M	Before treatment	-40	300	65	P-waves and QRS complexes of low voltage. T-I inverted. Low T-I and II.			108	86

MYXEDEMA HEART

tion was prolonged in one case but it is not certain that this change was due to myxedema, since no subsequent tracings were made after the patient had been receiving thyroid substance. In four cases additional electrocardiograms were made after the patient had been receiving thyroid substance for one to five months, and in all, the original abnormalities were found to have been corrected.

None of the eight patients presented signs of congestive heart failure, but five had experienced dyspnea on slight or moderate exertion.

The following case report illustrates the most important features of myxedema heart not accompanied by congestive heart failure.

CASE REPORT

Case 1: A white married woman, 56 years of age, had experienced an attack of influenza two years before and shortly afterward noted swelling of the soft tissues of the head and face and puffiness under the eyes. The swelling varied in degree from day to day and was usually worse in the mornings. After one year, swelling, burning pain, and paresthesia had developed in the hands, and to a lesser degree in the feet. The sensory disturbances were aggravated by exposure to cold. The hair had become drier and the skin dry and rough. The weight had increased, but the actual amount gained was not known. Weakness, fatiguability, and apathy were prominent symptoms, and there was mild dyspnea on limited exertion.

Physical examination: The patient was 61½ inches tall and weighed 174 pounds. The face was full and the expression dull. There was distinct puffiness about the eyes. The hair was thin and dry and the skin dry and of a lemon-yellow tint. The tongue was full and thick. There was no palpable thyroid tissue. The lungs were clear on percussion and auscultation. The area of relative cardiac dullness extended 11 cm. to the left of the midsternal line in the fifth intercostal space. The heart rhythm was regular and the rate 52 beats per minute. A faint systolic murmur was present over the aortic area. All heart sounds were of average quality. The peripheral arteries were not appreciably thickened, and the arterial pressure was 150 mm. systolic and 98 mm. diastolic. The liver was not enlarged or tender. The hands, forearms, feet, and lower legs appeared swollen but there was no pitting edema.

Examination of the urine gave normal findings. The red blood cell count was 4,130,000 per cu. mm., and the hemoglobin content 71 per cent. The white blood cell count was 6,150 per cu. mm. The plasma cholesterol content was 263 mgm. per 100 cc., and the Wassermann and Kahn reactions of the blood were negative.

The basal metabolic rate was —36 per cent. A teleroentgenogram showed the transverse diameter of the heart shadow to be 16.5 cm. and

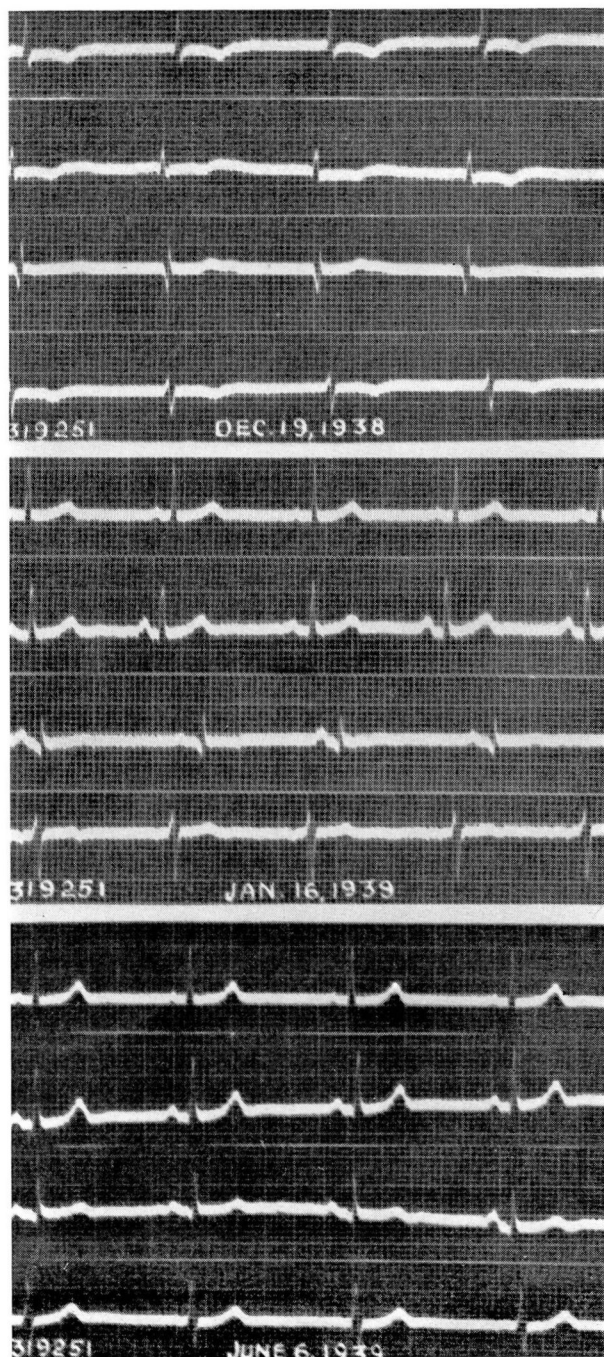


FIGURE 1: Electrocardiograms of patient discussed in Case 1.

MYXEDEMA HEART

the internal diameter of the thorax 30 cm. An electrocardiogram (figure 1) showed sinus rhythm with a rate of 58 per minute. The QRS complexes were of low voltage and the P-waves were iso-electric in all leads. The T-waves were inverted in leads I, II, and IV F and of low amplitude in lead III.

Armour's desiccated thyroid was prescribed in doses of three grains daily for two weeks, and the dosage was then reduced to two grains daily. Twenty-seven days after beginning treatment, the patient's weight had decreased to 151 pounds and there was striking improvement in her general appearance. The basal metabolic rate was -4 per cent and the plasma cholesterol content 128 mgm. per 100 cc. The electrocardiogram (figure 1) was normal except for an iso-electric P-I and a flat T-III. The heart rate was 60 beats per minute. The patient was advised to continue to take two grains of desiccated thyroid daily for one more month, and then to reduce the dose to one grain daily.

Six months after the institution of therapy, the patient's general appearance was quite normal and she complained only of occasional tingling in the hands. The weight was 129 pounds, the pulse rate 60 beats per minute, and the blood pressure 132 mm. systolic and 84 mm. diastolic. The basal metabolic rate was -5 per cent and the plasma cholesterol content 183 mgm. per 100 cc. A teleroentgenogram showed the transverse diameter of the heart shadow to be 2.5 cm. smaller than at the time of the first examination. The electrocardiogram was within normal limits except for a low P-I (figure 1). The red blood cell count was 4,470,000 per cu. mm. and the hemoglobin content 84 per cent. The patient was advised to continue to take one grain of desiccated thyroid daily.

DISCUSSION

Knowledge of the pathology of myxedema heart is based on the examination of only a small amount of material². The significant changes consist of interstitial edema and more or less myocardial fibrosis. Coronary artery sclerosis is often present. The increase in the size of the cardiac shadow in teleroentgenograms has been variously explained in the past as the result principally of hypertrophy of the heart, dilatation of the heart, or pericardial effusion. The prompt and often considerable diminution in the size of the shadow after the institution of treatment with thyroid substance is strong evidence against the presence of any great degree of true hypertrophy. Pericardial effusion is present at times, but in most cases of myxedema neither the clinical findings nor the roentgenographic appearance are consistent with the presence of significant amounts of fluid in the pericardium³. There is general agreement at present that the cardiac enlargement in myxedema is due chiefly to dilatation, but interstitial edema may be a minor contributory factor.

Changes in the electrocardiogram occur even more commonly in myxedema than does enlargement of the heart. Although many types of abnormalities have been recorded, the only one that is characteristic consists of iso-electric or inverted P- and T-waves in all leads. The QRS complexes, however, are often of subnormal amplitude.

Neither the electrocardiographic abnormalities nor the cardiac enlargement of myxedema are corrected by the use of digitalis. Thyroid substance in adequate amounts, on the other hand, brings about a complete return of all changes to normal. Overdosage must be carefully avoided, and whenever the heart is considerably enlarged or there is a history of angina pectoris, only small amounts of thyroid should be given. The effect of treatment on the basal metabolic rate, heart size, and electrocardiogram should be checked periodically, and as soon as the maximum degree of improvement has been attained, the daily dose of thyroid should be reduced to the lowest level that will maintain this state.

SUMMARY

The roentgenographic and electrocardiographic findings in eight cases of myxedema heart have been summarized, and one case has been reported in detail.

REFERENCES

1. Zondek, H.: *Das Myxödemherz*, München med. Wchnschr., 65:1180-1182, 1918.
2. Higgins, W. H.: The heart in myxedema: correlation of physical and postmortem findings, *Am. J. Med. Sc.*, 191:80-88, (January) 1936.
3. Lerman, J., Clark, R. J. and Means, J. H.: Heart in myxedema; electrocardiographic and roentgen-ray measurements before and after therapy, *Ann. Int. Med.*, 6:1251-1271, (April) 1933.