

KIRK M. CHAN-TACK, MD

Department of Medicine, University of
Missouri-Columbia, Columbia, Mo

SHANNON STANDRIDGE

Department of Pathology, University of
Missouri-Columbia, Columbia, Mo

EDWARD ADELSTEIN, MD

Department of Pathology, University of
Missouri-Columbia, Columbia, Mo

A 62-year-old man with hypotension and an abnormal chest radiograph

A 62-YEAR-OLD MAN was dancing at a wedding when he experienced the sudden onset of “fullness and discomfort” in the middle of his chest, accompanied by dizziness, nausea, diaphoresis, and presyncope. He was taken to a local emergency room and was found to be hypotensive (blood pressure 80/42 mm Hg). Vigorous volume resuscitation with normal saline was started. The patient was then transferred by helicopter to our hospital for further evaluation and management.

The patient’s medical history was normal, except for pneumonia “many years ago.” He was not taking any medications, and he reported no allergies. The family history was noncontributory. He had no history of tobacco, alcohol, or illicit drug use.

Review of systems revealed only that the patient had a cough with clear sputum that had persisted for 3 days. He denied shortness of breath, palpitations, syncope, and hemoptysis.

Physical examination

The patient was fully alert and was seated comfortably in the hospital stretcher. His temperature was 98.1°F (36.7°C), pulse 90 beats/minute, respirations 22/minute, blood pressure 160/90 mm Hg, oxygen saturation 97% while receiving oxygen at 2 L/minute, weight 90 kg. No jugular venous distention was noted. His lungs were clear. Heart sounds were normal without any murmurs, rubs, or gallops. The abdominal examination was normal, with no organomegaly, masses, or abdominal bruits noted. Peripheral pulses were intact, brisk, and symmetric. The skin was warm and dry. The remainder of the physical examination was unremarkable.

Laboratory data

Laboratory blood test results were normal, except for the following:

- Creatinine 1.6 mg/dL (normal 0.6–1.2)
- Creatine kinase 304 U/L (normal 20–130)
- Creatine kinase-MB isoenzyme fraction 1% (normal < 2)
- Cardiac troponin I level 0.6 ng/mL (normal 0–0.3).

Imaging studies

Electrocardiography (ECG) showed normal sinus rhythm and left atrial enlargement. No acute ST-T wave changes or S₁Q₃T₃ pattern was noted.

Portable chest radiography (FIGURE 1) revealed mild superior mediastinal widening,

The patient’s radiograph on presentation

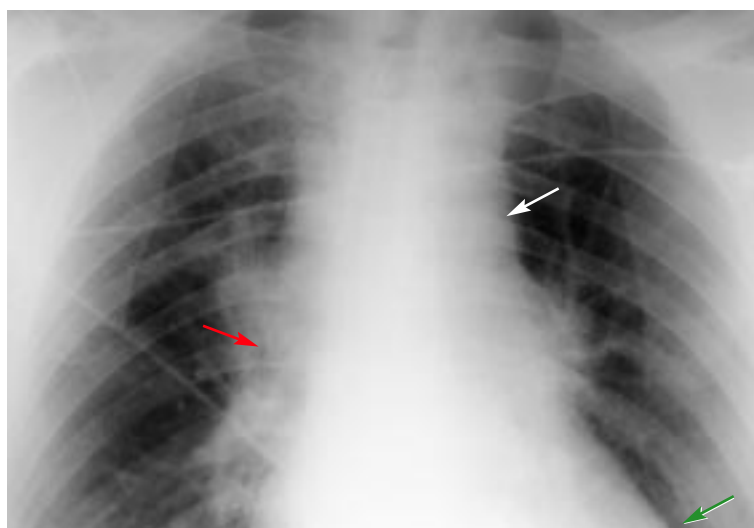


FIGURE 1. Portable radiography reveals mild superior mediastinal widening (white arrow), prominent right hilum (red arrow), and bilateral lower lobe discoid atelectasis (green arrow).



prominent right hilum, and bilateral lower lobe discoid atelectasis. The heart size was described as either in the “top normal” size range or mildly enlarged.

■ DIFFERENTIAL DIAGNOSIS

1 Which is the most likely diagnosis at this point?

- ☐ Acute coronary syndrome
- ☐ Pulmonary embolism
- ☐ Aortic dissection
- ☐ Cardiac tamponade

Hypotension, even if transient, often portends significant disease. Conditions associated with hypotension include sepsis, cardiogenic shock due to acute coronary syndrome, aortic dissection, drug reaction, anaphylaxis, pulmonary embolism, cardiac tamponade, tension pneumothorax, hypovolemia, hemorrhage, hypoxemia, and hypoadrenalism.

Acute coronary syndrome

The physical examination in patients with acute coronary syndrome is often completely normal. Chest radiographs are usually normal, unless the patient is in congestive heart failure.

The ECG results and initial cardiac enzyme levels in this patient were not consistent with acute myocardial infarction; however, it is too soon to rule out unstable angina or non-Q-wave myocardial infarction as the underlying process. Furthermore, our patient has several key risk factors for acute coronary syndrome: he is male and over age 50, and he has hypertension. He does not have other risk factors, such as diabetes, smoking, or a family history of premature cardiac disease, and his lipid status is unknown. Nevertheless, acute coronary syndrome was suspected at this time.

Pulmonary embolism

Pulmonary embolism can present with presyncope and transient hypotension. Other symptoms include dyspnea, chest pain (pleuritic or nonpleuritic), fever, diaphoresis, cough, or hemoptysis. Physical examination may show tachypnea, tachycardia, hypoxia, jugular venous distention, bilateral rales, increased

pulmonic component of S₂, tricuspid insufficiency murmur, right ventricular heave, or right-sided S₃. ECG typically shows sinus tachycardia, but other findings (acute bundle branch block, acute axis change, new-onset atrial fibrillation, S₁Q₃T₃, T-wave inversion in V₁ to V₄, right ventricular strain) can also be seen. Chest radiographs may be normal; suggestive findings include an elevated diaphragm, pleural effusion, pulmonary artery dilatation, infiltrates, and wedge-shaped consolidation (“Hampton’s hump”). Based on what we have seen to this point, this diagnosis is unlikely.

Aortic dissection

Acute transient hypotension in an elderly man with apparent baseline hypertension, coupled with the finding of a widened mediastinum on the chest radiograph, should raise the suspicion of aortic dissection. A widened mediastinum on an anterior-posterior film is less specific for aortic dissection than on a posterior-anterior film; the view obtained in this patient was anterior-posterior, so the radiograph obtained in this patient is less helpful in the diagnosis.

Although long-standing uncontrolled hypertension is one of the principal risk factors for aortic dissection, the blood pressure in patients who present with an acute aortic dissection may be elevated, normal, or low. Patients with aortic dissection may have an aortic insufficiency murmur, diminished or absent pulses, congestive heart failure, or acute neurologic deficits from a stroke. None of these was present on the initial examination of this patient.

Data from the International Registry of Acute Aortic Dissection (IRAD) show that the ECG is normal or nonspecific in about 80% of patients with acute aortic dissection.¹ This registry also notes that the chest radiograph may be normal in 11% of cases or may lack the classic finding of a widened mediastinum or an abnormal aortic contour in 17% of cases.

Cardiac tamponade

Cardiac tamponade most commonly results from neoplastic disease, idiopathic pericarditis, or uremia—none of which seems likely in

Even transient hypotension often portends significant disease

A turn for the worse

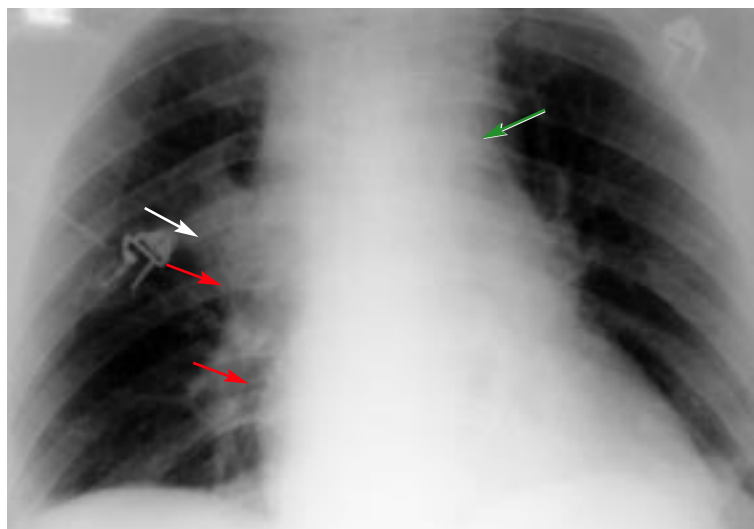


FIGURE 2. A repeat chest radiograph shows a right hilar and right paramediastinal prominence (white arrow), possible right hilar mass or infiltrate (red arrow), and peritracheal lymphadenopathy (green arrow).

Acute aortic dissection is always a medical emergency

this patient, given the available information. The cardinal pathophysiologic process of cardiac tamponade involves elevated intracardiac pressures, limited ventricular filling, and reduced cardiac output. Pulsus paradoxus is common. A prominent X descent is usually seen in the jugular veins. ECG can show low voltage or electrical alternans. Chest radiography can show an enlarged cardiac silhouette but may be normal in acute tamponade.

■ CASE CONTINUED

Worsening of clinical status, repeat radiography performed

As acute coronary syndrome was suspected, the patient was admitted to the cardiac intensive care unit for telemetry monitoring. Treatment with aspirin, a beta-blocker, and enoxaparin was begun, and serial cardiac enzyme levels were checked.

Six hours later, the patient developed pleuritic chest pain, difficulty breathing, and hemoptysis. His temperature was 98.6°F (37°C), blood pressure 180/100 mm Hg, pulse 90 beats per minute, respirations 26, oxygen saturation 95% while receiving oxygen at 4 L/minute. The physical examination was otherwise unchanged, and the first two sets of

cardiac enzyme studies were negative. A repeat chest radiograph (**FIGURE 2**) showed a right hilar and right paramediastinal prominence, a possible right hilar mass or infiltrate, and peritracheal lymphadenopathy.

Diagnosis reconsidered

These findings made the initial diagnosis of acute coronary syndrome unlikely, and pulmonary embolism was considered. However, duplex ultrasonography of the legs revealed no deep venous thrombosis, and ventilation-perfusion scanning detected no pulmonary embolus, making pulmonary embolism unlikely as the underlying diagnosis. Nevertheless, because of the patient's symptoms and for confirmation, computed tomography (CT) of the chest was ordered, and pulmonologists were consulted.

During the night, the hypertension persisted (systolic blood pressure 180–200 mm Hg) despite increasing doses of an oral beta-blocker.

■ AORTIC DISSECTION REVEALED

Chest CT performed on the morning of the second hospital day revealed a large aneurysmal ascending aorta with a luminal filling defect due to type 1 aortic dissection, an enlarged heart, and a large pericardial effusion (**FIGURE 3**). No evidence of dissection along the transverse or descending aorta was found.

Classification of aortic dissection

Acute aortic dissection is a medical emergency.^{1–9} In many cases, it begins as a tear in the aortic intima. In some cases, the dissection begins as bleeding into the media. Blood accumulates in the aortic media and separates the intima from the adventitia, creating a false lumen. The dissection usually propagates distally from the initial site, although proximal extension into the coronary arteries can occur.

Dissections can originate anywhere along the aorta: 60% arise in the ascending aorta, 30% arise in the descending aorta, and 10% arise in the aortic arch.

Two main classification systems exist.^{2–9} The DeBakey system uses the point of origin and extension of the dissection. The



Daily/Stanford system distinguishes between dissections that involve the ascending aorta (type A) and all others (type B).

Regardless of which system is used, if the time between symptom onset and presentation is within 14 days, the aortic dissection is considered acute. It is chronic if the time between symptom onset and presentation is greater than 14 days.

Predisposing factors

Factors that predispose to aortic dissection are:

- Uncontrolled hypertension (seen in 70% to 90% of cases)
- Age over 50 (peak incidence in the 50s and 60s)
- Male sex (three times more common in men than in women)
- Connective tissue disease (Marfan, Ehlers-Danlos, Turner syndromes)
- Coarctation of the aorta
- Congenital bicuspid or unicommissural aortic valve
- Atherosclerosis
- Inflammatory aortitis (syphilitic aortitis, giant cell arteritis, Takayasu arteritis)
- Pregnancy
- Cocaine use.^{1-6,9}

The most important risk factors are long-standing, uncontrolled hypertension, advanced age (peak incidence is in the 6th and 7th decades of life), aortic wall disease (wall integrity is affected by a variety of conditions), and male sex—three of which were present in this patient.

Red flag symptoms

A high index of suspicion is the most important factor in the diagnosis of aortic dissection. In addition, certain symptoms should heighten clinical suspicion:

Pain. According to the IRAD data,¹ pain occurs in 85% to 95% of patients with aortic dissection and may have an abrupt onset in 85% of these cases. Common locations for pain include the chest (70% to 79% of patients), anterior chest (60% to 70%), posterior chest (33% to 35%), back (47% to 53%), and abdomen (22% to 30%). In the IRAD, 90% of patients described the pain as “severe or worst ever.” The pain was sharp (62% to 68%), tearing or ripping (49% to 52%), radi-

Day 2: Acute aortic dissection

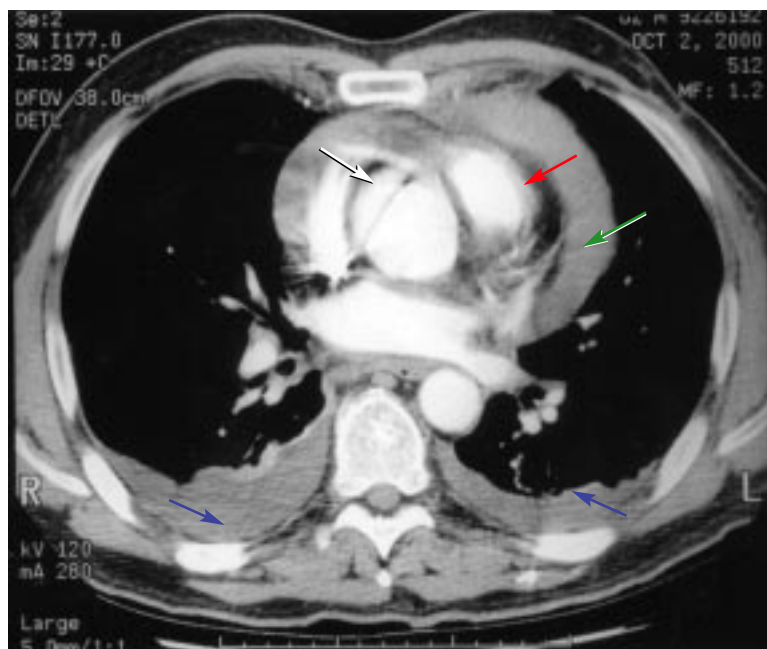


FIGURE 3. Chest CT demonstrates a large aneurysmal ascending aorta with luminal filling defect characteristic of a type 1 aortic dissection (white arrow). Cardiomegaly (red arrow) and a large pericardial effusion (green arrow) are also noted. There was no evidence of dissection along the transverse or descending aorta. There was bilateral atelectasis (right more than left) (blue arrows) but no mediastinal or hilar lymphadenopathy.

ating (27% to 30%), or migrating (15% to 19%).

Neurologic deficit is the presenting symptom in 20% of patients with aortic dissection, with syncope a presenting symptom in 4% to 13%.

Dyspnea is present in 3% to 9%.

In the IRAD, key presenting signs included an aortic insufficiency murmur (44% of patients), diminished or absent pulses (19%), congestive heart failure (9%), and stroke (6%); also, the systolic blood pressure was above 150 mm Hg at presentation in 36% of patients, 100 to 149 mm Hg in 39%, 80 to 100 in 12%, and below 80 in 13%.

Laboratory testing is of limited value in aortic dissection

Laboratory studies can be helpful but are neither sensitive nor specific. Acute renal failure with elevated blood urea nitrogen and creati-

nine levels occurs in 15% to 20% of patients with aortic dissection. Mild leukocytosis (white blood cell count 12 to $15 \times 10^9/L$) is seen in 26% of patients. Cardiac enzyme levels are normal in 85% to 92% of patients with aortic dissection.^{1,3,4}

IMAGING STUDIES FOR AORTIC DISSECTION

2 Which of the following studies can be used to diagnose aortic dissection?

- ☐ ECG
- ☐ Chest radiography
- ☐ Chest CT
- ☐ Magnetic resonance imaging (MRI)
- ☐ Transthoracic echocardiography
- ☐ Transesophageal echocardiography

As noted above, ECG and chest radiography are not usually helpful in the evaluation of aortic dissection, and more sophisticated imaging studies are usually needed to confirm the diagnosis. All the other studies listed can be used.

Chest CT with intravenous contrast has high sensitivity (90% to 95%) and high specificity (90% to 95%) and can rapidly provide valuable diagnostic information.²⁻⁴ It may not always detect dissection in the aortic branches, however.

Magnetic resonance imaging (MRI) of the chest has high sensitivity (95% to 100%) and high specificity (95% to 100%) but is time-consuming and expensive.²⁻⁴

Transthoracic echocardiography is fast, noninvasive, and easily done at the bedside. It is very sensitive for identifying ascending aortic dissection (96%), aortic insufficiency, and pericardial effusion, but has poor sensitivity for distal dissection.²⁻⁴

Transesophageal echocardiography is also fast, has high sensitivity (95% to 99%) and high specificity (85% to 90%), and detects coronary artery involvement, aortic insufficiency, and pericardial effusion.²⁻⁴ However, it is invasive and requires esophageal intubation.

Aortography. Despite the availability of other effective techniques, aortography remains the gold standard, with high sensitiv-

ity (90% to 95%) and high specificity (95% to 99%).²⁻⁴ It is invasive and requires intra-arterial contrast. It establishes the site of the tear and the extent of dissection, identifies whether communication exists between the true and false lumens, quantifies the degree of aortic insufficiency, and identifies whether the main arterial branches are involved.

MANAGEMENT

3 Which should be the next step in managing this patient?

- ☐ Continued drug therapy and telemetry monitoring
- ☐ Aggressive blood pressure control
- ☐ Discontinuation of aspirin and enoxaparin
- ☐ Surgery
- ☐ Aggressive blood pressure control and immediate surgery

In acute aortic dissection, aggressive blood pressure control^{1,2,5,8,9} and emergency surgery are essential, and a cardiothoracic surgery consult should be obtained immediately. Systolic blood pressure should be lowered to and maintained between 100 and 120 mm Hg or at the lowest level to allow adequate renal, cardiac, and cerebral perfusion. Beta-blockers (esmolol, metoprolol, labetalol, or propranolol given intravenously) are the treatment of choice: they lower blood pressure and lower the rate of pressure change (dP/dT) within the aorta. Calcium channel blockers may be used if patients cannot tolerate beta-blockers. Intravenous nitroprusside is a potent vasodilator and may be used in conjunction with beta-blockers, but always as a second-line agent.

Immediate surgery is warranted for dissections of the ascending aorta (DeBakey type 1 and 2, Daily/Stanford type A),^{1,2,5,8,9} which our patient had. Surgery involves replacing the ascending aorta (and aortic arch if needed), reconstructing the aortic root to restore aortic valve competence, and directing blood flow back into the true lumen.

Distal dissection (DeBakey type 3, Daily/Stanford type B) is treated medically with beta-blockers for blood pressure control and aortic wall shear stress reduction.^{1,2,5,8,9}

Aggressive blood pressure control and immediate surgery are essential



Day 3: Disaster

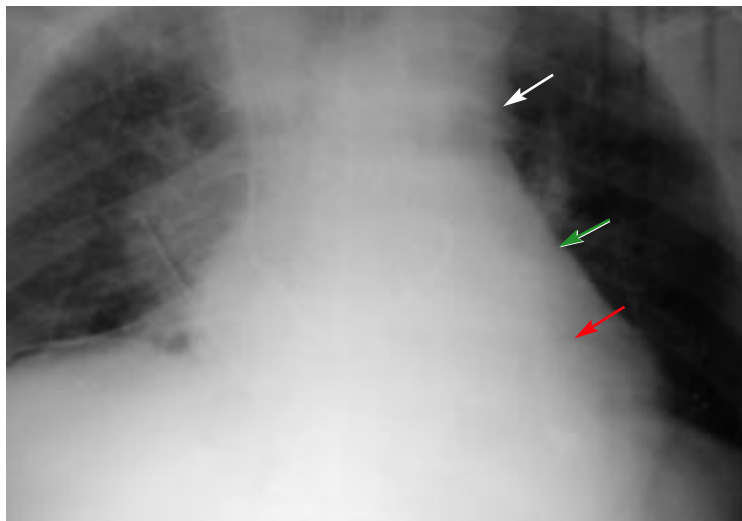


FIGURE 4. Chest radiography reveals significant superior mediastinal widening (white arrow), cardiomegaly (red arrow), and pericardial effusion (green arrow).

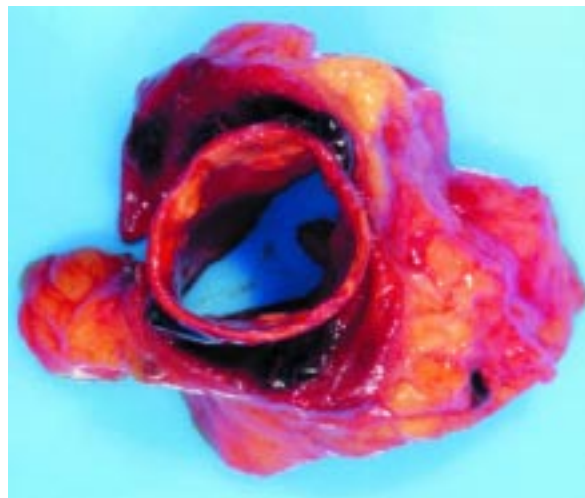


FIGURE 5. Gross specimen of the aorta shows separation of the intimal and medial layers.

However, surgery may be needed in refractory type B dissection or if complications arise (such as dissection into vital branch vessels).

■ CASE CONTINUED

Intravenous beta-blocker therapy was started and titrated for improved blood pressure control. A cardiothoracic surgeon was consulted, and the patient was taken directly to the operating room. His clinical status deteriorated, and hypotension developed in the operating room. The pericardium was opened and was found to contain 200 mL of blood. The dissection and rupture of the ascending aorta were extensive. The ruptured aorta was replaced with graft. There was massive blood loss, and multiple units of packed red blood cells and platelets were transfused intraoperatively and postoperatively.

The postoperative course was marked by refractory hemorrhagic shock, thrombocytopenia, coagulopathy, and increasing oxygenation requirements. On the morning of the third hospital day, the patient suddenly developed bradycardia. Portable chest radiography (**FIGURE 4**) revealed significant superior mediastinal widening, cardiomegaly, and an enlarged cardiac silhouette. The mediastinum was emergently re-explored at the bedside and

fresh blood was found around the heart. Open heart massage was performed, and a “code blue” was initiated. Resuscitation attempts were unsuccessful, and the patient died.

Pathologic review showed separation of the aortic intima and media, with elastin disorganization, mucoid pooling, and loss of smooth muscle cells within the plane of dissection in the aortic media (**FIGURE 5**).

■ PROGNOSIS OF AORTIC DISSECTION


Despite advances in the diagnosis and management of acute aortic dissection, morbidity and mortality remain high. Morbidity is primarily due to renal, cerebral, myocardial, mesenteric, or hepatic ischemia. Mortality rates depend on the type of dissection and have gradually improved, but overall in-hospital mortality rates remain in the range of 27% to 30%.¹⁻⁴ The most common causes of death from type A aortic dissection are aortic rupture (45%) and visceral organ ischemia (15%). Patients with a type B dissection most commonly die of aortic rupture (40%) or visceral organ ischemia (15%).

No patient should ever be considered cured of this disease. Overall survival rates for patients who leave the hospital are 50% to 80% at 5 years (higher rates in more recent

**No patient
should be
considered
cured of aortic
dissection**



series), and 40% at 10 years. Survival rates are not influenced by the type of dissection.

Long-term medical therapy with beta-blockers is essential for blood pressure control and reducing aortic wall shear stress. Close clinical monitoring and radiologic surveillance are important features of long-term care. Authors recommend chest CT or MRI every 3 to 12 months depending upon the aortic size and the rate of increase of the aorta diameter. Aggressive treatment of any concomitant cardiac, cerebrovascular, or peripheral vascular disease is also needed. 

■ REFERENCES

1. Hagan PG, Nienaber CA, Isselbacher EM, et al. The International Registry of Acute Aortic Dissection (IRAD): new insights into an old disease. *JAMA* 2000; 283:897–903.
2. Pretre R, Von Segesser LK. Aortic dissection. *Lancet* 1997; 349:1461–1464.
3. von Kodolitsch Y, Schwartz AG, Nienaber CA. Clinical prediction of acute aortic dissection. *Arch Intern Med* 2000; 160:2977–2982.
4. Spittell PC, Spittell JA Jr, Joyce JW, et al. Clinical features and differential diagnosis of aortic dissection: experience with 236 cases (1980–1990). *Mayo Clin Proc* 1993; 68:642–651.
5. DeSanctis RW, Doroghazi RM, Austen WG, Buckley MJ. Aortic dissection. *N Engl J Med* 1987; 317:1060–1067.
6. Larson EW, Edwards WD. Risk factors for aortic dissection: a necropsy study of 61 cases. *Am J Cardiol* 1984; 53:849–855.
7. O’Gara PT, DeSanctis RW. Acute aortic dissection and its variants. Toward a common diagnostic and therapeutic approach. *Circulation* 1995; 92:1376–1378.
8. Asfoura JY, Vidt DG. Acute aortic dissection. *Chest* 1991; 99:724–729.
9. Crawford ES. The diagnosis and management of aortic dissection. *JAMA* 1990; 264:2537–2541.

ADDRESS: Kirk M. Chan-Tack, MD, Department of Medicine, Northwestern University Medical School, Evanston Hospital, 2650 Ridge Avenue, Evanston, IL 60201; e-mail kirkchantack@hotmail.com.