

**DAVID P. VOGT, MD**

General and Liver Transplant Surgery, Transplant Center, and Department of General Surgery, The Cleveland Clinic

Gallbladder disease: An update on diagnosis and treatment

ABSTRACT

This paper reviews the clinical presentation of gallstone disease, acalculous cholecystitis, biliary dyskinesia, and gallbladder cancer, as well as how to make best use of current diagnostic and treatment methods, particularly ultrasonography, cholescintigraphy, laparoscopic cholecystectomy, and endoscopic retrograde cholangiopancreatography.

KEY POINTS

Although 10% to 15% of people in the United States develop gallstones, fewer than half of those with gallstones have symptoms, and fewer than 10% develop potentially life-threatening complications.

Ultrasonography and cholescintigraphy are the most helpful imaging studies for the diagnosis of gallstone disease. Cholescintigraphy is 95% accurate in the outpatient diagnosis of acute cholecystitis.

Laparoscopic cholecystectomy has replaced open cholecystectomy as the gold standard for treating symptomatic gallbladder disease.

Endoscopic retrograde cholangiopancreatography with sphincterotomy is the standard treatment of patients with common bile duct stones (choledocholithiasis).

Gallbladder cancer is relatively uncommon but often has a dismal prognosis.

FOR THE MANY PATIENTS who present with acute or persistent symptoms of gallbladder disease, current diagnostic techniques and treatments offer results equal to or better than those of earlier methods, are less invasive, and allow patients to recover faster.

This paper reviews the evaluation and treatment of gallstones, common bile duct stones, biliary dyskinesia, gallbladder polyps, and gallbladder cancer.

CHOLELITHIASIS (GALLSTONES)

About 20 million people in the United States (10% to 15% of the adult population) develop gallstones, and the incidence increases with age.^{1,2} Fewer than 50% of those with gallstones actually have symptoms, and fewer than 10% develop potentially life-threatening complications.¹

Clinical presentations of cholelithiasis

Biliary colic. From 60% to 70% of people with symptomatic cholelithiasis experience episodes of biliary colic,¹ typically described as postprandial epigastric or right upper quadrant pain, sometimes radiating to the back or up to the right shoulder. The pain may last from several minutes to several hours. Intense pain is often accompanied by nausea and vomiting.

Occasionally, a patient may insist that the pain is in the left upper quadrant. Many patients also complain of belching, bloating, dyspepsia, and flatulence, but unless these symptoms are associated with biliary colic, they are not likely to resolve after cholecystectomy.

The physical examination may reveal mild epigastric or right upper quadrant tenderness, but most patients do not have significant physical findings.

TABLE 1

The Ranson criteria for prognosis in acute pancreatitis

Signs on admission

Age > 55 years
 Serum glucose level > 200 mg/dL
 Serum lactate dehydrogenase level > 350 U/L
 Aspartate aminotransferase level > 250 U/L
 White blood cell count > $16,000 \times 10^9/L$

Signs 48 hours after admission

Hematocrit increase > 10 percentage points
 Blood urea nitrogen increase > 5 mg/dL
 Serum calcium < 8 mg/dL
 Partial pressure of arterial oxygen < 60 mm Hg
 Base deficit > 4 mEq/L
 Estimated fluid sequestration > 6 L

Mortality increases with the number of signs present; if fewer than three signs are present, the mortality rate is < 5%; if three or four are present, it is 15% to 20%

ADAPTED FROM RANSON JHC, RIFKIND KM, ROSES DF, FINK SD, ENG K, SPENCER FC. PROGNOSTIC SIGNS AND THE ROLE OF OPERATIVE MANAGEMENT IN ACUTE PANCREATITIS. SURG GYNECOL OBSTET 1974; 139:69–81.

Biliary colic is intermittent; acute cholecystitis is persistent

The pain of biliary colic is from contraction of the gallbladder, which cannot empty because the cystic duct is obstructed by a stone. The gallbladder is stimulated to contract primarily by cholecystokinin, which is released from the small bowel mucosa. The pain resolves after the gallbladder stops contracting or when the cystic duct becomes patent again.

Acute cholecystitis is the initial presentation of symptomatic gallstones in 15% to 20% of patients.³

Patients with acute cholecystitis experience severe pain that persists for several hours, until they finally seek help at a local emergency room.

Whereas in biliary colic the cystic duct obstruction is transient, in acute cholecystitis it is persistent. Persistent cystic duct obstruction, in combination with chemical irritants in the bile, results in inflammation and edema of the gallbladder wall. Nausea and vomiting are common.

Physical examination usually reveals marked tenderness in the right upper quadrant, often associated with a definite mass or fullness. Palpation of the right upper quadrant

during inspiration often causes such severe discomfort that the patient stops inspiring (a positive Murphy sign). Local peritoneal signs and fever are common.

Gallstone pancreatitis. In 10% to 15% of patients with symptomatic gallstones, the initial presentation is a complication such as gallstone pancreatitis or a common bile duct stone.³

Ninety percent of patients with gallstone pancreatitis have a “mild” episode, defined as having no more than three of the 11 Ranson criteria (TABLE 1).⁴ The symptoms are similar to those of a severe episode of biliary colic. The epigastric or right upper quadrant pain lasts for several hours and may be associated with nausea and vomiting. Physical examination usually reveals epigastric fullness and tenderness, but no peritoneal signs. For most patients, symptoms improve significantly over 3 to 4 days with supportive therapy alone.

Patients with **common bile duct stones** often have jaundice and fever in addition to pain.

Laboratory tests for cholelithiasis

Laboratory tests should include a complete blood count, liver function tests, and serum amylase and lipase levels.

In chronic, episodic biliary colic, most patients have normal laboratory values, particularly if they have no symptoms at the time of their office visit. However, patients with acute pain at the time of evaluation may have elevated levels of liver enzymes (aspartate aminotransferase, alanine aminotransferase, alkaline phosphatase) and bilirubin, particularly if bile duct stones are present.

In gallstone pancreatitis, patients have elevated levels of both serum amylase and lipase, as well as abnormal liver function tests.

In acute cholecystitis, leukocytosis should be expected, and up to 15% of patients may have mild elevations of aspartate aminotransferase, alanine aminotransferase, alkaline phosphatase, and bilirubin if the stone is not in the common bile duct.

Imaging studies for cholelithiasis

Ultrasonography and cholescintigraphy are the imaging studies most helpful and most often used in the diagnosis of gallstone disease.



■ Ultrasonography aids the diagnosis of gallstones

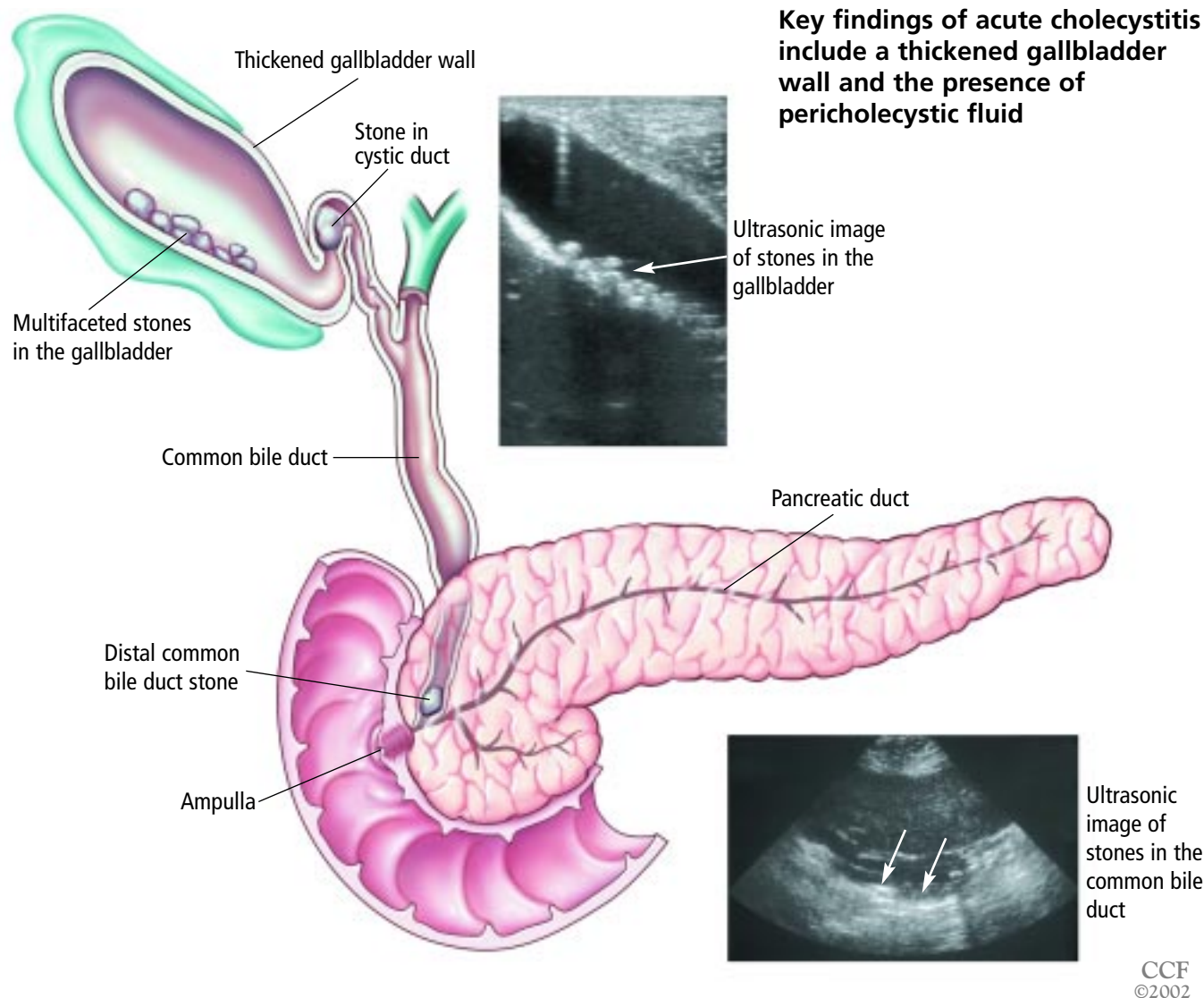


FIGURE 1

Ultrasonography is safe, fast, and relatively inexpensive and involves no radiation exposure. It is the study of choice for patients with suspected biliary colic. Positive findings include stones, thickening of the gallbladder wall, pericholecystic fluid, and a positive Murphy sign on contact with the ultrasonographic probe⁵ (FIGURE 1). The latter three findings are particularly indicative of acute cholecystitis.

A drawback to ultrasonography is that it is only as accurate as the person who performs and interprets it.

Cholescintigraphy is accurate in diagnosing acute cholecystitis in ambulatory patients more than 95% of the time.^{6,7} When combined with cholecystokinin injection, it is helpful in assessing patients with possible biliary dyskinesia.⁸

Cholescintigraphy provides the functional information that the cystic duct is obstructed, which is a necessary component in the pathogenesis of calculous cholecystitis. However, it has a false-positive rate of 30% to 40% in patients who have been hospitalized for

other medical problems for several weeks, particularly if they have been on parenteral nutrition. In these patients, ultrasonography is more accurate.⁵

Computed tomography is not as accurate as ultrasonography in detecting gallstones and is therefore not a good screening study in evaluating patients with probable chronic biliary disease.⁵ In acute cases, however, it can show thickening of the gallbladder wall or pericholecystic fluid associated with acute cholecystitis.⁵

ERCP when choledocholithiasis is suspected

Patients suspected of having choledocholithiasis (a stone in the common bile duct) may benefit from undergoing endoscopic retrograde cholangiopancreatography (ERCP), sphincterotomy, and stone extraction before a laparoscopic cholecystectomy. Factors that predict choledocholithiasis include:

- Abnormal liver function tests, particularly bilirubin and alkaline phosphatase levels
- Common bile duct dilation of 8 mm or greater
- Common bile duct stones identified with ultrasonography.⁹

Another approach is simply to proceed with laparoscopic cholecystectomy and to perform cholangiography intraoperatively. If cholangiography demonstrates stones, these can sometimes be removed laparoscopically, or the surgery can be converted to open surgical exploration of the common bile duct. However, in most cases, common bile duct stones are removed via endoscopic sphincterotomy within 1 or 2 days of cholecystectomy.

Laparoscopic surgery for patients with gallstone pancreatitis

Most patients (90%) with gallstone pancreatitis have a mild episode. Their pain usually resolves promptly and their liver enzyme levels (aspartate aminotransferase, alanine aminotransferase, alkaline phosphatase, bilirubin, serum amylase, and serum lipase) decline within 3 to 4 days of admission to the hospital with supportive care alone. (Supportive care consists of giving nothing by mouth and maintaining the patient on intravenous hydration, parenteral analgesics, and antibiotics.)

These patients should undergo laparoscopic cholecystectomy with intraoperative cholangiography within a month to prevent further episodes of pancreatitis. They should not undergo preoperative ERCP, as it may exacerbate the pancreatitis.⁹ If bile duct stones are found during cholecystectomy, endoscopic sphincterotomy should be performed within the next few days.

Outcomes of cholecystectomy

Cholecystectomy remains the best therapy for symptomatic gallstone disease. It is effective and safe, with low rates of complications (14%) and mortality (0.17%), particularly if performed electively in patients younger than 65 years.

The number and severity of episodes of biliary colic vary considerably from patient to patient; some have relatively mild episodes for years, and others have a severe solitary attack. Cholecystectomy is indicated across this spectrum of patients. However, when to perform the procedure is ultimately determined by the patient.

In patients with typical biliary colic, symptoms resolve after cholecystectomy in more than 85% of cases.¹ However, patients with gallstones who have atypical pain or nonspecific symptoms such as belching, bloating, and indigestion are less likely to have resolution of their symptoms after the gallbladder is removed. Therefore, these patients should have further studies, which may include an upper gastrointestinal tract contrast study, endoscopy, and colonoscopy. If the additional studies are normal, the patient can be offered a cholecystectomy with the caveat that the symptoms may not improve.

Laparoscopic cholecystectomy: Advantages and disadvantages

Laparoscopic cholecystectomy is now the gold standard in the treatment of symptomatic gallbladder disease. More than 500,000 of these procedures are performed every year in the United States.¹

Laparoscopic cholecystectomy is safe, and compared with open cholecystectomy, the previous gold standard, it is associated with less pain, fewer complications,^{10,11} and faster recovery. Mortality rates for laparoscopic

Gallstone pancreatitis resolves in 3–4 days with supportive care alone



cholecystectomy are 0.06% to 0.1%, vs 0 to 0.4% for open cholecystectomy.^{10,11} The mean length of hospital stay after laparoscopic cholecystectomy is 1.6 days vs 4.3 days for open cholecystectomy, and patients return to work in half the time (15 vs 31 days).¹¹

From 2% to 5% of elective laparoscopic cholecystectomies need to be converted to an open procedure, usually owing either to inflammation that obscures the distinction between the cystic and common bile duct or to bleeding that cannot be controlled laparoscopically.

Surgical complications. Significant complications, some resulting in death, can occur with laparoscopic cholecystectomy, and intraoperative injuries that occur during laparoscopic cholecystectomy are more likely to result in death than are those that occur during open cholecystectomy.¹⁰ Laparoscopic cholecystectomy is also associated with a higher incidence of bile duct injury than is open cholecystectomy (0.6% vs 0.1%–0.25%).¹⁰ More than half of patients with bile duct injury need operative repair, and up to 25% of the repairs may need to be revised because of stricture formation.^{10–12}

An analysis of data from a national survey of almost 80,000 laparoscopic cholecystectomy procedures performed at 4,300 hospitals revealed that injury to the bowel or major vessels was associated with death rates of 8% and 5%, respectively.¹⁰

The rate of complications from laparoscopic cholecystectomy decreases as the number of operations the surgeon has performed increases: 21% if the surgeon has performed fewer than 10 procedures vs 12% if the surgeon has performed more than 50.¹⁰

Conversion rates in patients with acute cholecystitis. Although laparoscopic cholecystectomy is the procedure of choice in patients with acute cholecystitis, rates of conversion to an open procedure range from 5% to 40%.^{13–16} In most cases of conversion, either laparoscopy was performed more than 3 days after the onset of symptoms or the gallbladder was gangrenous. After 3 days, the edema in the gallbladder progresses to a woody induration that obscures the anatomy in the area and makes it harder to distinguish the cystic duct from the bile duct, thus

increasing the risk of bile duct injury. If laparoscopic cholecystectomy is performed within 3 days of symptom onset, the conversion rate is 23% to 27%; if performed after 3 days, the rate is 47% to 59%.^{13–16} Patients with gangrenous cholecystitis have a conversion rate of 35% to 49%.^{16,17}

Cholecystostomy tube placement

A cholecystostomy tube is indicated in some patients with acute cholecystitis. Historically, surgeons used to place a tube when they started an open cholecystectomy but could not complete it, either because the patient was critically ill and was felt to be too unstable to complete the planned procedure or because the inflammation encountered precluded a safe cholecystectomy.

Now, for critically ill patients in intensive care, the accepted practice is for a radiologist to place a cholecystostomy tube percutaneously via the liver with ultrasound guidance. The procedure can be done safely at the bedside without general anesthesia. The complication rate is low, and mortality is related primarily to comorbidities.¹⁸

The role of laparoscopic cholecystectomy in cirrhosis, diabetes, pregnancy

Cirrhosis. Mortality rates of 10%, mainly from liver failure and sepsis,¹⁹ have been reported in patients with severe cirrhosis (Child-Pugh grade C) who undergo cholecystectomy.¹⁹ Laparoscopic cholecystectomy can be performed in patients with Child grade A or B cirrhosis,²⁰ but even in carefully selected patients the complication rate is 32%.²⁰

Diabetes alone is not a significant factor in patients with gallstones. Diabetic patients with asymptomatic gallstones do not require prophylactic cholecystectomy, as was advised 20 to 25 years ago.

Pregnant women can safely undergo laparoscopic cholecystectomy, particularly during the second trimester and with the help of the obstetric team.²¹

■ ACUTE ACALCULOUS CHOLECYSTITIS

The incidence of acute acalculous (ie, without stones) cholecystitis in the general population ranges from 2% to 15%. In the past, nearly all

Cholecystostomy tubes can be placed percutaneously at the bedside

Most patients with acute acalculous cholecystitis have abnormal liver function tests and leukocytosis

patients with acute acalculous cholecystitis had previously sustained trauma or burns, undergone major surgery, or developed multi-organ system failure. More recently, the incidence has been increasing in ambulatory patients, particularly in elderly men with atherosclerosis or immunosuppression.^{6,22,23}

Acute acalculous cholecystitis can rapidly progress to gangrene and perforation, since the pathophysiologic process appears to be transmural infarction of the gallbladder wall rather than inflammatory changes associated with stones.^{6,22,23}

Signs and symptoms

Most patients with acute acalculous cholecystitis have abdominal pain, fever, and right upper quadrant tenderness or signs of local peritoneal irritation. Almost all have abnormal liver function tests and leukocytosis.

Diagnosis

Imaging studies for acute acalculous cholecystitis include cholescintigraphy, ultrasonography, and computed tomography. Of these three, ultrasonography and computed tomography have higher specificity in critically ill patients.²³ Cholescintigraphy is accurate in about 95% of ambulatory patients, but the false-positive rate is 30% to 40% in critically ill hospital patients, particularly those who are on hyperalimentation.⁵

Treatment

Treatments for acute acalculous cholecystitis include percutaneous cholecystostomy, open cholecystostomy, and cholecystectomy. Even though acute acalculous cholecystitis may result from infarction of the gallbladder wall, decompression of the gallbladder by placement of a cholecystostomy tube may be sufficient to control the inflammatory process.

If cholecystectomy is necessary, the degree of inflammation and induration usually precludes the laparoscopic approach.

The mortality rate is 50% if surgery is not performed.²³ The mortality rate associated with surgical intervention in these patients ranges from 6% to 9%, which is significantly higher than with calculous disease.^{22,23} The mortality is related primarily to the patient's overall condition.

■ BILIARY DYSKINESIA

Management of biliary dyskinesia is challenging. Patients typically have chronic symptoms consistent with biliary colic and an abnormal gallbladder ejection fraction; however, ultrasonography, even if repeated, does not demonstrate stones, nor does oral cholecystography.

Diagnosis

Evaluation of a patient with possible biliary dyskinesia should include upper endoscopy and cholecystokinin-stimulated cholescintigraphy. Endoscopic abnormalities such as gastritis, ulcer, or reflux should be treated before considering cholecystectomy.

Treatment

If endoscopic testing is normal and the gallbladder ejection fraction on cholescintigraphy is less than 35%, the patient may benefit from cholecystectomy. Several studies reported that 80% to 100% of carefully selected patients had complete resolution of, or significant improvement in, their symptoms.^{8,24,25} Pathologic examination of the gallbladders of these patients demonstrated acalculous chronic cholecystitis in 67% to 95%.^{8,24,25}

However, one report²⁴ cautioned that an abnormal gallbladder ejection fraction does not always indicate biliary disease, since about 20% of patients studied had symptomatic resolution without cholecystectomy.

■ GALLBLADDER POLYPS

Approximately 4% of the general population have gallbladder polyps.²⁶ Most of these are cholesterol polyps.²⁷ Others include adenomas, hyperplastic polyps, granulation, and adenomyomatosis.²⁸

Cholesterol polyps are almost always less than 10 mm in diameter, and often, more than one is found.²⁸ Adenomas tend to be larger (mean diameter 6 mm) and solitary.²⁸ Almost all malignant polyps are larger than 10 mm and solitary.²⁸ From 20% to 60% of patients with polyps also have gallstones.

Although some polyps cause symptoms consistent with biliary colic, most are asymptomatic and are found during ultrasonography



for investigation of nonspecific upper abdominal discomfort.

Patients with symptoms or with a polyp 10 mm or greater in diameter should undergo cholecystectomy. Patients without symptoms who have polyps smaller than 10 mm may undergo follow-up ultrasonography in 6 months to monitor polyp growth. Enlargement of a polyp may be an indication for cholecystectomy.²⁸

■ GALLBLADDER CANCER

Gallbladder cancer is relatively uncommon and has a dismal prognosis. It is responsible for about 6,500 deaths annually in the United States, or approximately 4% of all cancer deaths.²⁹ Eighty percent to 85% of patients with gallbladder cancer have cholelithiasis.

Older studies suggested an association between calcium in the gallbladder wall ("porcelain gallbladder") and gallbladder cancer: from 20% to 60% of patients with porcelain gallbladder had gallbladder cancer. However, a more recent review³⁰ demonstrated no cancer in 15 specimens of porcelain gallbladder, which represented 0.14% of 10,741 cholecystectomies performed from 1955 to 1998.

More than 90% of gallbladder cancers are adenocarcinomas, ranging from well differentiated to poorly differentiated.

Patients with early-stage gallbladder cancer have no symptoms, although if they have cholelithiasis they may have symptoms of biliary colic. Elderly patients with persistent, progressive right upper quadrant pain are likely to have gallbladder cancer, particularly if they develop jaundice and have a palpable mass.

Diagnosis

Laboratory studies are normal unless the biliary tree is obstructed. Useful imaging studies include ultrasonography and computed

tomography, but neither demonstrates any abnormalities if the cancer is in the early stages. These studies also cannot distinguish a neoplasm from an extensive inflammatory process. However, if either study does demonstrate a mass, particularly if the process invades the liver parenchyma, an image-guided biopsy should be performed.

Treatment

If cancer is confirmed, no surgical intervention is indicated. However, patients with jaundice and a gallbladder mass with or without extension into the liver are candidates for endoscopic or percutaneous stenting.

Surgical management of gallbladder cancer, especially radical resection, remains controversial. In most cases, a patient undergoes cholecystectomy for symptomatic gallstones, and cancer is only detected at the time of pathologic analysis.

The prognosis depends on the depth of invasion into the gallbladder wall and regional lymph node involvement. Patients with stage 1 disease (involvement of the mucosa or of the mucosa and muscular layer) have an 80% 5-year survival following simple cholecystectomy.^{31,32}

The management of advanced cancer is controversial (gallbladder cancer is considered advanced if there is tumor penetration through the gallbladder wall, invasion into adjacent organs, or positive regional nodes). Should these patients undergo reexploration for more radical resection, such as liver resection and extensive lymphadenectomy of the porta hepatis? Although some experts advocate very aggressive surgery, the 5-year survival rate is only about 10% in patients with stage 2 disease (penetration through the wall of the gallbladder), and 0% in patients with regional lymph node involvement.³³ Based on these data, our policy has been not to perform reexploratory surgery in patients found to have gallbladder cancer.



Gallbladder cancer often carries a dismal prognosis

■ REFERENCES

1. Roslyn JJ, Binns GS, Hughes EF, et al. Open cholecystectomy. A contemporary analysis of 42,474 patients. *Ann Surg* 1993; 218:129-137.
2. Everhart JE, Khare M, Hill M, Mauver KR. Prevalence and ethnic differences in gallbladder disease in the United States. *Gastroenterology* 1999; 117:632-639.
3. Hermann RE, editor. *Manual of Surgery of the Gallbladder, Bile Ducts, and Exocrine Pancreas*. New York: Springer-Verlag, 1979.
4. Kelly TR. Surgical treatment of gallstone pancreatitis. *Contemp Surg* 1991; 38:13-19.
5. Carroll BA. Preferred imaging techniques for the diagnosis of cholecystitis and cholelithiasis. *Ann Surg* 1989; 210:1-12.
6. Savoca PE, Longo WE, Zucker KA, et al. The increasing prevalence of acalculous cholecystitis in outpatients. Results of a 7-year study. *Ann Surg* 1990; 211:433-437.
7. Chatziannou SN, Moore WH, Ford PV, Dhekne RD. Hepatobiliary scintigraphy



is superior to abdominal ultrasonography in suspected acute cholecystitis. *Surgery* 2000; 127:609–613.

8. **Sorenson MK, Fancher S, Lang N, et al.** Abnormal gallbladder ejection fraction predicts success of cholecystectomy in patients with biliary dyskinesia. *Am J Surg* 1993; 166:672–675.
9. **Santucci L, Nataline G, Sarpi L, Fiorucci S, Solenas A, Morelli A.** Selective endoscopic retrograde cholangiography and preoperative bile duct stone removal in patients scheduled for laparoscopic cholecystectomy: a prospective study. *Am J Gastroenterol* 1996; 91:1326–1330.
10. **Deziel DJ, Millikan KW, Economou SG, Doolas A, Ko ST, Airan MC.** Complications of laparoscopic cholecystectomy: a national study of 4,292 hospitals and an analysis of 77,604 cases. *Am J Surg* 1993; 165:9–14.
11. **Kane RL, Lurie N, Borbas C, et al.** The outcomes of elective laparoscopic and open cholecystectomies. *J Am Coll Surg* 1995; 180:136–145.
12. **Woods MS, Traverso LW, Kozrek RA, et al.** Characteristics of biliary tract complications during laparoscopic cholecystectomy: a multi-institutional study. *Am J Surg* 1994; 167:27–34.
13. **Chandler CF, Lane JS, Ferguson P, Thompson JE, Ashley SW.** Prospective evaluation of early versus delayed laparoscopic cholecystectomy for treatment of acute cholecystitis. *Am Surg* 2000; 66:896–900.
14. **Avrutis O, Friedman SJ, Meshoulm J, Haskell L.** Safety and success of early laparoscopic cholecystectomy for treatment of acute cholecystitis. *Surg Laparosc Endosc Percutan Tech* 2000; 10:200–207.
15. **Pessaux P, Tuech JJ, Rouge C.** Laparoscopic cholecystectomy in acute cholecystitis. A comparative study in patients with acute vs chronic cholecystitis. *Surg Endosc* 2000; 14:358–361.
16. **Eldar S, Sabo E, Nash E, Abrahamson J, Matter I.** Laparoscopic cholecystectomy for acute cholecystitis: prospective trial. *World J Surg* 1997; 21:540–545.
17. **Merriam LT, Kanaan SA, Darres LG, Angelos P.** Gangrenous cholecystitis: an analysis of risk factors and experience with laparoscopic cholecystectomy. *Surgery* 1999; 126:685–686.
18. **Chang L, Moonka R, Stelzner M.** Percutaneous cholecystostomy for acute cholecystitis in veteran patients. *Am J Surg* 2000; 180:198–202.
19. **Bloch RS, Allaben RD, Walt AJ.** Cholecystectomy in patients with cirrhosis. A surgical challenge. *Arch Surg* 1985; 120:669–672.
20. **Sleeman D, Nomias N, Levi D, et al.** Laparoscopic cholecystectomy in cirrhotic patients. *J Am Coll Surg* 1998; 187:400–403.
21. **Cosenza CA, Soffari B, Jabbour N, et al.** Surgical management of biliary gallstone disease during pregnancy. *Am J Surg* 1999; 178:545–548.
22. **Kalliatas S, Ziegler DW, Flancbaum L, Choban PS.** Acute acalculous cholecystitis: incidence, risk factors, diagnosis, and outcome. *Am Surg* 1998; 64:471–475.
23. **Kuang AA, Hirose R, Kirkwood KS.** Acute acalculous cholecystitis: expanding the population at risk. *Contemp Surg* 2001; 57:245–253.
24. **Goncalves RM, Harris JA, Rivera DE.** Biliary dyskinesia: natural history and surgical results. *Am Surg* 1998; 64:493–498.
25. **Mishkind MT, Pruitt RF, Bambini DA, et al.** Effectiveness of cholecystokinin-stimulated cholecintigraphy in the diagnosis and treatment of acalculous gallbladder disease. *Am Surg* 1997; 63:769–774.
26. **Jorgensen T, Jensen KH.** Polyps in the gallbladder. A prevalence study. *Scand J Gastroenterol* 1990; 25:281–286.
27. **Koga A, Watanabe K, Kukuyama T, et al.** Diagnosis and operative indications for polypoid lesions of the gallbladder. *Arch Surg* 1988; 123:26–29.
28. **Shinkai H, Kimura W, Tetsuhiro M.** Surgical indications for small polypoid lesions of the gallbladder. *Am J Surg* 1998; 175:114–116.
29. **Wanebo HJ, Castle WN, Fechner RE.** Is carcinoma of the gallbladder a curable lesion? *Ann Surg* 1982; 195:624–631.
30. **Tofigh S, McFadden DW, Cortina GR, et al.** Porcelain gallbladder is not associated with gallbladder carcinoma. *Am Surg* 2001; 67:7–10.
31. **Morrow CE, Sutherland DE, Florack G, et al.** Primary gallbladder carcinoma: significance of subserosal lesions and results of aggressive surgical treatment and adjuvant chemotherapy. *Surgery* 1983; 94:709–713.
32. **Shiarai Y, Yoshida K, Tsukada, et al.** Early carcinoma of the gallbladder. *Eur J Surg* 1992; 158:545–548.
33. **Benoist S, Panis Y, Fagniez PL, et al.** Long-term results after curative resection for carcinoma of the gallbladder. *Am J Surg* 1998; 175:118–122.

ADDRESS: David P. Vagt, MD, Department of General Surgery, A110, The Cleveland Clinic Foundation, 9500 Euclid Avenue, Cleveland, OH 44195; e-mail vogtd@ccf.org.