



SCOTT A. McHAM, DO
Department of General Internal Medicine,
The Cleveland Clinic

ALAN L. HULL, MD, PhD
Department of General Internal Medicine,
The Cleveland Clinic

A 47-year-old alcoholic man with progressive abnormal gait

A 47-YEAR-OLD ALCOHOLIC MAN is admitted to a community hospital because he is extremely weak and cannot walk. He has a long history of alcohol abuse, consuming 12 beers per day over the last 25 years, and of malnutrition, with a 60-pound weight loss over the previous 6 months.

Physical examination. Blood pressure 105/80 mm Hg, pulse rate 80 per minute, respiration rate 16 per minute, temperature 96.8°F (36.0°C). Cranial nerves II through XII are normal and there are no tremors or flap, but the patient cannot stand or walk without assistance.

Laboratory data. Analysis of blood and serum reveals normal potassium, chloride, creatinine, glucose, liver function, white blood cell count, hemoglobin, and hematocrit levels, but the following are abnormal:

- Sodium 135 mmol/L (normal 137–144)
- Blood urea nitrogen 30 mg/dL (normal 6–21)
- Platelet count $97 \times 10^9/L$ (normal 150–400).

The urine drug screen is negative, except for an alcohol level of less than 10 mg/dL.

Hospital course. The patient remains in the hospital for several days that are uneventful except for intensive physical rehabilitation; at discharge his motor strength is 3.5 to 4 on a scale of 5 in both legs and 5 on a scale of 5 in both arms. He can walk 100 feet with assistance. He is discharged to a nursing home with the diagnoses of acute and chronic alcoholism, severe malnutrition, and ataxia with bilateral leg weakness due to deconditioning.

Outpatient follow-up. Approximately 1 month later, the patient visits the outpatient clinic for the first time for evaluation of his ataxia. During the consultation, he reveals

that for 6 weeks before his hospitalization he experienced progressive unsteadiness on his feet with episodes of falling. He cannot fully recall the events before or during his hospital stay. Since his discharge, his ataxic symptoms have improved.

On examination, cranial nerves II through XII are normal, motor strength is 5 on a scale of 5 in both arms and legs, and senses are normal, including vibration and proprioception. However, his memory is impaired and he has horizontal nystagmus of left and right lateral gaze, abnormal rapid alternating movements, and gait ataxia. He has a wide-based gait and cannot walk a tandem line.

His electrolytes, glucose, liver function, complete blood count, vitamin B₁₂, and folate levels are all normal. Serologic tests for human immunodeficiency virus and syphilis are negative.

■ DIFFERENTIAL DIAGNOSIS

1 The differential diagnosis includes which of the following?

- ☐ Cerebellar infarction
- ☐ Central pontine myelinolysis
- ☐ Acoustic neuroma
- ☐ Wernicke encephalopathy
- ☐ Subdural hematoma
- ☐ Subacute spinal cord compression

All these diagnoses can cause gait ataxia, usually over an extended time, along with varying degrees of memory and cognitive impairment.

Cerebellar infarction is unlikely since it is associated initially with the sudden onset of gait ataxia, headache, nausea, vomiting, dizziness

Findings:

- Alcoholism
- Weight loss
- Weakness
- Ataxia
- Impaired memory



ness, ipsilateral clumsiness, and dysarthria. This patient has only gait ataxia.

Acoustic neuroma is the most common type of cranial nerve tumor. The initial symptom is usually partial or complete nerve deafness. As the tumor grows larger, the ipsilateral cranial nerves V and VII become involved, and when the tumor is large, ipsilateral cerebellar ataxia can occur. All patients who develop hearing loss between the ages of 25 and 60 should be evaluated for an acoustic neuroma.

Wernicke encephalopathy is caused by inadequate intake or absorption of thiamine, often in the setting of severe alcoholism. It evolves over days to weeks and has three features that may occur alone or together:

- Abnormal eye movements, which begin with nystagmus and lateral rectus or horizontal gaze paresis and progress to complete ophthalmoplegia; the pupils are usually spared
- Ataxia of gait and stance, often accompanied by lower-limb intention tremor and dysmetria (the arms are usually not affected, and dysarthria is usually absent)
- Altered mentation, the earliest signs of which are inattentiveness, mental slowing (abulia), and impaired memory.

Treatment is with intravenous or intramuscular thiamine, rehydration, correction of electrolyte abnormalities, alcohol cessation, and nutritional therapy. Without treatment, patients become lethargic, and their condition progresses to coma and death.

While Wernicke encephalopathy (especially a partially treated case) is possible and should be included in the differential diagnosis, it is unlikely, in view of the duration of the symptoms at presentation.

Subdural hematoma is unlikely, since the patient has no history of trauma (although symptoms can occur weeks to months after an injury, and in this case the patient's history may be inaccurate). Chronic subdural hematomas present weeks to months after the injury. These hematomas may become quite large without causing symptoms. The neurologic findings may vary from no or minimal deficit to focal neurologic symptoms that may be transient or progressive.

Subacute spinal cord compression can present with gait ataxia and motor weakness.

TABLE 1

Alcohol-related neurologic disorders

Immediate effects

Intoxication
Withdrawal

Fetal exposure to alcohol

Fetal alcohol syndrome

Nutritional diseases

Wernicke-Korsakoff syndrome
Polyneuropathy
Optic neuropathy
Pellagra

Liver diseases

Hepatic stupor or coma
Chronic hepatocerebral degeneration

Diseases of uncertain pathogenesis

Cerebellar degeneration
Marchiafava-Bignami disease
Alcoholic cardiomyopathy and myopathy
Alcoholic dementia and cerebral atrophy
Central pontine myelinolysis

Most patients report local back pain or radicular pain that precedes other neurologic symptoms. This diagnosis is unlikely since the patient reported no pain, sensory changes, bowel incontinence, or bladder retention, and did not have the Babinski sign.

Central pontine myelinolysis is a demyelinating disorder that occurs most often in alcoholic or malnourished patients and is often associated with severe hyponatremia that is iatrogenically corrected too rapidly. This diagnosis seems unlikely, since this patient's sodium derangement is minor and alcoholism has many other neurologic effects that are more common (TABLE 1).¹ However, this is in fact what our patient has.

CASE CONTINUED

Our patient undergoes a magnetic resonance imaging (MRI) scan of the brain, which reveals a confluent well-defined focus of hyperintensity centrally in the pons on fluid-attenuated inversion recovery (FLAIR) and T2-weighted images that corresponds to a similar focus of hypointensity on the T1-weighted

**He drinks 12
beers per day,
and has lost
60 lb in
6 months**

Central pontine myelinolysis

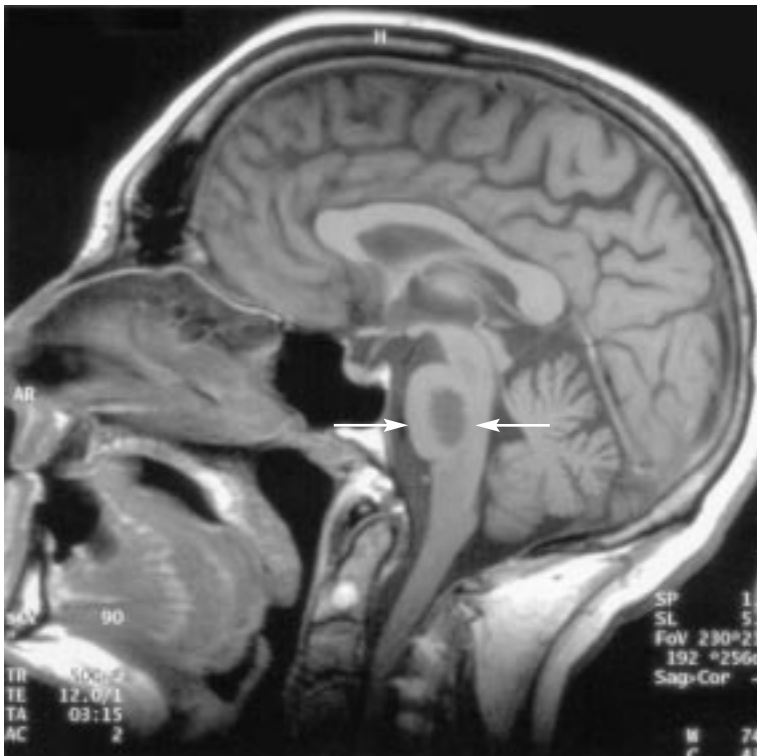


FIGURE 1. Magnetic resonance imaging scan, T1-weighted sagittal view, showing a hypointense area in the pons (arrows).

images (FIGURE 1). These findings are consistent with central pontine myelinolysis.

He undergoes treatment with alcohol cessation, multivitamin and thiamine supplementation, and physical therapy. At a 2-month follow-up office visit, he continues to improve with no further episodes of falling. Neurologic examination is normal except for his gait, which is approaching normal, although he still has difficulty walking a tandem line.

DISCUSSION: CENTRAL PONTINE MYELINOLYSIS

Signs and symptoms

The classic clinical picture of central pontine myelinolysis is confusion, quadriplegia, pseudobulbar palsy, and pseudocoma or a “locked-in syndrome” (a condition in which intellectual activity is preserved but cannot be expressed because of total incapacity to express voluntary responses) over a period of

several days.² However, the clinical manifestations can range from asymptomatic to coma due to associated conditions, and the severity of the clinical presentation does not correlate with the size of the lesion.^{3,4} The broad range of manifestations can make the diagnosis difficult.

Clinical suspicion must be high because the initial diagnosis is clinical. Most cases of central pontine myelinolysis are symptomatic,⁴ and these symptoms may include lethargy, decreased level of consciousness, mutism, dysarthria, tremor, ataxia, spastic quadriparesis, ocular motor abnormalities, pseudobulbar palsy, and coma.⁵

Our patient's presenting symptoms of gait ataxia progressing to bilateral lower extremity motor weakness and memory impairment are consistent with previous observations in the literature.^{5–8}

Mechanism: Sodium derangement, malnutrition, or alcoholism?

The mechanism involved in the genesis of central pontine myelinolysis is not fully understood; alcoholism, malnutrition, and sodium derangements are the contending culprits.

Central pontine myelinolysis was first described in 1959 by Adams et al,⁹ who attributed it to a nutritional deficiency because all the patients in their series were malnourished or alcoholic. Alcoholism is associated with up to 78% of cases of central pontine myelinolysis.^{10,11} However, studies in the 1980s linked the disorder with rapid correction of hyponatremia,^{12,13} which has refocused attention on sodium.

In a 12-year retrospective analysis of central pontine myelinolysis at autopsy, Newell et al⁴ concluded that the disease is associated with a rapid rise in serum sodium levels, but that alcoholism, chronic liver disease, and liver transplantation can contribute to it.

However, even though serum sodium derangement has been strongly linked to central pontine myelinolysis, it is not absolutely necessary, as shown by reports of cases in alcoholic patients who were normonatremic.^{14,15} In addition, Mast et al¹⁶ propose that iatrogenic sodium restoration may not really be the mechanism behind all cases of central pontine



myelinolysis that develop after sodium restoration. Instead, they suggest that in some patients the clinical onset may be a delayed response to initially asymptomatic demyelination, and that normal sodium levels at admission should not exclude the diagnosis.

Our patient provides further evidence that central pontine myelinolysis is multifactorial. His serum sodium concentration was 135 mmol/L, which is only 2 mmol/L below the “normal” range; in contrast, in most reported cases in which the sodium level was abnormal it was above 160 mmol/L or below 120 mmol/L.¹⁷ His symptoms began 2 to 3 days before his initial hospitalization and there is no record of his being severely hyponatremic. Suspected contributing factors in our patient are chronic alcoholism and malnutrition, which reflect the original 1959 report by Adams et al.⁹

In cases triggered by sodium correction, neurologic abnormalities may appear within 3 days of the correction.⁵ However, there is no such inciting event in patients who present only with chronic alcoholism or malnutrition.

Histologically, the lesions of central pontine myelinolysis closely resemble those of nutritional optic neuropathy and vitamin B₁₂ myelopathy, suggesting that nutritional factors are important.² Messert et al¹⁰ suggest that demyelination is associated with ischemia of small perforating arteries caused by pontine edema.

Other possible factors include changes in brain electrolyte levels, hydration, blood-brain barrier competence, and oxidative stress, but the relationship between these factors, the mechanism of myelinolysis, and the relative vulnerability of particular brain territories are all unclear.¹⁸

Imaging studies

Preclinical detection of abnormal pontine signal properties with magnetic resonance relaxometry may identify patients at high risk for developing central pontine myelinolysis.¹⁹ The most sensitive diagnostic imaging study is

T2-weighted MRI, but it may not detect changes for several weeks to months after the onset of symptoms.⁵

Reports of similar cases in alcoholic patients have revealed that brainstem lesions can be massive while causing only relatively minor neurologic symptoms and signs.

Treatment

Although two case reports noted improvements in patients with central pontine myelinolysis using hyperbaric oxygen or thyrotropin-releasing hormone, no studies have demonstrated an effective treatment.⁵ Sequelae such as depression, psychosis, and parkinsonism can be treated, and supportive care may prevent complications in severe cases (eg, coma and paraplegia).⁵ Alcohol detoxification and general supportive treatment have proven beneficial.

Prognosis

The outcome may range from complete recovery to little or no improvement to death.⁵ Fortunately, our patient is recovering.

Neurologic signs usually regress nearly completely, which suggests considerable reversibility or compensation of brainstem lesions in alcohol-related central pontine myelinolysis.

SUMMARY

- Central pontine myelinolysis should be considered in the differential diagnosis of a patient with a history of alcoholism and malnutrition presenting with ataxia, regardless of serum sodium values.
- T2-weighted images are the most sensitive imaging technique, but changes may not be evident for weeks after the insult, and in addition, the insult may not be known.
- Supportive care is important to prevent complications, but no treatment has been found to be effective in treating the illness. Patient outcomes vary considerably and are difficult to predict.

Suspect central pontine myelinolysis in a malnourished alcoholic with ataxia, regardless of sodium values

REFERENCES

1. Adams RD, Victor M, Ropper AH. Alcohol and alcoholism. In Adams RD, Victor M, Ropper AH, editors: *Principles of Neurology*, 6th ed. New York: McGraw-Hill, 1997:1166–1185.
2. Wright DG, Laureno R, Victor M. Pontine and extrapontine myelinolysis. *Brain* 1979; 102:361–385.
3. Adams RD, Victor M, Ropper AH. The acquired



metabolic disorders of the nervous system.

In Adams RD, Victor M, Ropper AH, editors: *Principles of Neurology*, 6th ed. New York: McGraw Hill, 1996:1108–1137.

4. **Newell KL, Kleinschmidt-DeMasters BK.** Central pontine myelinolysis at autopsy; a twelve-year retrospective analysis. *Neurol Sci* 1996; 142:134–139.
5. **Karp BI, Laureno R.** Pontine and extrapontine myelinolysis: a neurologic disorder following rapid correction of hyponatremia. *Medicine (Baltimore)* 1993; 72:359–373.
6. **Brunner JE, Redmond JM, Haggard AH, Elias SB.** Central pontine myelinolysis after rapid correction of hyponatremia: a magnetic resonance imaging study. *Ann Neurol* 1988; 23:389–391.
7. **Defbvre L, Rogelet P, Destee A, Verier A.** Regressive dystonia and cerebellar ataxia: two unusual symptoms in central pontine myelinolysis. *J Neurol* 1995; 242:450–454.
8. **Thompson PD, Miller D, Gledhill RF, Rossor MN.** Magnetic resonance imaging in central pontine myelinolysis. *J Neurol Neurosurg Psychiatry* 1989; 52:675–677.
9. **Adams RA, Victor M, Mancell EL.** Central pontine myelinolysis: a hitherto undescribed disease occurring in alcoholics and malnourished patients. *Arch Neurol Psychiatry* 1959; 81:303–308.
10. **Messert B, Orrison WW, Hawkins MJ, Quagliari CE.** Central pontine myelinolysis. Considerations on etiology, diagnosis and treatment. *Neurology* 1979; 29:147–160.
11. **Laubenberg J, Schneider B, Ansorge O, et al.** Central pontine myelinolysis: clinical presentation and radiologic findings. *Eur Radiol* 1996; 6:177–183.
12. **Kleinschmidt-Demasters B, Norenberg M.** Rapid correction of hyponatremia causes demyelination: relation to central pontine myelinolysis. *Science* 1981; 211:1068–1080.
13. **Laureno R.** Central pontine myelinolysis following rapid correction of hyponatremia. *Ann Neurol* 1983; 13:232–242.
14. **Mascalchi M, Cincotta M, Piazzini M.** Case report: MRI demonstration of pontine and thalamic myelinolysis in a normonatremic alcoholic. *Clin Radiol* 1993; 47:137–138.
15. **Laitt RD, Thornton M, Goddard P.** Pontine myelinolysis in a normonatremic alcoholic. *Clin Radiol* 1993; 48:432–433.
16. **Mast H, Gordon PH, Mohr JP, Tatemichi TK.** Central pontine myelinolysis: clinical syndrome with normal serum sodium. *Eur J Med Res* 1995; 1:168–170.
17. **Endo Y, Oda M, Hara M.** Central pontine myelinolysis: a study of 37 cases in 1,000 consecutive autopsies. *Acta Neuropathol* 1981; 53:145–153.
18. **Laureno R, Karp BI.** Myelinolysis after correction of hyponatremia. *Ann Intern Med* 1997; 126:57–62.
19. **Sullivan EV, Pfefferbaum A.** Magnetic resonance relaxometry reveals central pontine abnormalities in clinically asymptomatic alcoholic men. *Alcohol Clin Exp Res* 2001; 25:1206–1211.

ADDRESS: Alan L. Hull, MD, PhD, Department of Internal Medicine, E13, The Cleveland Clinic Foundation, 9500 Euclid Avenue, Cleveland, OH 44195; e-mail hulla1@ccf.org.