

ALBERT W. CHAN, MD, MS

Interventional cardiology fellow, Department of Cardiovascular Medicine, Cleveland Clinic

DAVID J. MOLITERNO, MD

Associate professor of medicine, Department of Cardiovascular Medicine, Cleveland Clinic

In-stent restenosis: Update on intracoronary radiotherapy

ABSTRACT

Stents eliminate vessel recoil and remodeling, two of the three major causes of restenosis after balloon angioplasty, but they promote the third cause, neointimal proliferation. Intracoronary radiotherapy at the time of successful repeat balloon angioplasty is proving effective in treating in-stent restenosis and lowering rates of recurrence. Current techniques and their safety and efficacy are discussed.

KEY POINTS

Although intracoronary radiotherapy can attenuate restenosis, it does not cure the disease.

The key is matching the irradiation to the injured area, so as not to undertreat the restenotic lesion.

To lower the risk of late thrombosis after intracoronary radiotherapy, it is recommended that clopidogrel be given for at least 6 months, and for 12 months if a new stent was placed. Aspirin is also given.

IN THE ERA OF ROUTINE stenting with percutaneous coronary angioplasty, in-stent restenosis remains an important limitation and is becoming an epidemic. Intracoronary radiotherapy has emerged as a promising means of reducing the risk of recurrent restenosis.

In this article, we review how intracoronary radiotherapy is performed and the major issues related to its use. We also briefly discuss other novel strategies for preventing in-stent restenosis that may redefine the role of intracoronary radiotherapy.

IN-STENT RESTENOSIS: A NEW EPIDEMIC

A clear benefit of coronary stenting has been demonstrated in clinical trials.¹⁻³ As a result, about 80% of percutaneous coronary interventions now involve stent implantation. However, in-stent restenosis remains an important problem. In the EPISTENT (Evaluation of Platelet IIb/IIIa Inhibition in Stenting) trial,⁴ as many as 8.7% of cases required target vessel revascularization within 6 months of stent placement. If we consider that more than 700,000 percutaneous coronary procedures will be performed in the United States in 2001, based on a cost of \$20,000 per case, a total of \$1.2 billion will be spent this year alone to treat in-stent restenosis.⁵ In-stent restenosis has thus become an epidemic and an economic burden on society.

THERAPEUTIC OPTIONS FOR IN-STENT RESTENOSIS

Although coronary stents reduce restenosis by preventing early recoil and late vascular



TABLE 1

Clinical trials of intracoronary radiation for in-stent restenosis

TRIAL	NUMBER OF PATIENTS	RADIATION DOSE	TARGET LESION	PRIMARY END POINTS
Gamma-radiation (iridium-192)				
SCRIPPS ¹³	55	8 to 30 Gray (Gy)	Post-angioplasty stenosis (38%) In-stent restenosis (62%)	Angiographic luminal loss at 6 months
Gamma-One ¹⁵	252	8 to 30 Gy	In-stent restenosis, lesion length < 45 mm	Death, myocardial infarction, or target lesion revascularization at 9 months
WRIST ¹⁴	100	15 Gy at 2.0 mm from the radiation source	In-stent restenosis, lesion length < 47 mm	Death, myocardial infarction, target lesion revascularization at 6 months
SVG WRIST ¹⁴	30	15 Gy at 2.4 mm from the radiation source	In-stent restenosis in venous bypass grafts, lesion length < 47 mm	Death, myocardial infarction, target lesion revascularization at 6 months
Long WRIST ¹⁶	120	15 Gy at 2.0 mm from the radiation source	Diffuse in-stent restenosis, 36 to 80 mm	Death, myocardial infarction, target lesion revascularization at 6 months
Beta-radiation				
Beta WRIST registry	50	20 Gy of yttrium-90 at 1.0 mm from the balloon-centered source wire	In-stent restenosis	Death, myocardial infarction, target lesion revascularization at 6 months
START ²¹	476	16 to 20 Gy of strontium-90 or yttrium-90 at 2.0 mm from the center	In-stent restenosis at 8 months	Target vessel revascularization
INHIBIT ²²	332	20 Gy of phosphorus-32 at 1.0 mm from the center	Focal or diffuse in-stent restenosis	Death, myocardial infarction, target lesion revascularization at 9 months

remodeling after percutaneous revascularization, they stimulate more neointimal proliferation than other interventional procedures.^{6,7} In-stent restenosis is considered an excessive healing process after tissue injury.

Neointimal proliferation is now seen as the exclusive cause of in-stent restenosis,⁸ and antiproliferation strategies have become the focus of attempts to reduce rates of in-stent restenosis. Conventional treatments such as repeat balloon angioplasty, cutting balloon angioplasty, repeat stenting, or atherectomy have been disappointing, with recurrence rates averaging 25% to 50% for focal resteno-

sis, and up to 65% for diffuse restenosis.⁹⁻¹²

■ THE BASIS FOR INTRACORONARY RADIOTHERAPY

Gamma-radiation and beta-radiation have been studied for the treatment of in-stent restenosis. Gamma-radiation, a form of electromagnetic energy carried by photons, can penetrate more than 10 mm of human tissue. Beta-radiation, carried by electrons, offers a wider range of energy and penetrates 2 to 3 mm of human tissue. In either case, the radiation can break the bonds of single-stranded

TABLE 2

Gamma-radiation for in-stent restenosis: Major adverse clinical events at follow-up

TRIAL	FOLLOW-UP PERIOD	DEATH, MYOCARDIAL INFARCTION, TARGET LESION REVASCULARIZATION (%)		P VALUE
		RADIATION GROUP	PLACEBO GROUP	
SCRIPPS ¹³	12 months	15.0	48.0	.01
	39 months	23.1	55.2	.01
Gamma-One ¹⁵	9 months	28.2	43.8	.02
WRIST ¹⁴	12 months	35.3	67.6	< .001
Long WRIST ¹⁶	12 months	38.3	61.7	.01

and double-stranded DNA in actively dividing cells within the vascular media and intima. In this way, intracoronary radiotherapy inhibits smooth muscle proliferation, prevents arterial remodeling, and delays healing responses after vascular injury. Intracoronary radiotherapy is often also referred to as vascular brachytherapy (brachy- is Latin for “localized”).

The radioactive isotopes available for clinical use in intracoronary radiotherapy are iridium-192 for gamma-radiation, and phosphorus-32, strontium-90, yttrium-90, and rhodium-188 for beta-radiation.

CLINICAL TRIALS OF INTRACORONARY RADIATION FOR IN-STENT RESTENOSIS

Trials of gamma-radiation

The efficacy of iridium-192 gamma-radiation in preventing recurrence of restenosis in patients with in-stent restenosis was established in three moderate-sized randomized, placebo-controlled trials (TABLES 1 and 2, FIGURE 1).^{13–15}

SCRIPPS trial. In 1997, the SCRIPPS (Scripps Coronary Radiation to Inhibit Proliferation Post-stenting) trial¹³ randomized 55 patients with restenosis after angioplasty alone or angioplasty with stenting to receive gamma-radiation or placebo after successful repeat angioplasty. The late luminal loss was significantly lower in the radiation group compared with the placebo group (1.85 ± 0.89 vs 2.43 ± 0.78 mm, $P = .02$).

Gamma-One trial. In the Gamma-One

trial,¹⁵ which enrolled 252 patients, iridium-192 gamma-radiation given after successful balloon angioplasty was associated with less need for target lesion revascularization (24% vs 42%, $P < .01$) and lower rates of binary angiographic restenosis (32% vs 55%, $P = .01$) compared with placebo.

WRIST. In WRIST (Washington Radiation for In-Stent Restenosis Trial),¹⁴ the iridium-192 gamma-radiation group also had lower rates of both target lesion revascularization (23% vs 63%, $P < .001$) and angiographic restenosis (19% vs 58%, $P = .001$) compared with placebo at 6 months. In the subgroup of patients with in-stent restenosis within saphenous vein grafts (in SVG WRIST, gamma-radiation was also found to lower revascularization rates.¹⁴

Long WRIST,¹⁶ which examined long lesions (mean stent length 70 mm), reported a 50% reduction ($P = .001$) in rates of target lesion revascularization.

Immediate procedural success was achieved in 100% of treated patients in all of these trials. It should be noted that many of the target lesion revascularizations in these trials were driven by repeat angiography (or angiographic restenosis) in the study protocols.

Trials of beta-radiation

Beta-radiation was initially studied as an adjunctive treatment to prevent restenosis in de novo lesions in native coronary arteries.^{17–19} Recently, it has also been tested as a treatment for in-stent restenosis (TABLE 1, FIGURE 1). Two randomized trials of beta-radiation for

Three studies show gamma-radiation prevents recurrence of in-stent restenosis



in-stent restenosis have been completed, but published reports are not yet available.

Waksman et al²⁰ examined the safety and efficacy of 20.6 Gray (Gy) of yttrium-90 beta-radiation in treating in-stent restenosis²⁰ in 50 patients, and compared the results against the placebo group in WRIST (gamma-radiation). At 6 months, the rate of target lesion revascularization was 26%, which compared favorably with the 50% reduction seen in WRIST.

START (Strontium-90 Treatment of Angiographic Restenosis Trial)²¹ randomized 476 patients to undergo either strontium-90 beta-radiation or placebo brachytherapy for in-stent restenosis. At 8 months, the rate of clinical restenosis was 24% in the radiation group vs 34% in the placebo group, a 34% risk reduction ($P = .008$). The rates of angiographic restenosis were 14% vs 42% ($P < .001$).

INHIBIT (Intimal Hyperplasia Inhibition with Beta In-stent Trial), a multicenter, randomized, placebo-controlled trial,²² demonstrated a 63% reduction (11% vs 29%) of recurrence of in-stent restenosis at 8 months using phosphorus-32 beta-radiation.

■ HOW INTRACORONARY RADIOTHERAPY IS PERFORMED

In view of the significant reduction of target lesion revascularization observed in the above trials, the US Food and Drug Administration has approved two catheter-based radiation devices for in-stent restenosis: the Beta-Cath (beta-radiation) system (Novoste, Norcross, GA) and the Checkmate (gamma-radiation) system (Cordis, Miami, FL).

Patients with recent acute myocardial infarction, poor left ventricular systolic function, presence of thrombus, or a coronary artery diameter narrower than 2.75 mm are not considered candidates for intracoronary radiotherapy.

The procedure

After completion of balloon angioplasty, intracoronary ultrasound is used to assess the diameter of the target vessel and the dose regimen for radiation therapy. Then a radiation catheter is tracked over a guidewire to the target lesion. For gamma-radiation, all catheterization personnel are cleared from the room

Intracoronary radiotherapy prevents recurrence of in-stent restenosis: Trial results

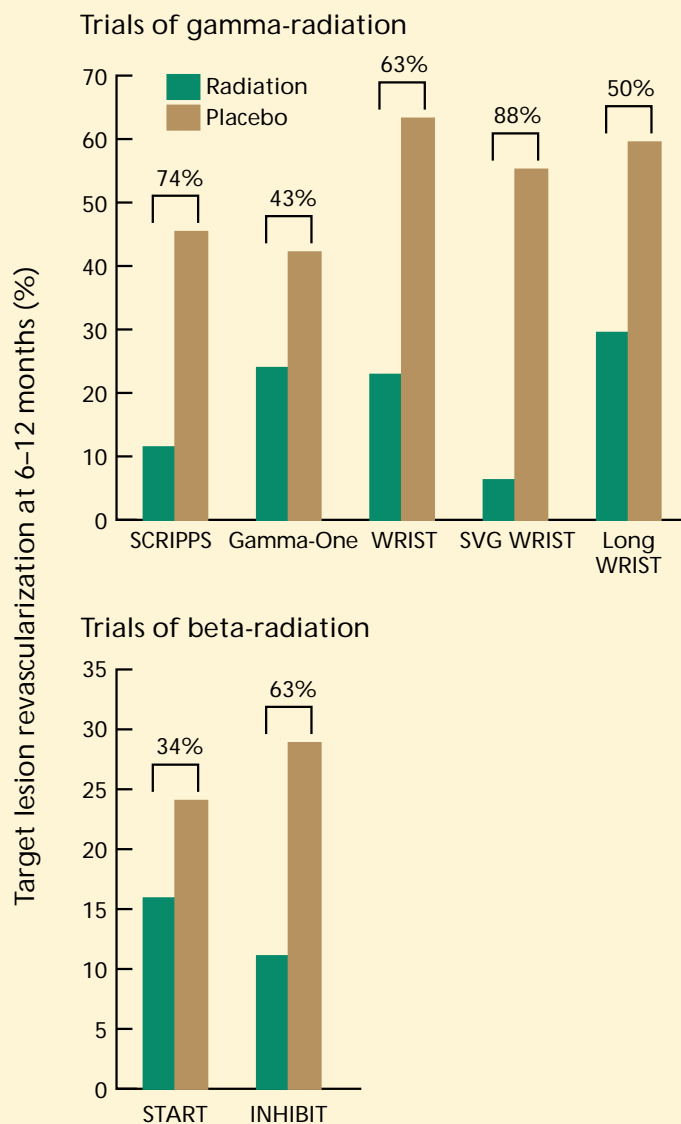
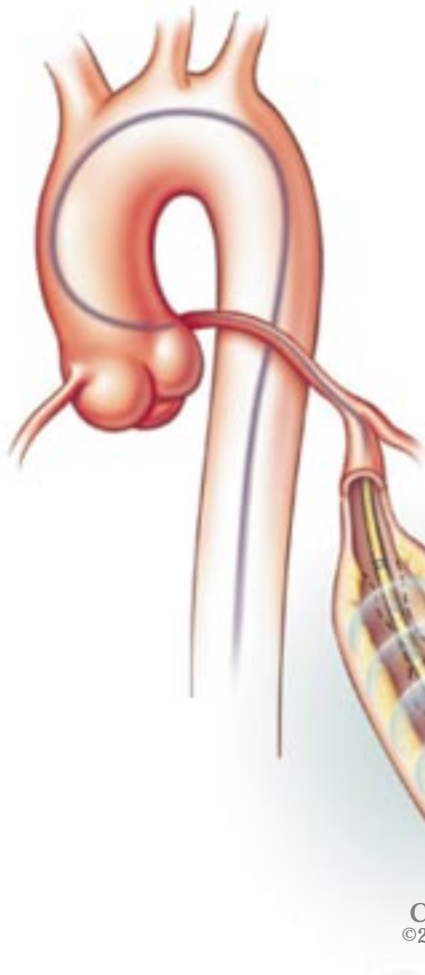


FIGURE 1. Cumulative incidence of target lesion revascularization required after intracoronary radiotherapy using gamma-radiation (top) and beta-radiation (bottom). Percentages indicate percent reduction with therapy; all differences were statistically significant.

and appropriate protective shields are put in place. A radiation oncologist inserts a ribbon that contains a predetermined dose of iridium-192 into the delivery catheter, which covers

Intracoronary radiotherapy for in-stent restenosis



In intracoronary radiotherapy using gamma-radiation, the patient undergoes balloon angioplasty. Then a radiation catheter is tracked over a guidewire to the target lesion. A radiation oncologist inserts a ribbon with a predetermined dose of iridium-192 into the delivery catheter, to cover the target lesion. The ribbon is left in place for an average of 12 to 20 minutes ("dwell time"), depending on the vessel diameter. The angiograms below show the area of restenosis (arrows) before, during, and after gamma-radiation therapy.

In beta-radiation therapy (not shown), a radioactive source wire is advanced to the target lesion and is centered using a balloon.

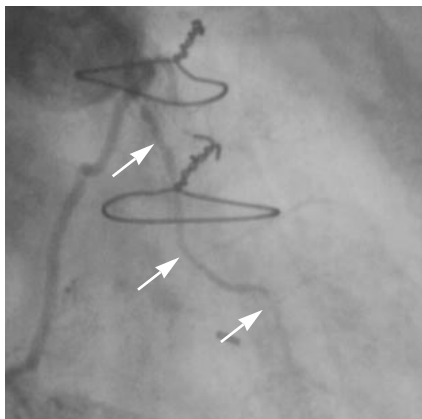
In-stent restenosis (dotted line) treated with balloon angioplasty before radiotherapy (stent omitted to show other details)

Ribbon

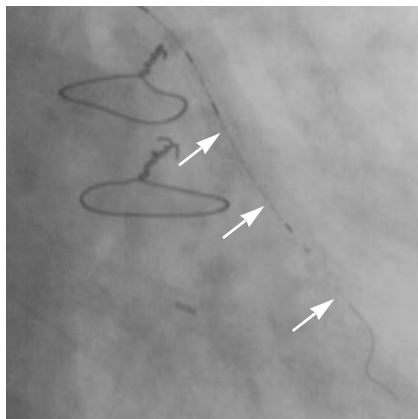
Radioactive "seeds" of iridium-192 (for gamma-radiation)

Guidewire

Before radiotherapy



During radiotherapy



After radiotherapy

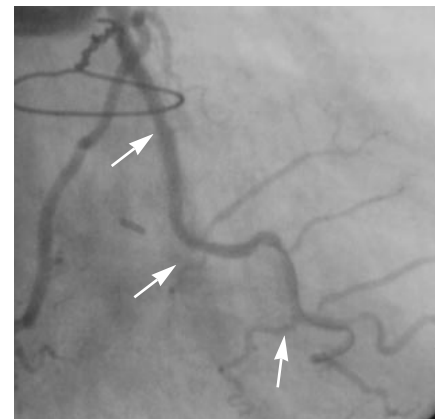


FIGURE 2

**TABLE 3****Pros and cons of gamma-radiation and beta-radiation for intracoronary radiotherapy of in-stent restenosis**

	GAMMA-RADIATION	BETA-RADIATION
Advantages	Stable radiation seed placement without constant fluoroscopic confirmation during dwell time Smaller catheter diameter	Less tissue penetration Less unneeded radiation to patient and health care workers Shorter catheter dwell time and thus less risk from ischemia Can be used with radioactive stent technology
Disadvantages	Deep tissue penetration Long catheter dwell time, means a longer ischemic time Need to clear the laboratory during dwell time Extensive shielding required Radiation oncologist must be present	Radiation oncologist must be present Intermittent fluoroscopy required during radiation delivery to ensure correct positioning of radiation seeds, and hence, more radiation exposure for the operators

the target lesion (FIGURE 2) plus 3 to 5 mm beyond each end. The ribbon is left in place for an average of 12 to 20 minutes (“dwell time”), depending on the vessel diameter.

In beta-radiation therapy, a radioactive source wire is delivered into a closed (“end-lumen”) catheter with the aid of a centering balloon and is advanced to the target. The object is to deliver a target dose of radiation within a certain distance (typically 2 mm) from the balloon-centered source wire. The average dwell time required is 3 to 5 minutes.

■ UNRESOLVED ISSUES**Gamma-radiation or beta-radiation?**

Beta-radiation is less penetrating and, therefore, laboratory personnel do not need to leave the room (TABLE 3). Beta-radiotherapy requires less dwell time and, hence, shorter ischemic time compared with gamma-radiotherapy (3 to 5 minutes vs 12 to 20 minutes). However, the current beta-radiation system is limited by its larger catheter diameter and by its ability to treat only shorter target segments compared with the gamma-radiation system.

Observational studies suggest that beta-radiation and gamma-radiation have similar efficacy in the reduction of restenosis.^{20,23} Guiding radiation delivery with intravascular ultrasound may improve the uniformity of radiation delivery within the arterial lumen.²⁴ Further studies are needed to better define the

dosimetry and the role of each catheter system in the treatment of in-stent restenosis. Head-to-head trials comparing the efficacy of beta-radiation vs gamma-radiation for in-stent restenosis are underway in Europe.

A treatment, not a cure: recurrence of restenosis

Although intracoronary radiotherapy can attenuate restenosis, it does not cure the disease. The 3-year follow-up in the SCRIPPS trial showed that loss of luminal diameter occurred between 6 months and 3 years after intracoronary radiotherapy,²⁵ suggesting that this treatment simply delays, rather than cures, restenosis.

Are there late complications due to radiation?**Mitotic and aneurysmal changes.**

Although not yet reported in any clinical trials, mitotic changes (carcinoma) or aneurysmal changes in coronary arteries are a theoretically possible late sequela of intracoronary radiotherapy, and the observation of these findings may require many years of follow-up.

Late thrombosis and myocardial infarction observed several months after intracoronary radiotherapy raised concerns about the safety of radiation.²⁶ After intracoronary radiation, endothelial repair is delayed due to the same inhibiting effect of radiation on tissue proliferation and migration. Late thrombosis is

Trials of beta-radiation vs gamma-radiation are underway

thought to be due to delayed re-endothelialization of stents, or to late positive arterial remodeling causing separation of the stent from the arterial wall. In the clinical trials,^{13–15,21,22} radiotherapy reduced the need for target lesion revascularization—but not the rates of myocardial infarction or death. In fact, Gamma-One, the largest trial of gamma-radiotherapy for in-stent restenosis,¹⁵ showed a trend of increased death (3.1% vs 0.8%, $P = .17$) and myocardial infarction (4.6% vs 2.5%, $P = .09$) in the iridium-192 group vs the placebo group at 9 months. In the pooled analysis of the brachytherapy trials,²⁶ late thrombosis was reported in 9.1% of the radiotherapy group vs 1.2% of the placebo group ($P < .0001$) at a median of 5 months; acute myocardial infarction was reported in 43% of these patients. By multivariate logistic regression analysis, new stent implantation and long lesions were found to be the major predictors of late thrombosis.

The Plavix WRIST registry reported the efficacy of a 6-month course of clopidogrel (Plavix) and aspirin in preventing subacute thrombosis after iridium-192 radiotherapy.²⁷ In beta-radiotherapy trials, prolonged clopidogrel and aspirin therapy (3 to 6 months) was associated with a low incidence of late thrombosis (0% to 2% reported at 6 to 8 months of angiographic follow-up).^{21,22}

Should we use intracoronary radiotherapy at the time of original stent placement?


Neither current catheter delivery system is approved for the primary prevention of restenosis, ie, use at the time of angioplasty of de novo lesions. Although some studies have demonstrated the efficacy of this therapeutic

option,^{17–19} uncertainty about the long-term effects of radiation limits its broader application at this time.

■ FUTURE TREATMENT OPTIONS FOR IN-STENT RESTENOSIS

Parallel to the development of catheter-based intracoronary radiotherapy has been the investigation of beta-radioactive stents—ie, stents coated with phosphorus-32.^{28,29} A potential advantage of radioactive stents that emit beta-radiation is that they do not require a radiation oncologist or additional shielding in the catheterization laboratory.

Although radioactive stents essentially eliminate in-stent restenosis, stent-edge hyperplasia due to a stimulating effect of low-dose radiation (“geographic miss”) and to balloon injury is a major limitation of this technique.³⁰ Further research should focus on improving stent dose, distribution, isotope, and stent design (eg, square-shouldered balloons, cold-end stents).³⁰ A balloon catheter filled with beta-emitting rhenium-188 has been shown as feasible in pilot studies.^{24,31–35}

Given that neointimal hyperplasia constitutes the major mechanism for in-stent restenosis, antiproliferative drugs such as sirolimus (Rapamycin), paclitaxel (Taxol), and tranilast are plausible options for this “disease.” Drug-eluting stents may enhance local delivery of these drugs and are undergoing phase III trials to explore their efficacy in eliminating in-stent restenosis. If drug-eluting stents prove effective in inhibiting neointimal hyperplasia, a revision of the indications for intracoronary radiotherapy may be necessary. 

Stents that elute antiproliferative drugs are being tested

■ REFERENCES

1. Fischman DL, Leon MB, Baim DS, et al. A randomized comparison of coronary-stent placement and balloon angioplasty in the treatment of coronary artery disease. Stent Restenosis Study Investigators. *N Engl J Med* 1994; 331:496–501.
2. Serruys PW, de Jaegere P, Kiemeneij F, et al. A comparison of balloon-expandable-stent implantation with balloon angioplasty in patients with coronary artery disease. Benestent Study Group. *N Engl J Med* 1994; 331:489–495.
3. Serruys PW, van Hout B, Bonnier H, et al. Randomised comparison of implantation of heparin-coated stents with balloon angioplasty in selected patients with coronary artery disease (Benestent II). *Lancet* 1998; 352:673–681.
4. Lincoff AM, Califf RM, Moliterno DJ, et al. Complementary clinical benefits of coronary-artery stenting and blockade of platelet glycoprotein IIb/IIIa receptors. Evaluation of Platelet IIb/IIIa Inhibition in Stenting Investigators. *N Engl J Med* 1999; 341:319–327.
5. American Heart Association. 2000 Heart and stroke statistical update: medical procedures, facilities and costs. Available at URL: www.americanheart.org/statistics/medical.html. Last accessed June 13, 2001.
6. Mintz G, Popma JJ, Pichard AD, et al. Arterial remodelling after coronary angioplasty: a serial intravascular ultrasound study. *Circulation* 1996; 94:35–43.
7. Post MJ, de Smet BJ, van der Helm Y, et al. Arterial remodeling after balloon angioplasty or stenting in an atherosclerotic experimental model. *Circulation* 1997; 96:996–1003.



8. Mintz GS, Popma JJ, Hong MK, et al. Intravascular ultrasound to discern device-specific effects and mechanisms of restenosis. *Am J Cardiol* 1996; 78:18–22.
 9. Macander PJ, Roubin GS, Agrawal SK, Cannon AD, Dean LS, Bazley WA. Balloon angioplasty for the treatment of in-stent restenosis: feasibility of, safety, and efficacy. *Cathet Cardiovasc Diagn* 1994; 32:125–131.
 10. Eltchaninoff H, Koning R, Tron C, Gupta V, Cribier A. Balloon angioplasty for the treatment of coronary in-stent restenosis: immediate results and 6-month angiographic recurrent restenosis rate. *J Am Coll Cardiol* 1998; 32:980–984.
 11. Bossi I, Klersy C, Black AJ, et al. In-stent restenosis: long-term outcome and predictors of subsequent target lesion revascularization after repeat balloon angioplasty. *J Am Coll Cardiol* 2000; 35:1569–1576.
 12. Mehran R, Dangas G, Mintz GS, et al. Treatment of in-stent restenosis with excimer laser coronary angioplasty versus rotational atherectomy: comparative mechanisms and results. *Circulation* 2000; 101:2484–2489.
 13. Teirstein PS, Massullo V, Jani S, et al. Catheter-based radiotherapy to inhibit restenosis after coronary stenting. *N Engl J Med* 1997; 336:1697–1703.
 14. Waksman R, White RL, Chan RC, et al. Intracoronary gamma-radiation therapy after angioplasty inhibits recurrence in patients with in-stent restenosis. *Circulation* 2000; 101:2165–2171.
 15. Leon MB, Teirstein PS, Moses J, et al. Localized intracoronary gamma-radiation therapy to inhibit the recurrence of restenosis after stenting. *N Engl J Med* 2001; 344:250–256.
 16. Waksman R. Intracoronary gamma radiation for diffuse in-stent restenosis: a two-center randomized clinical study—The Washington Radiation for In-Stent Restenosis Trial for Long Lesions (Long WRIST), presented at the annual scientific session of the American College of Cardiology in 2000, Houston, TX.
 17. King SB 3rd, Williams DO, Chougule P, et al. Endovascular beta-radiation to reduce restenosis after coronary balloon angioplasty: results of the beta energy restenosis trial (BERT). *Circulation* 1998; 97:2025–2030.
 18. Raizner AE, Oesterle SN, Waksman R, et al. Inhibition of restenosis with b-emitting radiotherapy. Report of the proliferation reduction with vascular energy trial (PREVENT). *Circulation* 2000; 102:951–958.
 19. Verin V, Popowski Y, de Bruyne B, et al. Endoluminal beta-radiation therapy for the prevention of coronary restenosis after balloon angioplasty. *N Engl J Med* 2001; 344:243–249.
 20. Waksman R, Bhargava B, White L, et al. Intracoronary beta-radiation therapy inhibits recurrence of in-stent restenosis. *Circulation* 2000; 101:1895–1898.
 21. Popma JJ. Late clinical and angiographic outcomes after use of 90Sr/90Y beta radiation for the treatment of in-stent restenosis: results from the strontium-90 treatment of angiographic restenosis (START) trial. Presented at the American College of Cardiology 49th annual scientific session, Anaheim, Calif, March 2000.
 22. Waksman R. Intimal hyperplasia inhibition with beta in-stent trial (INHIBIT). Presented at the American Heart Association 2000, New Orleans, LA.
 23. Lansky AJ, Mehran R, Desai K, et al. Impact of gamma and beta radiation vs placebo on the changing pattern of in-stent restenosis: a matched angiographic analysis [abstract]. *J Am Coll Cardiol* 2001; 37:29.
 24. Schühlen H, Eigler NL, Whiting JS, et al. Intracoronary brachytherapy for in-stent restenosis with a rhenium-188 liquid-filled balloon system. Results from the pilot phase of a randomized trial [abstract]. *J Am Coll Cardiol* 2000; 35:2.
 25. Teirstein PS, Massullo V, Jani S, et al. Three-year clinical and angiographic follow-up after intracoronary radiation: results of a randomized clinical trial. *Circulation* 2000; 101:360–365.
 26. Waksman R, Bhargava B, Mintz GS, et al. Late total occlusion after intracoronary brachytherapy for patients with in-stent restenosis. *J Am Coll Cardiol* 2000; 36:65–68.
 27. Waksman R, Ajani AE, White RL, et al. Prolonged antiplatelet therapy to prevent late thrombosis after intracoronary gamma-radiation in patients with in-stent restenosis: Washington Radiation for In-Stent Restenosis Trial plus 6 months of clopidogrel. *Circulation* 2001; 103:2332–2335.
 28. Albiero R, Adamian M, Kobayashi N, et al. Short- and intermediate-term results of (32)P radioactive beta-emitting stent implantation in patients with coronary artery disease: The Milan Dose-Response Study. *Circulation* 2000; 101:18–26.
 29. Albiero R, Colombo A. European high-activity ³²P radioactive stent experience. *J Invasive Cardiol* 2000; 12:416–21.
 30. Serruys PW, Kay IP. I like the candy, I hate the wrapper: the ³²P radioactive stent. *Circulation* 2000; 101:3–7.
 31. Makkar R, Whiting J, Li A, Hausleiter J, Robinson A, Eigler N. Intravascular brachytherapy with rhenium-188 balloon: RADIANT pilot study. *J Am Coll Cardiol* 2000; 35:2A.
 32. Reynen K, Koeckeritz U, Kropp J, Wunderlich G, Schmeisser A, Strasser RH. Safety and efficacy of vascular beta-radiation of in-stent restenosis with a rhenium-188 liquid-filled PTCA balloon system [abstract]. *J Am Coll Cardiol* 2001; 37:55.
 33. Hoeher M, Woehrle J, Wohlfrom M, et al. Intracoronary beta-irradiation with liquid rhenium-188 to prevent restenosis following coronary angioplasty. Results from the randomized ECRIS-1 trial [abstract]. *Circulation* 2000; 102 (suppl 2):750.
 34. Chae I, Kin H, Sohn D, et al. Intracoronary beta radiation therapy with ¹⁸⁸Re-DTPA-filled balloon system after angioplasty-spare (Seoul National University Hospital post-angioplasty Rhenium) trial [abstract]. *Circulation* 2000; 102 (suppl 2):751.
 35. Jepson NS, Karolis C, Milross C, et al. Intracoronary radiotherapy with liquid rhenium-188 for the treatment of in-stent restenosis—preliminary results of the power (Prince of Wales endovascular radiation) study. *Circulation* 2000; 102 (suppl 2):423.
-
ADDRESS: David J. Moliterno, MD, Department of Cardiology, F25, The Cleveland Clinic Foundation, 9500 Euclid Avenue, F25, Cleveland, OH 44195; e-mail molited@ccf.org.