

**A. THOMAS MCRAE, III, MD**

Department of Cardiology, Cleveland Clinic

MINA K. CHUNG, MDSection of Cardiac Electrophysiology,
Department of Cardiology, Cleveland Clinic**CRAIG R. ASHER, MD**Section of Cardiovascular Imaging,
Department of Cardiology, Cleveland Clinic

Arrhythmogenic right ventricular cardiomyopathy: A cause of sudden death in young people

ABSTRACT

Arrhythmogenic right ventricular cardiomyopathy (ARVC) is an increasingly recognized cause of ventricular tachycardia and sudden cardiac death in young people, notably young athletes. The best treatment is not clear, although options include antiarrhythmic drugs, radiofrequency ablation, and implantable defibrillators.

KEY POINTS

The classic presentation is of a young athlete who complains of palpitations and dizzy spells while exercising.

The prevalence of ARVC is difficult to estimate, since many cases are only recognized postmortem. In one series, ARVC accounted for only 3% of cases of sudden death in young athletes, but reports from Italy put the figure at 20%.

Electrocardiography, although not sensitive, is a useful initial test. Echocardiography is often the first test that demonstrates the characteristic abnormalities of ARVC, but a normal echocardiogram does not exclude the diagnosis.

ARVC should be suspected if a family history of ARVC is present, if the patient or a family member has had an event of unexplained ventricular tachycardia or sudden cardiac death, if unexplained symptoms of presyncope, syncope, dyspnea, palpitations, or chest pain occur in a young adult, or if noninvasive tests such as ECG, Holter monitoring, or echocardiography reveal suggestive findings.

Once the diagnosis of ARVC is made, the patient should refrain from participating in competitive sports or other intense exertional activities.

ARRHYTHMOGENIC right ventricular cardiomyopathy (ARVC) has recently been recognized as a cause of ventricular tachycardia and sudden death in young people.

Because the sudden death of a young, seemingly healthy adult is such a devastating event, much attention has been focused on the causes of sudden death in athletes, with the goal of implementing preparticipation screening programs. Although left heart cardiomyopathies such as hypertrophic cardiomyopathy, coronary anomalies, and valvular heart disease account for most of such cases in the United States (**TABLE 1**),^{1,2} ARVC is now believed to be an important cause as well.

This review highlights the major features of this enigmatic disease with specific attention to the symptoms that should lead a physician to suspect it, and the diagnostic tests used to define it.

THREE MAIN FEATURES

According to the World Health Organization/International Society and Federation of Cardiology Task Force on the Definition and Classification of Cardiomyopathies,³ ARVC, also known as arrhythmogenic right ventricular dysplasia, is distinct from the more familiar forms of cardiomyopathy (dilated, hypertrophic, and restrictive) and is characterized by three features:

- Progressive fibrofatty replacement of right ventricular myocardium
- Strong familial transmission
- Presentation with symptomatic arrhythmias or sudden death.

TABLE 1

Causes of sudden cardiac death in 134 young athletes

CAUSE	PERCENT
Hypertrophic cardiomyopathy	36
Unexplained increase in cardiac mass (possible hypertrophic cardiomyopathy)	10
Aberrant coronary arteries	13
Other coronary anomalies	6
Ruptured aortic aneurysm	5
Tunneled left anterior descending coronary artery	5
Aortic valve stenosis	4
Lesion consistent with myocarditis	3
Idiopathic dilated cardiomyopathy	3
Arrhythmogenic right ventricular cardiomyopathy (ARVD)	3
Idiopathic myocardial scarring	3
Mitral valve prolapse	2
Atherosclerotic coronary artery disease	2
Other congenital heart diseases	1.5
Long QT syndrome	0.5
Sarcoidosis	0.5
Sickle cell trait	0.5
"Normal" heart	2

ADAPTED FROM MARON BJ, SHIRANI J, POLIAC LC, MATHENGE R, ROBERTS WC, MUELLER FO. SUDDEN DEATH IN YOUNG COMPETITIVE ATHLETES. CLINICAL, DEMOGRAPHIC, AND PATHOLOGICAL PROFILES. JAMA 1996; 276:199–204.

■ PREVALENCE DIFFICULT TO ESTIMATE

The prevalence of ARVC is difficult to estimate, since many cases are only recognized postmortem. Earlier in the disease, cases are unrecognized because we lack effective screening tests and commonly accepted diagnostic criteria. Nonetheless, the disease is uncommon. Most reports of ARVC are from Europe (particularly the Veneto region of Italy) and the United States. These seemingly endemic regions may simply be areas where the disease is best understood and most often investigated.

Patients with ARVC are predominantly male, with a male-to-female ratio of 2.7 to 1 and a mean age at onset of symptoms ranging from the late 20s to early 30s. The disease almost always occurs after puberty, though it has been detected in persons of all ages.³

■ PATHOPHYSIOLOGY: A TWO-STEP PROCESS

ARVC is familial in more than 50% of patients, with the more common form being autosomal dominant. Rare recessive forms have also been characterized, particularly in a region of Greece.⁴

The disease is thought to progress in a two-step process involving first a genetic predisposition to fatty infiltration of the right ventricle and later transformation from a pure fatty infiltration to a fibrofatty form involving apoptosis or myocarditis, possibly as a result of some unknown environmental stimulus or virus.⁵

ARVC was initially thought to involve the right ventricle only, but it is now known that most cases involve both ventricles.^{6,7} The disease progresses as right and left ventricular function deteriorate over time. In its end stage, ARVC is clinically indistinguishable from dilated cardiomyopathy, and many patients thought to have idiopathic dilated cardiomyopathy are discovered at autopsy to have had ARVC.⁶

■ CLINICAL MANIFESTATIONS

Asymptomatic ARVC is uncommonly recognized unless a physician is alerted to a family history of the disease. Furthermore, most athletic screening programs cannot detect the disease by a routine history and physical examination. ARVC may be suspected on the basis of electrocardiographic (ECG) findings, though this requires that the clinician be alert to often subtle or sometimes nonspecific patterns.

Therefore, patients with ARVC generally present as young adults with symptoms on initial presentation that include presyncope, syncope, palpitations, premature ventricular contractions (PVCs), ventricular arrhythmias, right or left heart failure, and sudden cardiac



TABLE 2

Diagnostic criteria for arrhythmogenic right ventricular cardiomyopathy

Family history

Major criterion: Familial disease confirmed at necroscopy or surgery

Minor criteria: Family history of premature sudden death (< 35 years of age) due to suspected arrhythmogenic right ventricular cardiomyopathy

Family history of arrhythmogenic right ventricular cardiomyopathy (clinical diagnosis based on present criteria)

Electrocardiographic depolarization or conduction abnormalities

Major criterion: Epsilon waves or localized prolongation (> 110 ms) of QRS complex in right precordial leads (V_1 – V_3)

Minor criterion: Late potentials on signal-averaged ECG

Electrocardiographic repolarization abnormalities

Minor criterion: Inverted T waves in right precordial leads (V_2 and V_3) in people older than 12 years and in absence of right bundle-branch block

Arrhythmias

Minor criteria: Sustained or nonsustained left bundle branch block-type ventricular tachycardia documented on ECG or Holter monitoring or during exercise testing

Frequent ventricular extrasystoles (> 1,000/24 hours) on Holter monitoring)

Global or regional dysfunction and structural alterations

(detected by echocardiography, angiography, magnetic resonance imaging, or radionuclide scintigraphy)

Major criteria: Severe dilation and reduction of right ventricular ejection fraction with no or mild left ventricular involvement

Localized right ventricular aneurysms (akinetic or dyskinetic areas with diastolic bulging)

Severe segmental dilation of right ventricle

Minor criteria: Mild global right ventricular dilation or ejection fraction reduction with normal left ventricle

Mild segmental dilation of right ventricle

Regional right ventricular hypokinesia

Tissue characteristics of walls

Major criteria: Fibrofatty replacement of myocardium on endomyocardial biopsy

The diagnosis is made with 2 major criteria or 1 major plus 2 minor criteria or 4 minor criteria.

ADAPTED FROM MCKENNA WJ, THIENE G, NAVA A, ET AL. DIAGNOSIS OF ARRHYTHMOGENIC RIGHT VENTRICULAR DYSPLASIA/CARDIOMYOPATHY. TASK FORCE OF THE WORKING GROUP MYOCARDIAL AND PERICARDIAL DISEASE OF THE EUROPEAN SOCIETY OF CARDIOLOGY AND OF THE SCIENTIFIC COUNCIL ON CARDIOMYOPATHIES OF THE INTERNATIONAL SOCIETY AND FEDERATION OF CARDIOLOGY. BR HEART J 1994; 71:215–218.

**Often,
sudden
death is
the first
sign of ARVC**

arrest. Often, sudden cardiac arrest is the first manifestation of ARVC among persons participating in sports or strenuous activity. This is best documented in Italy, where ARVC accounts for 20% of all sudden cardiac deaths in people younger than 35 years.^{8,9}

The McKenna criteria are the most widely accepted criteria for the diagnosis of ARVC.¹⁰ The Arrhythmogenic Right Ventricular

Dysplasia/Cardiomyopathy Working Group recently revised the McKenna criteria to include family history and findings on ECG, Holter monitoring, echocardiography, right ventricular imaging, and biopsy (TABLE 2).¹¹ Newer diagnostic tests that postdate the McKenna criteria include computed tomography, magnetic resonance imaging (MRI), neurohormonal markers, and genetic probes. We

Ventricular tachycardia in arrhythmogenic right ventricular cardiomyopathy (ARVC)

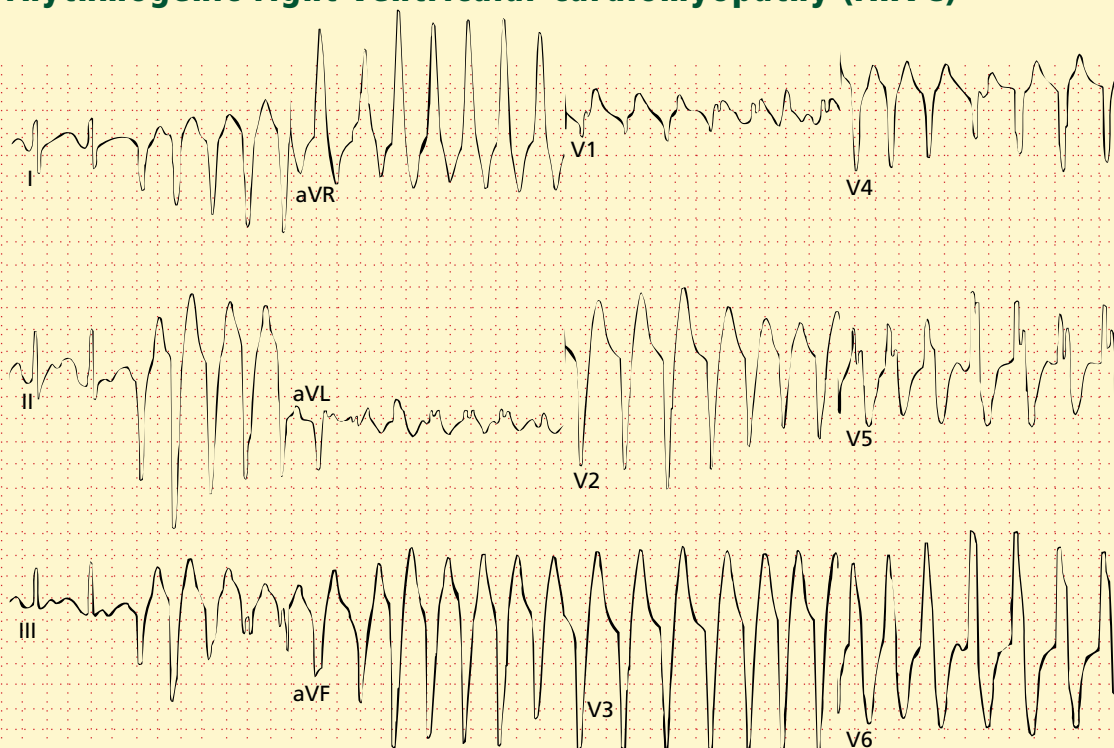

FIGURE 1. Twelve-lead electrocardiogram of a patient with ARVC showing left bundle-branch block ventricular tachycardia.

will review all of the currently available tests and integrate their use into the established framework.

WHOM TO SUSPECT OF HAVING ARVC

ARVC should be suspected if:

- A family history of ARVC is present (for these individuals, screening should include an ECG, echocardiogram, and Holter monitoring)
- The patient or a family member has had an event of unexplained ventricular tachycardia or resuscitated cardiac arrest or sudden cardiac death
- Unexplained symptoms of presyncope, syncope, dyspnea, palpitations, or chest pain occur in a young adult
- Noninvasive tests such as ECG, Holter

monitoring, or echocardiography reveal suggestive findings described below.

The classic presentation is of a young athlete who complains of palpitations and dizzy spells while exercising. An ECG is obtained and shows precordial T-wave inversions, incomplete right bundle branch abnormality, and left bundle branch morphology PVCs or left bundle branch block morphology ventricular tachycardia with a superior QRS axis. An echocardiogram demonstrates mild right ventricular enlargement and dysfunction with no other explanation. Such a patient should be referred to an electrophysiologist for further testing and treatment.

If clinical suspicion is high and initial diagnostic tests are equivocal, then one should proceed with MRI or electron-beam (“ultra-fast”) CT.

■ DIAGNOSTIC TESTS

Electrocardiography

ECG is a useful initial diagnostic test for assessing a patient with suspected ARVC, though a normal ECG does not exclude the disease. In his initial report, Marcus described the most frequent ECG abnormalities, which include:

- T-wave inversions in the precordial chest leads (V_1 through V_4 ; **FIGURE 1**)
- Conduction delays through the right ventricle (incomplete or complete right bundle-branch block)
- PVCs with left bundle-branch block and superior axis deviation
- Ventricular post-excitation waves (epsilon waves; **FIGURE 2**).¹²

If nonsustained or sustained ventricular tachycardia or frequent PVCs are present in ARVC, they usually have left bundle-branch morphology. They can be distinguished from right ventricular outflow tract PVCs or ventricular tachycardia, which have left bundle-branch, inferior-axis morphology and which in the absence of other evidence for ARVC are generally benign.

The overall accuracy of ECG findings for diagnosing ARVC has not been established. Many young adults have T-wave changes in the precordial leads (“juvenile T waves”), and conduction abnormalities are nonspecific. Only the infrequently encountered epsilon waves are highly suggestive of the disorder.

For patients with ECG findings that suggest ARVC, a signal-averaged ECG can be performed. This test has a reported sensitivity of 57%, a specificity of 95%, and a positive predictive value of 92% for the detection of abnormal late potentials that are the substrate for ventricular tachycardia. The more extensive the disease, the greater the likelihood that the signal-averaged ECG will detect it.¹³

Echocardiography

An echocardiogram is an integral part of the diagnostic evaluation of patients with syncope, arrhythmias, and cardiac arrest. Structural heart disease may be diagnosed echocardiographically in most patients with

Epsilon waves: Highly specific for ARVC

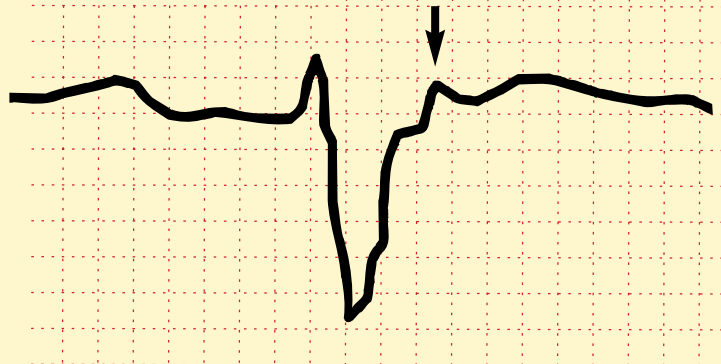


FIGURE 2. Repolarization (“epsilon”) wave in lead V_1 (arrow), which is highly specific for arrhythmogenic right ventricular cardiomyopathy.

COURTESY OF ANDREA NATALE, MD, DEPARTMENT OF CARDIOLOGY, CLEVELAND CLINIC FOUNDATION

these presenting symptoms. The value of echocardiography for patients with palpitations and no documented arrhythmias is less certain.

Echocardiographic evaluation of a patient with suspected ARVC should focus on assessing regional or global enlargement or dysfunction of the right ventricle. The three most frequent sites of dysplasia (the “triangle of dysplasia”) are the outflow tract, the apex, and the inflow portion of the right ventricle (**FIGURE 3**).¹² Specific findings in these areas include diastolic outpouchings and systolic aneurysms (**FIGURE 4**).

In a patient with suspected ARVC, echocardiographic evidence of diffuse right ventricular enlargement strongly supports the diagnosis.¹⁴ However, other causes of right ventricular disorders such as congenital, myocardial, or valvular diseases or shunts should be sought before the diagnosis of ARVC is made.¹⁵ Echocardiography is often the first test that demonstrates the characteristic abnormalities of ARVC, though its accuracy is variably reported and it is best used in patients with a high likelihood of disease.¹⁶ A normal echocardiogram does not exclude the diagnosis of ARVC, since early forms of the disease may not be apparent.

The ECG is a useful initial test, but does not rule out ARVC

The 'triangle of dysplasia' in ARVC

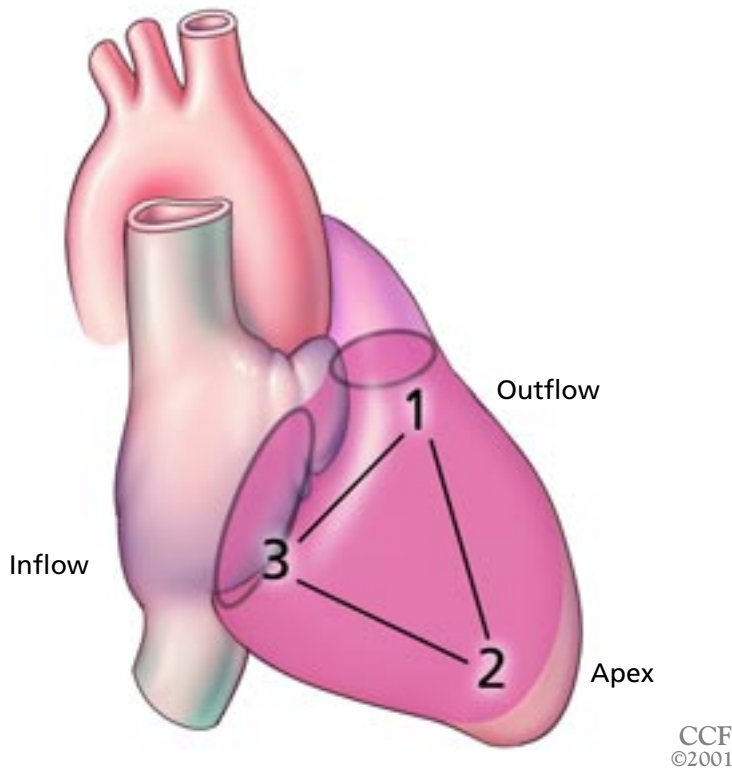


FIGURE 3. The three most frequent sites of dysplasia, "the triangle of dysplasia," in arrhythmogenic right ventricular cardiomyopathy (ARVC) as described by Marcus et al¹² are the outflow tract, apex, and inflow segments of the right ventricle.

ADAPTED FROM WITH PERMISSION FROM MARCUS FI, FONTAINE GH, GUIRAUDON G, ET AL. RIGHT VENTRICULAR DYSPLASIA: A REPORT OF 24 ADULT CASES. CIRCULATION 1982; 65:384-398.

Radionuclide cardiac studies

Radionuclide cardiac studies have been validated as a noninvasive alternative to right ventriculography and echocardiography.¹⁷ In some patients, the right ventricle's anterior location and irregular shape make it difficult to evaluate by echocardiography. In these patients, radionuclide scans are useful in measuring right ventricular size and function. Some investigators used radionuclide studies to assess right ventricular wall motion during exercise, with right ventricular dysfunction during stress suggesting the diagnosis of ARVC.

Magnetic resonance imaging and electron-beam computed tomography

Though expensive, time-consuming, and limited to specialized centers, MRI is consid-

ered by many to be the definitive noninvasive test for ARVC. In patients with suspected ARVC, MRI can detect fatty infiltration or thinning of the infundibulum and the diaphragmatic free wall of the right ventricle. The pathognomonic distribution of fatty infiltration is in the RV free wall, where MRI shows a high signal intensity diffusely present (FIGURE 5).¹⁸ The location of a high-intensity fat signal must be contrasted with the normal distribution of fat in the human heart, most notably in the atrio-ventricular groove. MRI can also be used to correlate the morphologic findings of wall thinning or outpouchings with dyskinetic RV segments on gradient-echo pulse sequences.¹⁹

Some centers prefer electron-beam computed tomography as an alternative to MRI. Like MRI, electron-beam computed tomography detects ARVC by the presence of epicardial adipose tissue, low-attenuation trabeculations, scalloping of the right ventricular free wall, and intramyocardial fat deposits. It can also be used to find fatty replacement of left ventricular myocardium.^{20,21}

Right ventricular angiography

Before echocardiography was commonly used, right ventriculography was frequently used as a reliable test for localized abnormalities such as sacculations, dilation, and dysfunction of the right ventricle. Since then, however, echocardiography has proved to be equivalent in terms of image quality and is less invasive, cheaper, more readily available, and simpler to perform.²²

Endomyocardial biopsy

The gold standard for diagnosing ARVC is a transmural biopsy specimen obtained at autopsy or during heart transplantation.

Endomyocardial biopsies are less sensitive but can be obtained in living, nontransplant patients with suspected ARVC. However, a paradox exists in that the process of fibrofatty replacement of the myocardium occurs preferentially in the right ventricular free wall, but endomyocardial biopsies are traditionally obtained from the right ventricular portion of the interventricular septum. Biopsy of the right ventricular free wall is considered risky with the potential for perforation and tam-

ponade, particularly in the thinned, fibrofatty right ventricular free wall of a patient with ARVC. Only small studies have validated biopsy of the right ventricular septum as a diagnostic tool in patients with suspected ARVC.²³ If the biopsy of the right ventricular septum reveals fibrofatty replacement of the right ventricle, then the diagnosis of ARVC is secured. If the biopsy is normal, however, the specimen could be falsely negative.

Under proposed criteria for histomorphometric evaluation of biopsy specimens, the diagnosis of ARVC requires that there be fewer than 45% residual myocytes, more than 40% fibrous tissue, and more than 3% fatty tissue. These criteria have a sensitivity of 67% and a specificity of 92%.²⁴

Brain natriuretic peptide

Future tests for ARVC may include direct genetic probes. Until then, measurement of proteins released in response to ARVC offers useful diagnostic and prognostic information. Plasma levels of brain natriuretic peptide were used in a small study to distinguish between ARVC and another form of idiopathic right ventricular outflow-tract tachycardia.²⁵ In addition, plasma levels of the peptide were found to be inversely related to the right ventricular ejection fraction, providing a potential method by which progression of the disease could be monitored.

■ TREATMENT IS CONTROVERSIAL

The optimal treatment of ARVC is controversial. Options are many and include antiarrhythmic drugs with serial electrophysiology studies, radiofrequency ablation, implantable cardioverter-defibrillator (ICD) placement, surgical disarticulation, and heart transplantation. Once the diagnosis of ARVC is made, the patient should refrain from participating in competitive sports or other intense exertional activities.

Drug therapy. The largest study (81 patients)²⁶ of drug therapy in ARVC found sotalol to be the most effective medication, with a success rate of 68% as determined by the inability to reproduce sustained ventricular tachycardia during serial electrophysiology studies. Amiodarone was successful in only

Outpouching of the left ventricle in ARVC

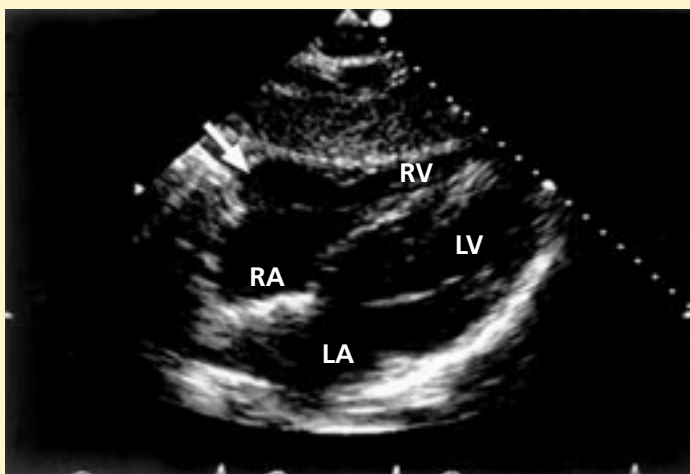


FIGURE 4. Echocardiogram, subcostal view, demonstrating an outpouching (arrow) at the base of the right ventricle suggestive of arrhythmogenic right ventricular cardiomyopathy (ARVC). RA right atrium, RV right ventricle, LA left atrium, LV left ventricle.

FROM ASHER C, LEVER H. ECHOCARDIOGRAPHIC PROFILES OF DISEASES ASSOCIATED WITH SUDDEN CARDIAC DEATH IN YOUNG ATHLETES. IN: WILLIAMS RA, EDITOR. THE ATHLETE AND HEART DISEASE: DIAGNOSIS, EVALUATION AND MANAGEMENT. PHILADELPHIA: LIPPINCOTT WILLIAMS AND WILKINS, 1999:155-172.

15% of cases, and class I agents were universally unsuccessful. The investigators concluded that if sotalol therapy failed, more invasive treatments should be considered.

Radiofrequency catheter ablation is effective for some patients with ventricular tachycardia refractory to antiarrhythmic therapy.²⁷⁻²⁹

Implantable cardioverter-defibrillators. Since the disease may be progressive, ablation may not be curative and many specialists recommend an ICD once the diagnosis is made. A patient who has been resuscitated from cardiac arrest can be treated with antitachycardia pacing or defibrillation. ICD therapy does not obviate the need for adjunct drug treatment to decrease the number of shocks delivered. Initially there were concerns about placing transvenous leads into the endocardium of the diseased right ventricle of a patient with ARVC and uncertainty about the ability of the device to correctly sense and deliver shocks. Small studies, however, have since

MRI appearance of fatty infiltration in ARVC

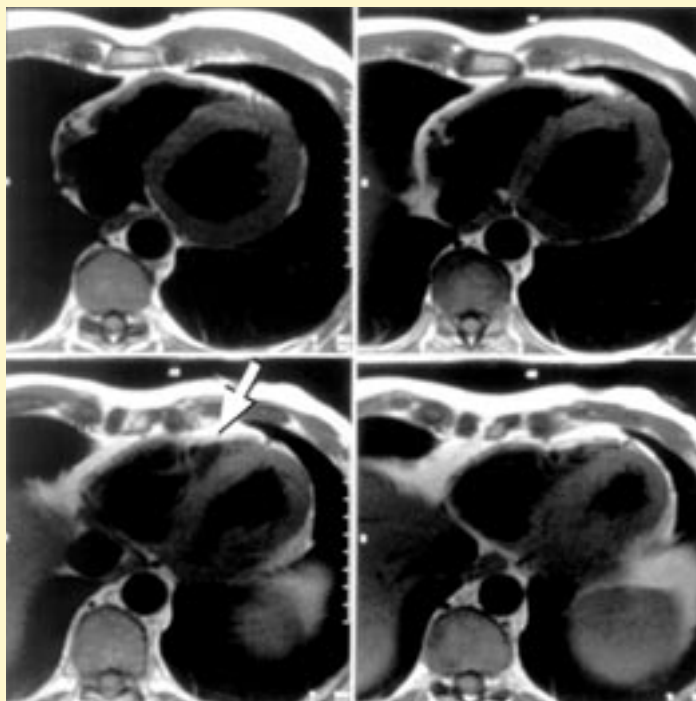


FIGURE 5. Magnetic resonance image (MRI) showing the fibrofatty distribution involving the right ventricle consistent with arrhythmogenic right ventricular cardiomyopathy (ARVC). Arrow points to fatty infiltration.

COURTESY OF RICHARD D. WHITE, MD, DEPARTMENT OF RADIOLOGY,
CLEVELAND CLINIC FOUNDATION


confirmed that transvenous endocardial lead placement is safe and that effective therapy can be delivered.²⁹

Surgical therapy, though no longer contemporary practice, involves disarticulation of the right ventricle, which separates it from the left ventricle and prevents it from propagating the arrhythmia to the left ventricle.

Cardiac transplantation is ultimately an option if the patient has progressive biventricular failure with increasing amounts of ventricular tachycardia.

REFERENCES

1. Maron BJ, Epstein SE, Roberts WC. Causes of sudden death in competitive athletes. *J Am Coll Cardiol* 1986; 7:204–214.
2. Maron BJ, Shirani J, Poliac LC, Mathenge R, Roberts WC, Mueller FO. Sudden death in young competitive athletes. Clinical, demographic, and pathological profiles. *JAMA* 1996; 276:199–204.
3. Richardson P, McKenna W, Bristow M, et al. Report of the 1995 World Health Organization/International Society and Federation of Cardiology Task Force on the Definition and Classification of Cardiomyopathies. *Circulation* 1996; 93:841–842.
4. Rampazzo A, Nava A, Danieli GA, et al. The gene for arrhythmogenic right ventricular cardiomyopathy maps to chromosome 14q23-q24. *Hum Mol Genet* 1994; 3:959–962.
5. Fontaine G, Fontaliran F, Frank R. Arrhythmogenic right ventricular cardiomyopathies: clinical forms and main differential diagnoses [editorial; comment]. *Circulation* 1998; 97:1532–1535.
6. Nemec J, Edwards BS, Osborn MJ, Edwards WD. Arrhythmogenic right ventricular dysplasia masquerading as dilated cardiomyopathy. *Am J Cardiol* 1999; 84:237–239.
7. Thiene G, Nava A, Corrado D, Rossi L, Pennelli N. Right ventricular cardiomyopathy and sudden death in young people. *N Engl J Med* 1988; 318:129–133.
8. Corrado D, Basso C, Thiene G, et al. Spectrum of clinicopathologic manifestations of arrhythmogenic right ventricular cardiomyopathy/dysplasia: a multicenter study. *J Am Coll Cardiol* 1997; 30:1512–1520.
9. Pinamonti B, Sinagra G, Salvi A, et al. Left ventricular involvement in right ventricular dysplasia. *Am Heart J* 1992; 123:711–724.
10. McKenna WJ, Thiene G, Nava A, et al. Diagnosis of arrhythmogenic right ventricular dysplasia/cardiomyopathy. Task Force of the Working Group Myocardial and Pericardial Disease of the European Society of Cardiology and of the Scientific Council on Cardiomyopathies of the International Society and Federation of Cardiology. *Br Heart J* 1994; 71:215–218.
11. Corrado D, Fontaine G, Marcus FI, et al. Arrhythmogenic right ventricular dysplasia/cardiomyopathy: need for an international registry. Study Group on Arrhythmogenic Right Ventricular Dysplasia/Cardiomyopathy of the Working Groups on Myocardial and Pericardial Disease and Arrhythmias of the European Society of Cardiology and of the Scientific Council on Cardiomyopathies of the World Heart Federation. *Circulation* 2000; 101:E101–E106.
12. Marcus FI, Fontaine GH, Guiraudon G, et al. Right ventricular dysplasia: a report of 24 adult cases. *Circulation* 1982; 65:384–398.
13. Nava A, Folino AF, Bauce B, et al. Signal-averaged electrocardiogram in patients with arrhythmogenic right ventricular cardiomyopathy and ventricular arrhythmias. *Eur Heart J* 2000; 21:58–65.
14. Kisslo J. Two-dimensional echocardiography in arrhythmogenic right ventricular dysplasia. *Eur Heart J* 1989; 10 Suppl D:22–26.
15. Asher C, Lever H. Echocardiographic profiles of diseases associated with sudden cardiac death in young athletes. In: Williams RA, editor. *The Athlete and Heart Disease: Diagnosis, Evaluation and Management*. Philadelphia: Lippincott Williams and Wilkins, 1999:155–172.
16. Alizad A, Seward JB. Echocardiographic features of genetic diseases: part 1. Cardiomyopathy. *J Am Soc Echocardiogr* 2000; 13:73–86.
17. Manyari DE, Duff HJ, Kostuk WJ, et al. Usefulness of non-invasive studies for diagnosis of right ventricular dysplasia. *Am J Cardiol* 1986; 57:1147–1153.
18. Blake LM, Scheinman MM, Higgins CB. MR features of arrhythmogenic right ventricular dysplasia. *AJR Am J Roentgenol* 1994; 162:809–812.
19. Ricci C, Longo R, Pagnan L, et al. Magnetic resonance imaging in right ventricular dysplasia. *Am J Cardiol* 1992; 70:1589–1595.

- 
20. Tada H, Shimizu W, Ohe T, et al. Usefulness of electron-beam computed tomography in arrhythmogenic right ventricular dysplasia. Relationship to electrophysiological abnormalities and left ventricular involvement. *Circulation* 1996; 94:437–444.
 21. Hamada S, Takamiya M, Ohe T, Ueda H. Arrhythmogenic right ventricular dysplasia: evaluation with electron-beam CT. *Radiology* 1993; 187:723–727.
 22. Robertson JH, Bardy GH, German LD, Gallagher JJ, Kisslo J. Comparison of two-dimensional echocardiographic and angiographic findings in arrhythmogenic right ventricular dysplasia. *Am J Cardiol* 1985; 55:1506–1508.
 23. Peters S, Davies MJ, McKenna WJ. Diagnostic value of endomyocardial biopsies of the right ventricular septum in arrhythmias originating from the right ventricle. *Jpn Heart J* 1996; 37:195–202.
 24. Angelini A, Thiene G, Boffa GM, et al. Endomyocardial biopsy in right ventricular cardiomyopathy. *Int J Cardiol* 1993; 40:273–282.
 25. Matsuo K, Nishikimi T, Yutani C, et al. Diagnostic value of plasma levels of brain natriuretic peptide in arrhythmogenic right ventricular dysplasia. *Circulation* 1998; 98:2433–2440.
 26. Wichter T, Borggrefe M, Haverkamp W, Chen X, Breithardt G. Efficacy of antiarrhythmic drugs in patients with arrhythmogenic right ventricular disease. Results in patients with inducible and noninducible ventricular tachycardia. *Circulation* 1992; 86:29–37.
 27. Ellison KE, Friedman PL, Ganz LI, Stevenson WG. Entrainment mapping and radiofrequency catheter ablation of ventricular tachycardia in right ventricular dysplasia. *J Am Coll Cardiol* 1998; 32:724–728.
 28. Feld GK. Expanding indications for radiofrequency catheter ablation: ventricular tachycardia in association with right ventricular dysplasia? *J Am Coll Cardiol* 1998; 32:729–731.
 29. Link MS, Wang PJ, Haugh CJ, et al. Arrhythmogenic right ventricular dysplasia: clinical results with implantable cardioverter defibrillators. *J Interv Card Electrophysiol* 1997; 1:41–48.
-
- ADDRESS:** Craig R. Asher, MD, Department of Cardiology, F15, The Cleveland Clinic Foundation, 9500 Euclid Avenue, Cleveland, OH 44195; e-mail ashercc@ccf.org.