

**HAMED A. DAW, MD**

Department of Hematology and Oncology,
Cleveland Clinic

MAURIE MARKMAN, MD

Director, Taussig Cancer Center; chairman,
Department of Hematology and Oncology,
Cleveland Clinic; and associate editor,
Cleveland Clinic Journal of Medicine

Epidural spinal cord compression in cancer patients: Diagnosis and management

ABSTRACT

In most patients with spinal cord compression due to epidural metastasis, the initial symptom is progressive back pain with an axial or radicular distribution, but early symptoms are often nonspecific. Since the key prognostic factor is the neurologic status at the time of presentation, and since early complaints are often nonspecific, a high index of suspicion is needed to diagnose this complication early.

KEY POINTS

With prompt management, ambulatory status can be maintained in about 80% of patients, but delays result in a rapid loss of function.

Back pain tends to be localized initially and may increase with lying supine, coughing, sneezing, flexing of the neck, and moving.

Differentiating back pain of epidural spinal cord compression from that of degenerative joint disease is critical. Pain of degenerative joint disease almost always affects the low cervical or low lumbar spine, whereas pain of metastatic compression occurs at any level. Lying down improves the pain of degenerative disease but typically worsens pain due to metastatic compression.

Magnetic resonance imaging is the diagnostic test of choice for epidural spinal cord compression.

Steroids should be given to all patients suspected of having spinal cord compression.

SPINAL CORD COMPRESSION due to epidural metastasis needs to be recognized early and treated promptly, since any delay may doom the patient to a very uncomfortable demise, with pain, immobility, and incontinence. With prompt treatment, 80% of patients maintain their ability to walk. In most patients, the initial symptom is progressive back pain with an axial or radicular distribution, but early symptoms are often nonspecific. Therefore, a high index of suspicion is needed to diagnose this complication early.

PATHOPHYSIOLOGY

In cancer patients, epidural spinal cord compression is usually the result of hematogenous spread of primary tumor cells to the bone marrow of the vertebral column, where metastatic tumors grow. In time these tumors can cause cord compression, either by extending into the epidural space or by causing vertebral body collapse.¹ In addition, animal studies have demonstrated that blood flow abnormalities such as vascular congestion, edema, and hemorrhage of the spinal cord at the level of the compression also play a role. These findings could be caused either by occlusion of venous outflow from the cord,² or by occlusion of the central perforating vessels of the spinal cord.³ Animal studies have also demonstrated that neurologic deficits are more likely to reverse when compression is gradual rather than acute.⁴

Vasogenic cord edema has been correlated with increased synthesis of prostaglandin E₂, which can be inhibited by steroidal and non-



steroidal anti-inflammatory drugs, as well as by serotonin antagonists (eg, cyproheptadine).⁵ These findings may lead to new types of therapy for this condition.

■ CLINICAL PRESENTATION

Back pain

Back pain is the most common presenting symptom, occurring in 95% of patients with epidural spinal cord compression. It may precede neurologic symptoms by weeks or months.

Caused by expanding metastases stretching the periosteum, the pain:

- Can be either localized or referred, although it is usually localized initially
- May increase with lying supine, coughing, sneezing, flexing the neck, moving
- May be described as a deep, dull ache
- May awaken the patient from sleep
- May not respond to analgesics
- May include tenderness on percussion over the involved area
- May be radicular, occurring near the area of compression in a dermatomal pattern—unilaterally when the cervical or lumbar spine is involved, and bilaterally when the thoracic spine is involved.⁶

Spinal cord compression vs degenerative joint disease

Differentiating the pain of metastatic epidural spinal cord compression from the pain of degenerative joint disease is critical. Clinical clues include:

- **Location** of the pain: pain of degenerative joint disease almost always affects the low cervical or low lumbar spine, whereas pain of metastatic compression occurs at any level
- **Positional relief:** lying down improves the pain of degenerative disease but typically worsens pain due to metastatic compression.

Neurologic signs

Neurologic signs or symptoms in patients with metastatic epidural spinal cord compression usually indicate disease progression.

Motor weakness usually follows the development of pain by weeks or months. It affects proximal muscles, creating difficulty when climbing stairs or rising from a chair.

When weakness is present, hyperreflexia and an extensor plantar response confirm involvement of the corticospinal tracts.

Sensory loss may occur below the level of cord compression and corresponds to a skin dermatome. Loss of proprioception is common when the posterior spine is involved.

Signs and symptoms of autonomic dysfunction such as hesitancy, urinary retention, and urinary and fecal incontinence occur late and are particularly ominous. Although narcotic analgesics can cause urinary retention, spinal cord compression should be ruled out first in any patient at risk.

■ PROGNOSIS

The prognosis depends very much on the patient's neurologic status at the time of diagnosis.⁷ Indicators of poor prognosis include:

Impaired ambulation is the most reliable indicator. If ambulatory at the initiation of therapy, 80% of patients remain able to walk after treatment. Only 30% to 40% of patients with motor dysfunction before treatment are able to walk after treatment.

Rapid symptom onset. Animal studies show that neurologic deficits are more likely to reverse when compression is gradual rather than acute.⁴

Duration of motor dysfunction greater than 48 hours indicates that the underlying injury has become irreversible.

Poor sphincter control at presentation indicates that epidural spinal cord compression is in the later stages, when treatment has little or no effect.

■ IMAGING STUDIES

Cancer patients in whom metastatic epidural spinal cord compression is suspected should undergo an immediate, careful, detailed neurologic examination, including imaging studies. The following imaging studies help to confirm the diagnosis.

Plain radiography

Plain radiography detects bony abnormalities (eg, absence of a pedicle, lucencies in the vertebral body) in 70% of patients with epidural spinal cord compression.⁸ However, more

Delays in diagnosis and treatment result in rapid decline

TABLE 1

Current management of metastatic epidural spinal cord compression

Radiotherapy is the treatment of choice for most patients: 30 Gy delivered in 10 fractions over a period of 2.5 weeks

Surgery is appropriate if the patient has:

- Spinal instability
- Unknown diagnosis
- No response to radiotherapy
- Already received the maximum tolerable dose of radiation therapy to the area
- Intractable pain despite radiotherapy and large doses of corticosteroids

than 50% of the bone mass must be lost before any radiographic abnormality can be detected. Plain radiography is less useful in patients with epidural spinal cord compression due to lymphoma or pediatric malignancies. In these patients, a paraspinal soft-tissue mass is usually the cause.

Magnetic resonance imaging

Magnetic resonance imaging (MRI) is the imaging study of choice for diagnosing epidural spinal cord compression. It is noninvasive, easily detects paraspinal soft-tissue masses, detects additional sites of vertebral involvement (multiple sites of compression can be detected in 9% to 30% of patients),⁹ and is as accurate as myelography or computed tomography.¹⁰ The addition of gadolinium contrast offers better detection of epidural, intradural extramedullary, intramedullary, and leptomeningeal lesions.

Computed tomographic myelography

Before the advent of MRI, computed tomography—performed after injecting metrizamide—was the tool of choice for diagnosing metastatic epidural spinal cord compression. This procedure is currently indicated in the following specific clinical situations:

- If MRI is not available
- If the patient has a pacemaker
- If the patient is too large to fit in the MRI machine
- If the patient has severe claustrophobia, is unable to lie flat for the duration of the

test, or has uncontrolled pain.

In a patient with complete myelographic block, contrast can be administered from above through a C1-2 puncture to demarcate the upper border of the block and to look for other epidural lesions.

Adverse effects associated with this procedure include infection, bleeding, and a 10% to 20% risk of iatrogenic neurologic deterioration attributed to the lumbar puncture in patients with complete subarachnoid block.⁷

MANAGEMENT: RELIEVING PAIN AND PRESERVING FUNCTION

Treatment of metastatic epidural spinal cord compression (TABLE 1) should focus on relieving pain and preserving neurologic function. Achieving these two goals will not only preserve the patient's quality of life, but also reduce the burden on the caregiver, since patients who progress to paraplegia require extensive and costly care.

Corticosteroids

Corticosteroid therapy is generally started as soon as the diagnosis of spinal cord compression is entertained. The goals of corticosteroid therapy are to reduce the vasogenic edema caused by the expanding cancer, to control pain, and to maintain neurologic function.

Exact dosages, schedules, and duration of therapy have not been established. A loading dose of dexamethasone 10 to 100 mg intravenously followed by 4 to 24 mg orally or intravenously every 6 hours has been suggested. Animal models point to a dose-dependent response following corticosteroid administration. In these models, the improvement in neurologic function peaked at day 2 of corticosteroid therapy and had diminished by day 4.³

Corticosteroid therapy is usually continued throughout radiation therapy and is tapered slowly toward the end of treatment. During the tapering period, patients should be carefully followed, and any neurologic deterioration should prompt an increase in the steroid dosage.

High-dose dexamethasone. Some experts have hoped that high-dose corticosteroid therapy would be more efficacious than conventional regimens. But three prospective,

Autonomic dysfunction has a poor prognosis

randomized trials^{11–13} of high-dose dexamethasone therapy showed varying results:

- Greenberg et al¹¹ found that high-dose dexamethasone (a 100-mg intravenous bolus, followed by 96 mg/day orally for the first 3 days, then tapered) brought substantial pain relief in patients undergoing radiation therapy, but had no effect on motor ability.
- Sørensen et al¹² found that patients who received high-dose dexamethasone (a 96-mg intravenous bolus, followed by 96 mg orally for 3 days, then tapered) in conjunction with radiation therapy maintained gait function longer than patients who received no dexamethasone with radiation therapy.
- Vecht et al¹³ found no advantage of high-dose dexamethasone therapy vs conventional doses in terms of either pain relief or neurologic function.

High-dose regimens carry a risk of serious toxicity; the incidence of serious toxic effects was 14% in one study.¹⁴ This risk must be weighed against the anticipated benefits.

Radiation therapy

Radiation therapy is the treatment of choice for most patients with epidural spinal cord compression. A common schedule is a dose of 30 Gy delivered in 10 fractions over 2.5 weeks. The treatment field includes the area of spinal cord compression, with a margin of two vertebral bodies above and below the area involved with disease. Patients with prostate or breast cancer often present with multiple areas of involvement.

Response to radiation therapy is evaluated in terms of pain relief and stabilization or reversal of neurologic deficit. Tumors classified as “radiosensitive” (eg, lymphoma, seminoma) respond better than “radioresistant” tumors (eg, sarcoma, melanoma), with a complete response rate of 77% vs 30%.¹⁵ Predictors of more favorable response include favorable histology (prostate or breast cancer, myeloma), earlier diagnosis, and less neurologic deficit at presentation.¹⁶

Surgery

Although radiation therapy is the treatment of choice for most patients with epidural spinal cord compression, surgery is also useful in selected patients. Indications include the

need to establish a diagnosis in patients with no known cancer, to treat spinal instability, to treat pathological fractures caused by symptomatic spinal metastases, and failure to respond to radiation therapy. On the other hand, recovery from spinal surgery is not devoid of complications, and this potential morbidity should be taken into account when surgery is considered for patients with poor life expectancy and several sites of metastatic disease.

Anterior decompression with mechanical stabilization is the surgical technique of choice for epidural metastases arising from the vertebral body. Several retrospective studies¹⁷ and a small prospective study¹⁸ failed to show any advantage of laminectomy when compared with radiotherapy alone.

Chemotherapy

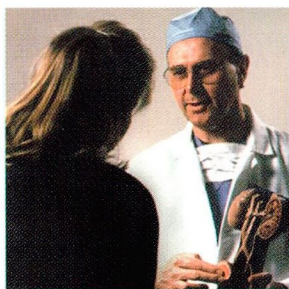
Chemotherapy has only a limited role in the management of epidural spinal cord compression. It may be used in adults who have a chemosensitive tumor (eg, germ cell tumor, Hodgkin disease) and who cannot undergo surgery or radiation therapy, or as adjuvant therapy after surgery or radiotherapy.

In children with chemosensitive tumors (eg, neuroblastoma, Ewing tumor), chemotherapy should be considered because of the risk of radiation-induced growth abnormalities or secondary tumors. Chemotherapy should also be considered in cases of recurrent spinal cord compression by a chemosensitive tumor in a site of previous radiation or surgery.

REFERENCES

1. Perrin RG, Janjan NA, Langford LA. In: Levin VA, editor. *Cancer in the nervous system*. New York: Churchill Livingstone, 1997; 259–280.
2. Arguello F, Baggs RB, Duerst RE, Johnstone L, McQueen K, Frantz CN. Pathogenesis of vertebral metastases and epidural spinal cord compression. *Cancer* 1990; 65: 98–106.
3. Ushio Y, Posner R, Posner JB, Shapiro WR. Experimental spinal cord compression by epidural neoplasm. *Neurology* 1977; 27:422–429.
4. Tarlov IM, Klinger H, Vitale S. Time limits for recovery after acute compression in dogs. *Arch Neurol Psychiatry* 1954; 71:271–290.
5. Siegal T. Participation of serotonergic mechanisms in the pathophysiology of experimental neoplastic spinal cord compression. *Neurology* 1991; 41:574–580.
6. Faul CM, Flickinger JC. The use of radiation in the management of spinal metastases. *J Neurooncol* 1995; 23:149–161.

Trials of high-dose corticosteroids showed varying results





LET US HEAR FROM YOU

- Let us hear your opinions about the *Cleveland Clinic Journal of Medicine*.
- Do you like current articles and sections?
- What topics would you like to see covered and how can we make the Journal more useful to you?

PHONE 216.444.2661
FAX 216.444.9385
E-MAIL ccjm@ccf.org
WWW <http://www.ccjm.org>

CLEVELAND CLINIC JOURNAL OF MEDICINE
The Cleveland Clinic Foundation
9500 Euclid Avenue, NA32
Cleveland, Ohio 44195



DEDICATED TO LIFELONG LEARNING
**CLEVELAND
CLINIC
JOURNAL OF
MEDICINE**



7. Byrne TN. Spinal cord compression from epidural metastases. *N Engl J Med* 1992; 327:614-619.
8. Rodichok LD, Harper GR, Ruckdeschel JC, et al. Early diagnosis of spinal epidural metastasis. *Am J Med* 1981; 70:1181-1188.
9. Boogerd W, Van der Sande JJ. Diagnosis and treatment of spinal cord compression in malignant disease. *Cancer Treat Rep* 1993; 19:129-150.
10. Carmody RF, Yang PJ, Seeley GW, Seeger JF, Unger EC, Johnson JE. Spinal cord compression due to metastatic disease: diagnosis with MR imaging versus myelography. *Radiology* 1989; 173:225-229.
11. Greenberg HS, Kim JH, Posner JB. Epidural spinal cord compression from metastatic tumor: results with a new treatment protocol. *Ann Neurol* 1980; 8:361-366.
12. Sørensen PS, Helweg-Larsen S, Mouridsen H, Hansen HH. Effect of high-dose dexamethasone in carcinomatous metastatic spinal cord compression treated with radiotherapy: a randomized trial. *Eur J Cancer* 1994; 30A:22-27.
13. Vecht CJ, Haaxma-Reiche H, van Putten WLJ, et al. Initial bolus of conventional versus high-dose dexamethasone in metastatic spinal cord compression. *Neurology* 1989; 39:1255-1257.
14. Heimdal K, Hirschberg H, Slettebo H, Watne K, Nome O. High incidence of serious side effects of high-dose dexamethasone treatment in patients epidural spinal cord compression. *J Neurooncol* 1992; 12:141-144.
15. Leviov M, Dale J, Stein M, et al. The management of metastatic spinal cord compression: a radiotherapeutic success ceiling. *Int J Radiat Oncol Biol Phys* 1993; 27:231-234.
16. Maranzano E, Latini P. Effectiveness of radiation therapy without surgery in metastatic spinal cord compression: a prospective analysis of 105 consecutive patients. *Cancer* 1991; 67:1311-1318.
17. Stark RJ, Henson RA, Evans SJ. Spinal metastases: a retrospective survey from a general hospital. *Brain* 1982; 105:189-213.
18. Young RF, Post EM, King GA. Treatment of spinal epidural metastases: randomized prospective comparison of laminectomy and radiotherapy. *J Neurosurg* 1980; 53:741-748.

ADDRESS: Hamed A. Daw, MD, Department of Hematology and Oncology, T40, The Cleveland Clinic Foundation, 9500 Euclid Avenue, Cleveland, OH 44195; e-mail dawh@ccf.org.

Visit the Cleveland Clinic
Center for Continuing Education
web site

www.clevelandclinicmeded.com

- A complete calendar of Cleveland Clinic CME courses
- CME course brochures
- AMA/PRA Category 1 CME credit online